

Push enteroscopy in management of suspected small bowel diseases: Is it still needed?

Mohamed A. Tawfik, Abd Allah El-Sawy

Department of Internal Medicine, Gastroenterology and Hepatology Unit, Tanta University, Tanta, Egypt

Abstract

Background and Study Aims: Small intestinal lesions still represent a challenge in diagnosis and treatment. The detection of small bowel lesions has been difficult due to limited visualization of the small bowel by esophagogastroduodenoscopy (EGD) and colonoscopy. In this study, we aimed to assess the efficacy of push enteroscopy (PE) in diagnosis and therapy of small bowel lesions in different indications in a single gastrointestinal (GI) endoscopy center. **Patients and Methods:** In the period from January 2012 to December 2013, 14 patients presented with different indications referred to the Tanta Endoscopy Center, a division of the internal medicine department and one of the most important centers in Delta Nile in Egypt. Patients were referred due to different indications, and they underwent examination by PE. **Results:** The overall diagnostic yield for patients with suspected small bowel disease was 57% and for patients with both occult and overt obscure bleeding 63%. Ectopic jejunal varices was the most common diagnosis in patients with GI blood loss. Patients with active overt GI bleeding had a higher diagnostic yield. The procedure was tolerated well, and no complications occurred. **Conclusions:** Additional endoscopic evaluation of the proximal small bowel by PE should be considered in all patients with nonspecific findings on EGD and colonoscopy especially with occult or overt bleeding, balloon-assisted enteroscopy may be not readily available and capsule endoscopy is expensive.

Key words

Angiodysplasia, gastrointestinal hemorrhage, push enteroscopy, small bowel disease

Introduction

The field of endoscopy has revolutionized the diagnosis and treatment of gastrointestinal (GI) diseases in recent years. However, imaging of the small bowel is still limited. Small bowel barium follow-through is the most commonly used investigation tool but has a low sensitivity and a specificity of only 10% for detecting pathology.^[1]

Thus, the quest for inspection and biopsy of a small intestine has been pursued enthusiastically for many

years.^[2] The detection of small bowel lesions has been difficult due to limited visualization of the small bowel by esophagogastroduodenoscopy (EGD) and colonoscopy.^[3]

Small bowel is the most difficult part of the GI tract to image due to its location, length, and tortuosity.^[4] Push enteroscopy (PE), which is endoscopy of the small bowel, has been for investigation of small bowel diseases in which PE is actively advanced under vision into the small bowel. The advantages of this method are that the biopsy and endoscopic treatment of mucosal lesions can be performed.^[2]

The most important clinical indication for visualization of the small intestine is obscure GI bleeding or iron-deficiency anemia (IDA), when the source of blood loss cannot be found in the EGD or colonoscopy. It is now recognized that small intestinal lesions account for a significant proportion of patients with obscure GI bleeding and IDA.^[5] In 20% of patients with IDA, a routine upper and lower GI endoscopy may not ascertain GI cause during hospital admission.^[6]

Access this article online

Website: www.jdeonline.in	Quick Response Code 
DOI: 10.4103/0976-5042.147498	

Address for correspondence:

Dr. Mohamed A. Tawfik, Department of Internal Medicine, Gastroenterology and Hepatology Unit, Tanta University, Tanta, Egypt. E-mail: m_atawfik@hotmail.com

Many studies have concluded that on evaluation of GI tract for IDA; most of the lesions were in lower GI tract and have recommended that evaluation for IDA should be started with lower GI examination.^[7-9]

Small – bowel bleedings with an origin located between the papilla and the ileocecal valve are defined as mid GI bleeding. The diagnostic yield of PE was reported to be in the range of 20–80%.^[10]

Push enteroscopy can be considered as the first diagnostic step in patients with suspected small bowel stenosis because capsule endoscopy (CE) should be avoided in these cases due to the risk of capsule retention.^[11]

The present study examines the usefulness of PE in different indications as a diagnostic and/or therapeutic tool when small bowel disease is suspected.

Patients

Fourteen patients underwent PE procedures over 24 months for diagnosis and treatment of suspected small bowel lesions; they were referred due to different indications. The procedures were carried out from January 2012 to December 2013. Clinical indications of PE were: IDA and/or occult GI bleeding (7 patients); overt GI bleeding (4) patients, and one patient for each abnormal small bowel radiology, persistent vomiting and chronic diarrhea.

Inclusion criteria

All patients were examined by both EGD and colonoscopy and revealed negative findings.

Exclusion criteria

There are no absolute contraindications to PE. Suspected or already known stenoses are, in fact, a very good indication for the push-and-pull enteroscopy, which is useful for their further diagnostic assessment. Postprocedural observation of the patients is also important for the timely detection of potential complications, particularly after endoscopic therapeutic interventions.^[12]

Confidentiality of data was guaranteed. Verbal witnessed consents were taken from patients for data collection. The research includes data collection only without any interference with the patient treatment.

Methods

The Pentax VSB-3440 was used for all examinations. This instrument is a video push-type enteroscope, with a total length of 2528 cm and a working length of 2200 cm. The distal diameter is 11.5 mm and the instrument channel is 3.5 mm. Following intubation of the pylorus and passage of the instrument to the distal duodenum, the enteroscope

was advanced through the duodeno-jejunal flexure and the instrument progressing by rotation of the shaft, with shortening and straightening of the scope to facilitate advancement. Small intestinal intubation length was calculated by straightening the instrument to remove the gastric loop, and subtracting 60 cm from the depth inserted: 60 cm being the average distance from incisors to pylorus (range 40–80 cm). All enteroscopic examinations were performed by author of this study.

Results

This study included 14 patients 6 males (43%) and 8 females (57%), their ages ranged from 17 to 67 years with a mean age 48.6 years.

Table 1 and Figure 1 show that IDA was the main indication of PE examination which represented 7/14 (50%), while four cases presented with recurrent episodes of melena (28.6%), and finally one case for each of abnormal computed tomography (CT) findings (dilated loops with air fluid levels), persistent vomiting and chronic diarrhea.

On the other hand, PE examination of these cases achieved diagnosis in 8/14 patients (57%) [Figure 2] with a distribution pattern as the following: Varices 3/8 (37%), arteriovenous malformations (AVMs) 2/8 (25%), ischemia 1/8 (12.5%), infestations 1 (12.5%), nonspecific inflammation 1 (12.5%) [Figure 3].

Diagnosis was achieved only in 3 out of 7 patients presented with IDA while all the studied cases presented with overt bleeding were diagnosed; on the other hand, only one patient

Table 1: Indications, findings, and outcome of PE for all studied patients

Age/sex	Indication	Enteroscopic findings	Therapy	Outcome
37/male	Melena	Jejunal varices	Surgery	Died
35/female	IDA	Jejunal AVMs	Medical	Hb stable
63/female	IDA	Duodenal, jejunal infestation	Medical	Hb stable
67/female	Melena	Jejunal ischemic necrosis	Surgery	Died
17/male	IDA	Jejunal varices	Surgery	Missed
59/female	I.O.*CT scan	Negative	Surgery	Hb stable
55/male	IDA	Negative	Medical	Recurrence
43/female	IDA	Negative	Medical	Recurrence
66/female	Persistent vomiting	Jejunal inflammation	Medical	Improved
33/male	Chronic diarrhea	Negative	Medical	Recurrence
52/male	IDA	Negative	Medical	Recurrence
49/female	IDA	Negative	Medical	Recurrence
57/female	Melena	Jejunal AVMs	APC	Hb stable
47/male	Melena	4 th part duodenal varices	Injected	Hb stable

PE=Push enteroscopy, IDA=Iron-deficiency anemia, AVM=Arteriovenous malformations, APC=Argon plasma coagulation, CT=Computerized tomography

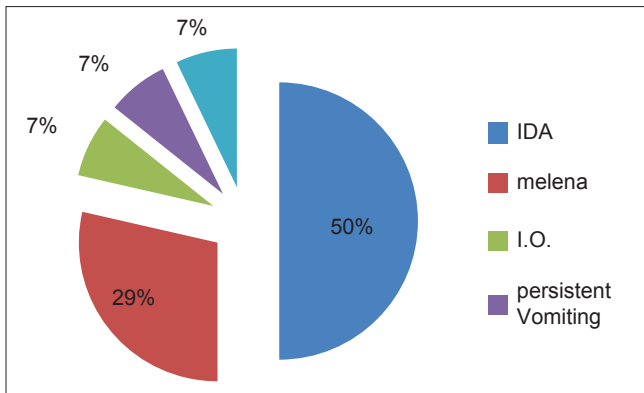


Figure 1: Indications of push enteroscope

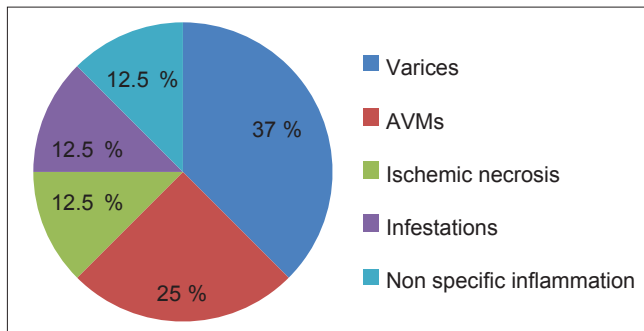


Figure 3: Distribution of the push enteroscopy detected lesions among positive cases

was diagnosed from the three who presented with the other indications [Figure 4]. The mean Hb among the studied patients were 9.05 gm/dl, however the mean prothrombin activity were 87.8% Table 2

Regarding PE therapy, two patients (14.3%) in this study were treated by PE, the first one had jejunal varices injected using cyanoacrylate and the other had AVMs treated by argon plasma coagulation, while medical treatment succeed to control the main indication in four cases (28.5%). Recurrence of the symptoms was happened in five cases (35.7%) that were normal PE examination. Finally, two cases were died after referred to surgery.

Discussion

Although PE couldn't be considered a new tool in the investigation of the small intestine as it was established during the 1980s but due to excessive loop formation, it allows only limited visualization of the small intestine;^[11] however, we established the diagnosis in 8 out of the 14 studied patients with suspected small bowel lesion [Figures 5-9], achieving diagnostic yield 57%, this result is very close to Pennazio *et al.* 60%^[13] on the other hand it is higher than Barkin *et al.* 39%^[14] and Chen *et al.* 33%.^[15]

Regarding the most important indication for the PE examination among the studied patients, occult bleeding and/or IDA was the first by 7/14 cases followed by overt bleeding namely melena

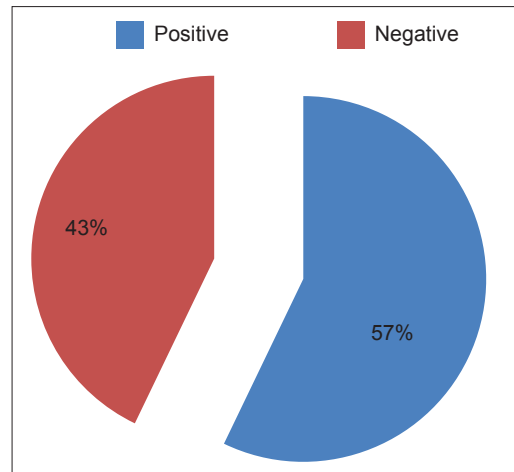


Figure 2: Push enteroscopy diagnostic ability in all patients

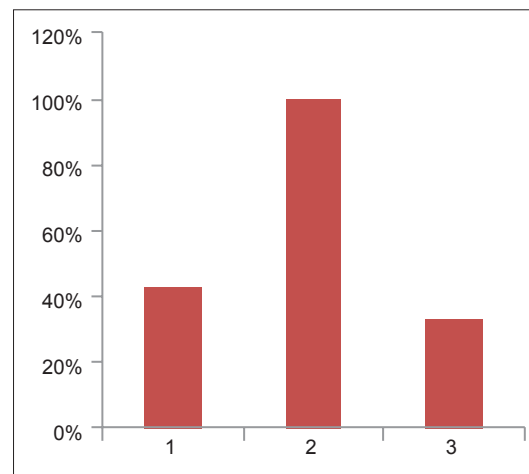


Figure 4: Comparison between achieved diagnosis in (1) occult, (2) overt bleeding and (3) other indications

by 4/14 cases. Interestingly, both occult and overt bleeding were the most important indication for referring cases to be examined by PE 11/14 (78.6%) and PE achieved diagnosis in 7/11 occult and overt patients with a percent (63.6%), this was compatible with Chak *et al.* (70%)^[16] Chong *et al.* (64%)^[17] and Schmit *et al.* (57%)^[18] and in contrast to Chen *et al.* 47%^[15] and Landi *et al.* 27%.^[19] The presence of active GI bleeding increased the diagnostic yield of the present study (4 of 4 patients). This is consistent with the published series.^[14,20] It stresses the importance of performing the procedure when patients have had evidence of active bleeding.

Since the introduction of wireless CE into clinical practice, the ability to diagnose small bowel diseases has improved greatly.^[21] However, CE is limited by the fact that biopsies cannot be taken, and interventional endoscopic procedures cannot be performed.^[22,23] Moreover, their economic costs still a burden in our country for a diagnostic tool alone.

Previous studies have revealed an overall CE "miss rate" of 10% and a miss rate of 18.6% for mass lesions especially if the lesion

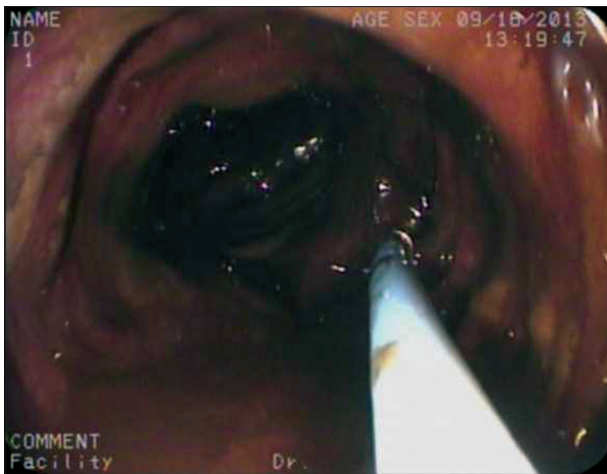

Figure 5: Ischemic necrosis of the proximal jejunum

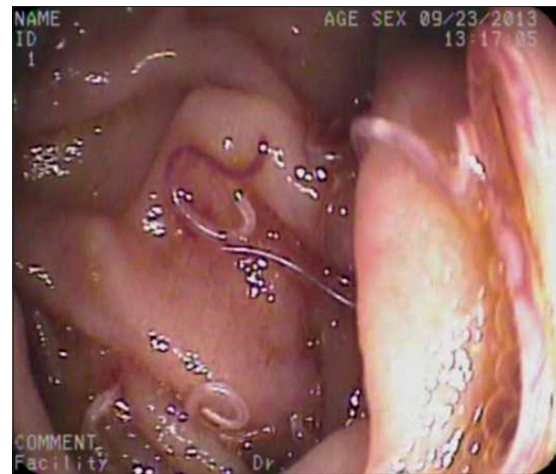


Figure 6: Heavy infestation in the proximal jejunum

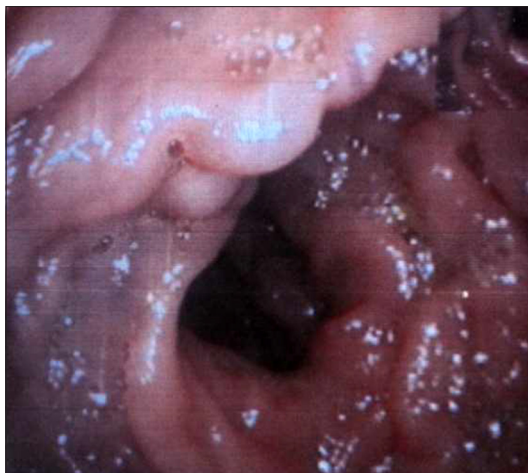

Figure 7: Jejunal varices

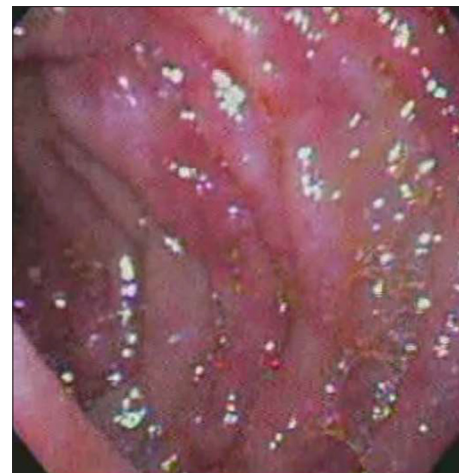

Figure 8: Nonspecific jejunitis

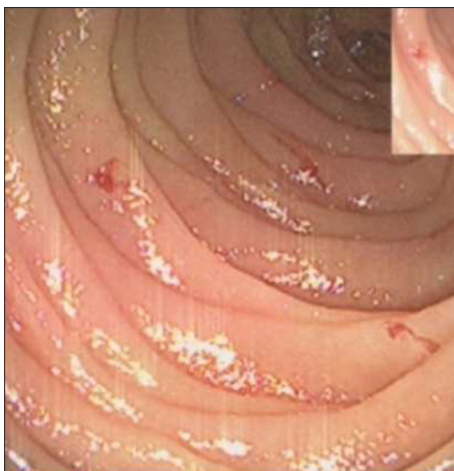


Figure 9: Multiple bleeding arteriovenous malformations in proximal jejunum

is smaller than 3 cm.^[24-26] There are several possible reasons why mass lesions are missed by CE. First, unlike vascular lesions, a small bowel mass lesions are typically unifocal. At the current image capture rate of two frames per second, focal lesions are

more likely to be missed than those that are diffuse.^[24] Second, as the capsule passes along the duodenal sweep, it may increase in speed. Therefore, mass lesions located in the proximal small bowel are more likely to be missed by CE. Lastly, incomplete small-bowel transit and blood in the lumen may obscure visualization of underlying mass lesions.^[24,27]

Double balloon enteroscopy (DBE) is a novel technique, which was described in 2003.^[21] DBE has resulted in the improved diagnosis of small bowel lesions by allowing deep access into the small bowel with diagnostic and therapeutic capacity.^[23] However, DBE is actually more time-consuming than other endoscopic procedures, which typically takes about 2 h. A longer duration often means patient intolerance and increase the risk of complications including but not limited to bowel perforation and pancreatitis.^[21] Moreover, DBE requires special endoscopic training and is not readily available in many institutions.

Push enteroscopy permits visualization and therapeutic intervention in the proximal small bowel, approximately 80–120 cm beyond the ligament of Treitz.^[28,29] PE is safe, relatively quick and a readily available modality. However, PE

Table 2: Ultrasound and laboratory tests for all studied patients underwent PE

Ultrasound	Hb (g/dl)	Platelets	Prothrombin activity %
LC, splenomegaly	9.5	100.000	74
Normal	8.2	220.000	91
PPF	7	170.000	100
Normal	10	270.000	84
Normal	7.8	190.000	87
Ileus, I.O.*CT	11	330.000	90
Normal	8.5	290.000	100
Normal	6.9	310.000	95
LC	10.9	160.000	88
Normal	12	240.000	90
Splenomegaly	10	130.000	77
Normal	10.7	350.000	83
PPF	6.5	190.000	100
LC, splenomegaly	7.7	60.000	70

PE=Push enteroscopy, CT=Computerized tomography, PPF=Periportal fibrosis, LC=Liver cirrhosis

is not a risk-free procedure. PE cannot reach the distal small intestine, and PE has a similar profile of complications as a conventional upper endoscopy.^[30,31]

Capsule endoscopy, PE, DBE, CT scan, and magnetic resonance enterography have facilitated with the diagnosis, monitoring, and management of patients with small bowel lesions.^[32]

The outcome of those patients after 3 months of follow-up was recorded. Six patients were improved clinically; however, recurrence occurred in five cases that were normal in PE examination and badly two patients died after referred to surgery.

Although this study was carried out on the referred cases over 24 months to GI endoscopy center of Tanta University Hospital, the number of those patient was relatively small (14) patients, which reflect the lack of expectancy to small intestinal lesions, however this expectancy is growing every day.

We conclude that PE has an important and useful role in this study, and it is a suitable tool to begin with it in investigations of patients whom a small bowel lesion is suspected especially in the presence of obscure overt bleeding, however, obscure occult bleeding was the most important indication among the studied patients. It is cheap, available, partially time saver and tolerable with a diagnostic yield of 57% in this study. Other endoscopic and nonendoscopic modalities will be useful in patients with PE negative findings especially if they are unavailable and/or high relatively expensive.

References

- Rosenbusch G, Jansen JB, Reeders JW. Contemporary radiological examination of the small bowel. *Baillieres Clin Gastroenterol* 1994;8:683-700.
- Chen RY, Taylor AC, Desmond PV. Push enteroscopy: A single centre experience and review of published series. *ANZ J Surg* 2002;72:215-8.
- Pata C, Akyüz Ü, Erzın Y, Mercan A. Double-balloon enteroscopy: The diagnosis and management of small bowel diseases. *Turk J Gastroenterol* 2012;21:353-9.
- Chan VO, Dermot E, Malone DE. *Small Bowel Vascular Disorders. Abdominal Imaging*. Berlin, Heidelberg: Springer Verlag; 2013.
- O'Mahony S, Morris AJ, Straiton M, Murray L, MacKenzie JF. Push enteroscopy in the investigation of small-intestinal disease. *QJM* 1996;89:685-90.
- Zuckerman GR, Prakash C, Askin MP, Lewis BS. American Gastroenterological Association medical position statement: Evaluation and management of occult and obscure gastrointestinal bleeding. *Gastroenterology* 2000;118:197-201.
- Park DI, Ryu SH, Oh SJ, Yoo TW, Kim HJ, Cho YK, *et al*. Significance of endoscopy in asymptomatic premenopausal women with iron deficiency anemia. *Dig Dis Sci* 2006;51:2372-6.
- Park DI, Ryu SH, Oh SJ, Yoo TW, Kim HJ, Cho YK, *et al*. Significance of endoscopy in asymptomatic premenopausal women with iron deficiency anemia. *Dig Dis Sci* 2006;51:2372-6.
- Rai S, Hemingway D. Iron deficiency anaemia – Useful diagnostic tool for right sided colon cancers? *Colorectal Dis* 2005;7:588-90.
- Pohl J, Delvaux M, Ell C, Gay G, May A, Mulder CJ, *et al*. European Society of Gastrointestinal Endoscopy (ESGE) Guidelines: Flexible endoscopy for diagnosis and treatment of small-bowel diseases. *Endoscopy* 2008;40:609-18.
- Sunada K, Yamamoto H, Kita H, Yano T, Sato H, Hayashi Y, *et al*. Clinical outcomes of enteroscopy using the double-balloon method for strictures of the small intestine. *World J Gastroenterol* 2005;11:1087-9.
- Ell C, May A, Nachbar L, C Ell. A May, L Nachbar, N Plum Small bowel endoscopy: Innovations in diagnosis and treatment. *Dtsch Arztebl* 2006;103:A3033-9.
- Pennazio M, Arrigoni A, Risio M, Spandre M, Rossini FP. Clinical evaluation of push-type enteroscopy. *Endoscopy* 1995;27:164-70.
- Barkin JS, Ross BS. Medical therapy for chronic gastrointestinal bleeding of obscure origin. *Am J Gastroenterol* 1998;93:1250-4.
- Chen RY, Taylor AC, Desmond PV. Push enteroscopy: A single centre experience and review of published series. *ANZ J Surg* 2002;72:215-8.
- Chak A, Koehler MK, Sundaram SN, Cooper GS, Canto MI, Sivak MV Jr. Diagnostic and therapeutic impact of push enteroscopy: Analysis of factors associated with positive findings. *Gastrointest Endosc* 1998;47:18-22.
- Chong J, Tagle M, Barkin JS, Reiner DK. Small bowel push-type fiberoptic endoscopy for patients with occult gastrointestinal bleeding or suspected small bowel pathology. *Am J Gastroenterol* 1994;89:2143-6.
- Schmit A, Gay F, Adler M, Cremer M, Van Gossum A. Diagnostic efficacy of push-enteroscopy and long-term follow-up of patients with small bowel angiodysplasias. *Dig Dis Sci* 1996;41:2348-52.
- Landi B, Tkoub M, Gaudric M, Guimbaud R, Cervoni JP, Chaussade S, *et al*. Diagnostic yield of push-type enteroscopy in relation to indication. *Gut* 1998;42:421-5.
- Cellier C, Tkoub M, Gaudric M, Guimbaud R, Auroux J, Chaussade S, *et al*. Comparison of push-type endoscopy and barium transit study of the small intestine in digestive bleeding and unexplained iron-deficiency anemia. *Gastroenterol Clin Biol* 1998;22:491-4.
- Kaffes AJ, Koo JH, Meredith C. Double-balloon enteroscopy in the diagnosis and the management of small-bowel diseases: An initial experience in 40 patients. *Gastrointest Endosc* 2006;63:81-6.
- Pata C, Akyüz Ü, Erzın Y, Mercan A. Double-balloon enteroscopy: The diagnosis and management of small bowel diseases. *Turk J Gastroenterol* 2012;21:353-9.
- Ross A, Mehdizadeh S, Tokar J, Leighton JA, Kamal A, Chen A, *et al*. Double balloon enteroscopy detects small bowel mass lesions missed by capsule endoscopy. *Dig Dis Sci* 2008;53:2140-3.
- Pata C, Akyüz Ü, Erzın Y, Mercan A. Double-balloon enteroscopy: The diagnosis and management of small bowel diseases. *Turk J Gastroenterol* 2012;21:353-9.

25. Lewis BS, Eisen GM, Friedman S. A pooled analysis to evaluate results of capsule endoscopy trials. *Endoscopy* 2005;37:960-5.
26. Postgate A, Despott E, Burling D, Gupta A, Phillips R, O'Beirne J, *et al*. Significant small-bowel lesions detected by alternative diagnostic modalities after negative capsule endoscopy. *Gastrointest Endosc* 2008;68:1209-14.
27. Postgate A, Despott E, Burling D, Gupta A, Phillips R, O'Beirne J, *et al*. Significant small-bowel lesions detected by alternative diagnostic modalities after negative capsule endoscopy. *Gastrointest Endosc* 2008;68:1209-14.
28. Semrad CE. Small bowel enteroscopy: Territory conquered, future horizons. *Curr Opin Gastroenterol* 2009;25:110-5.
29. Kaffes AJ, Koo JH, Meredith C. Double-balloon enteroscopy in the diagnosis and the management of small-bowel diseases: An initial experience in 40 patients. *Gastrointest Endosc* 2006;63:81-6.
30. Semrad CE. Small bowel enteroscopy: Territory conquered, future horizons. *Curr Opin Gastroenterol* 2009;25:110-5.
31. Mylonaki M, Fritscher-Ravens A, Swain P. Wireless capsule endoscopy: A comparison with push enteroscopy in patients with gastroscopy and colonoscopy negative gastrointestinal bleeding. *Gut* 2003;52:1122-6.
32. Tennyson CA, Semrad CE. Advances in small bowel imaging. *Curr Gastroenterol Rep* 2011;13:408-17.

How to cite this article: Tawfik MA, El-Sawy AA. Push enteroscopy in management of suspected small bowel diseases: Is it still needed?. *J Dig Endosc* 2014;5:95-100.

Source of Support: Nil, **Conflict of Interest:** None declared.