

EUS-guided celiac plexus neurolysis/block

Narendra S. Choudhary, Rajesh Puri

Institute of Digestive and Hepatobiliary Sciences Medanta, The Medicity, Gurgaon, Haryana, India

Abstract

Refractory chronic abdominal pain as a result of inoperable pancreatic cancer or chronic pancreatitis poses a formidable challenge and can be effectively relieved with celiac axis block or celiac plexus neurolysis (CPN). Percutaneous celiac plexus block (CPB) or computed tomography (CT)-guidance using anterior or posterior approaches has some limitations. However, endoultrasound (EUS)-guided CPB has evolved itself as an effective and safe procedure for management of refractory abdominal pain. The EUS offers advantages, which include accurate anatomic imaging, real-time monitoring of injection, and anterior approach, which avoids neurologic complications. The CPN can be combined with staging and fine-needle aspiration cytology (FNAC) of a malignancy in the same session. The present review discusses anatomic details of celiac axis block, procedure-related details, complications, contraindications, comparison to other modalities, and results of various studies and author's experience of EUS guided CPB/neurolysis.

Key words

Celiac plexus, computed tomography, endoscopic ultrasound, neurolysis

Introduction

In 1914, Max Kappis used splanchnic nerve blocks for surgical anesthesia.^[1] Initially, celiac plexus block (CPB) was performed using posterior approach that was associated with risk of neurological complications, and hence, was replaced by anterior approach. Currently, celiac axis block or neurolysis is used for management of refractory pain secondary to inoperable pancreatic cancer or chronic pancreatitis.^[2-5] The celiac plexus innervates the liver, gallbladder, biliary tract, pancreas, spleen, adrenal glands, kidneys, mesentery, and the small and large bowel proximal to the transverse colon.^[2] CPB refers to temporary inhibition of the celiac plexus with the help of bupivacaine and corticosteroid injections in patients with benign pancreatic diseases such as chronic pancreatitis. Celiac plexus neurolysis (CPN) refers to the ablation of the plexus (chemical splanchnicectomy which ablates the afferent

nerve fibers that transmit pain from intra-abdominal viscera), and is often achieved with alcohol or phenol administered with a local anesthetic.^[6] CPN using alcohol is not routinely used in benign diseases as there is risk of retroperitoneal fibrosis, which would render any subsequent pancreatic surgery more difficult. Anterior approach under computed tomography (CT)- or ultrasound-guidance has been used to avoid neurological complications.^[7,8] Endoultrasound (EUS)-guided celiac axis block/neurolysis has several advantages over other modalities. EUS uses anterior approach, thus, it avoids neurological complications and relative proximity of the celiac ganglia to the posterior gastric wall ensures an accurate passage of the needle into the ganglia, thereby minimizing the risk of complications and increasing effectiveness of block.^[5,6] Comparison of various celiac axis approaches is shown in Table 1.

Anatomy of Celiac Plexus

Celiac 'plexus' (ganglia and interconnecting fibers) is the largest plexus of sympathetic nervous system located in upper abdomen; it comprises of preganglionic sympathetic efferent nerve fibers derived from the greater splanchnic (T5-T9), lesser splanchnic (T10-T11), and least splanchnic (T12) nerves; preganglionic parasympathetic efferent fibers (from posterior trunk of the vagus nerve) and the visceral afferent fibers (for nociceptive stimuli) from the upper abdominal viscera. The

Access this article online

Website:

www.jdeonline.in

DOI:

10.4103/0976-5042.132394

Quick Response Code



Address for correspondence:

Dr. Rajesh Puri, Associate Director, Therapeutic Endoscopist and Endosonologist, Institute of Digestive and Hepatobiliary Sciences, Medanta, The Medicity, Gurgaon - 122 001, Haryana, India. E-mail: purirajesh69@gmail.com

celiac plexus innervates the liver, gallbladder, biliary tract, pancreas, spleen, adrenal glands, kidneys, mesentery, and the small and large bowel proximal to the transverse colon. The celiac plexus lies within retroperitoneal space posterior to the stomach and pancreas embedded in loose areolar tissue, close to the celiac axis anterolateral to aorta at the level of first lumbar vertebra, just inferior to origin of celiac artery as shown in Figure 1 and is separated from vertebral column by crus of diaphragm.^[2,4,9-12] There is considerable variability in size (0.5-4.5 cm), number (1-5), and position (T12-L1 disc space to middle of L2 - vertebral body). Zhang *et al.*, reported that 94% of the celiac ganglia are located at the level of T12 or L1.^[10]

EUS-Guided CPB/CPN-Procedure

The procedure is done under deep sedation. Patients on antiplatelet/anticoagulant drugs need to stop them to allow normalization of hemostasis. The patient is given intravenous fluids to prevent risk of hypotension that may arise from splanchnic blood pooling due to unopposed parasympathetic action after CPB/neurolysis. The procedure is performed with a curvilinear array EUS scope. The EUS under endoscopic view is passed into the proximal stomach, just distal to the gastroesophageal junction and along the posterior wall of the stomach, the aorta and the celiac axis (first vessel arising from the aorta below the diaphragm) are identified.^[13,14] The celiac plexus is identified as a hypoechoic, oblong, or lobulated structures, often with irregular edges, containing hyperechoic foci or strands, anterolateral to the origin of the celiac artery.^[15-17] After identification of base of celiac trunk, a EUS fine-needle aspiration (FNA) needle is passed through the biopsy channel and secured to the Luer-Lock assembly. This needle is advanced under real-time EUS imaging through the posterior wall of the stomach adjacent and anterior to the lateral aspect of the aorta at the level of celiac trunk origin. An aspiration test is done to rule out vessel puncture before injection. For neurolysis, 5-10 mL

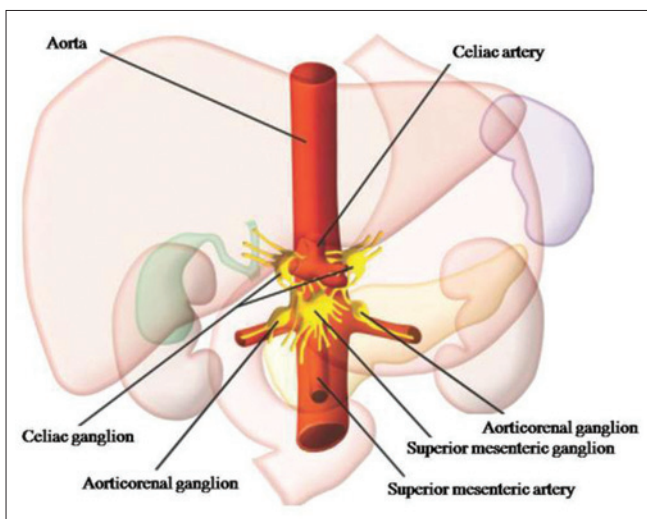


Figure 1: Morphologic and functional anatomy of the celiac plexus (adapted from reference 2)

of a local analgesic bupivacaine (0.25%) is injected followed by 10-20 mL of a neurolytic agent (98% dehydrated ethanol), which will produce an echogenic cloud; for plexus blocks, 20 mL of 0.25% bupivacaine is injected followed by 80 mg of triamcinolone. Alternatively, half amount may be injected to each side of celiac trunk. Our center uses EUS-FNA cytology (FNAC) needle having multiple side holes for CPN/CPB (Echotip; Cook Endoscopy, WinstonCook™); these multiple side holes ensure uniform distribution of neurolytic agents; however, there are no studies comparing one needle with another.

Contraindications of procedure^[4,18] are summarized in Table 2. Relative contraindications include altered anatomy interfering in obtaining adequate access or a history of multiple prior CPBs in patients with chronic pancreatitis. There are no guidelines regarding hemostasis for undertaking CPB/CPN, but at our center we follow same recommendations as outlined for EUS-guided FNAC. These include stopping all antiplatelet and anticoagulants except aspirin 7 days prior to the procedure

Table 1: Comparison of various techniques for celiac plexus block/neurolysis (adapted from reference 2)

Technique	Advantages	Disadvantages
Fluoroscopy	Easily available	Anatomic details are not seen Radiations are involved
Ultrasonography	Easily available Vascular structures are identifiable Diffusion of neurolytic agent may be seen without contrast medium	Not good for retro-peritoneum Operator dependent
CT	Retroperitoneal structures are identifiable May show celiac plexus Shows exact location of the needle tip and surrounding structures Shows diffusion of neurolytic agents	Radiations are involved
EUS	Shows proximity to celiac plexus Anatomic details well imaged Real-time monitoring of neurolytic injection Anterior approach avoids neurologic complications Allows staging, FNAC and/or biopsy	Operator dependent Invasive Snowstorm effect may hinder visualization of the celiac plexus

CT=Computerized tomography, EUS=Endoultrasound, FNAC=Fine-needle aspiration cytology

Table 2: Contraindications of celiac plexus block or neurolysis

Patients with coagulopathy
Local/intra-abdominal infection and sepsis
Bowel obstruction
Patients on disulfiram therapy for alcohol abuse
Patients with physical dependence and drug seeking behavior
Thrombocytopenia (platelets <50,000)
An uncooperative patient

and to ensure a platelet count of >50,000 and international normalized ratio (INR) <1.5.^[19]

Results of EUS-Guided CPB/CPN and Comparison to Other Modalities

Table 3 summarizes the results of various studies using EUS-guided CPN/CPB and their comparison to CT- and fluoroscopic-guided CPN/CPB.^[20-30] In a systemic review of EUS-guided CPN of 17 studies for relief of pain; eight studies involved 283 patients of pancreatic cancer and nine studies with 376 patients of chronic pancreatitis. The review concluded that pain relief occurred in 80.12% (95% confidence interval (CI) = 74.47-85.22) and in 59.45% (95% CI = 54.51-64.30) for pancreatic cancer and chronic pancreatitis, respectively.^[31] In general, EUS guided CPN/CPB is safe and more effective than other modalities of CPB.^[27,29]

A total of 62 patients underwent EUS-guided CPB/CPN at our center; of them 17 patients with chronic pancreatitis underwent CPB and 45 patients with pancreatic cancer and a few with gallbladder cancer underwent CPN for palliation of intractable pain. Eleven patients (17.7%) had no improvement in pain. The narcotic requirement

decreased in the remaining 51 patients (82.3%) and relief lasted for 8-12 weeks in majority of these patients. There were no serious procedure-related complications in any of these patients.

Complications

In the posterior approach era, major complications were neurological such as monoplegia and anal and bladder sphincter dysfunction due to puncture of spinal artery resulting in spinal ischemia. Other complications included backache, pneumothorax, and retroperitoneal abscess.^[2,7] The common complications of EUS-guided celiac axis block/neurolysis are immediate pain, orthostatic hypotension (due to loss of sympathetic tone and splanchnic vasodilatation), and transient diarrhea.^[14,18,32] The potential risk of hypotension can be reduced by administering 500 ml saline before the procedure and 500 ml saline after procedure at a rate of 100 ml per hour. A large series of 189 EUS-CPB and 31 EUS-CPN procedures which were performed in 128 and 30 patients, respectively, reported four complications (asymptomatic hypotension, retroperitoneal abscess, and severe self-limited pain in two patients).^[33] Uncommon complications of celiac plexus include chronic diarrhea,^[34] gastroparesis,^[35] retroperitoneal hemorrhage, peripancreatic abscess formation,^[36] and stomach rupture^[37] (after repeated injections).

Table 3: Results of endoultrasound-guided celiac plexus block (CPB)/celiac plexus neurolysis (CPN)

Author (year)	N, modality	Results	Comments
Wiechowska-Kozłowska ^[20] 2012	29, CPN	86% improved at 1-2 weeks	Improvement of pain in 76% of patients after 2-3 months
LeBlanc <i>et al.</i> , ^[21] 2011	29 in 1 injection and 21 in 2 injections, CPN	74% (69 vs 81%, <i>P</i> =NS)	Median duration of pain relief in the 1-injection and 2-injection groups: 11 and 14 weeks (<i>P</i> =NS)
Ascunce <i>et al.</i> , ^[22] 2011	64, CPN	50% at 1 week	Visualization of celiac ganglia was best predictor of response (odds ratio 15.7; <i>P</i> <0.001) Tumors located outside the head of the pancreas and higher baseline pain level were weakly associated with a good response
Wyse <i>et al.</i> , ^[23] 2011	40 CPN, 48 analgesics	EUS-CPN group had less pain and narcotic requirement	Used CPN at diagnosis of inoperable pancreatic cancer
Iwata <i>et al.</i> , ^[24] 2011	47, CPN	Pain relief 68.1%	Multivariate analysis: Direct invasion of celiac plexus and distribution of ethanol only on the left side of the celiac artery were negative predictors
Gunaratnam <i>et al.</i> , ^[25] 2001	58, CPN	78% patients had decline in pain scores	
Sakamoto <i>et al.</i> , ^[26] 2010	34 CPN vs 33 broad plexus neurolysis (including SMA)	BPN superior for pain control	Better neurolytic spread in BPN group (as seen by CT)
Santosh <i>et al.</i> , ^[27] 2009	27 CPB vs 29 fluoroscopic-guided CPB	70 vs 30% improvement	EUS-CPB more effective than fluoroscopic technique
Gress <i>et al.</i> , ^[28] 2001	90, CPB	55% had improvement in pain score	26% had persistent benefit beyond 12 weeks, 10% had persistent benefit at 24 weeks; less response in <45 years of age or previous pancreatic surgery for chronic pancreatitis
Gress <i>et al.</i> , ^[29] 1999	18 CPB (10 EUS-guided)	50 (EUS group) vs 25% (CT group)	EUS-guided block cost effective compared to CT-guided block
Wiersema and Wiersema, ^[30] 1996	30 CPN (25 carcinoma pancreas)	79-88% of patients had persistent improvement in their pain score	EUS group less cost and more persistent benefit (40% at 8 week and by 30% at 24 week) than CT group Median follow-up 10 weeks

EUS=Endoultrasound, SMA=Superior mesenteric artery, NS=Not significant, BPN=Broad plexus neurolysis, CT=Computed tomography

Conclusions

CPN should be considered in patients with upper abdominal cancer where pain is not adequately controlled with analgesics or significant opioid-induced side effects are present.^[38] CPB is used to provide temporary relief in chronic pancreatitis patients with significant pain to decrease dose of narcotics.^[39] EUS-guided CPN is a safe and useful modality for relief of intractable pain in patients with inoperable pancreatic cancer and chronic pancreatitis.

References

- Fujita Y, Sari A. Max Kappis and the celiac plexus block. *Anesthesiology* 1997;86:508.
- Kambadakone A, Thabet A, Gervais DA, Mueller PR, Arellano RS. CT-guided celiac plexus neurolysis: A review of anatomy, indications, technique, and tips for successful treatment. *Radiographics* 2011;31:1599-621.
- Erdine S. Celiac ganglion block. *Agri* 2005;17:14-22.
- Jain P, Dutta A, Sood J. Coeliac plexus blockade and neurolysis: An overview. *Indian J Anaesth* 2006;50:169-77.
- Michaels AJ, Draganov PV. Endoscopic ultrasonography guided celiac plexus neurolysis and celiac plexus block in the management of pain due to pancreatic cancer and chronic pancreatitis. *World J Gastroenterol* 2007;13:3575-80.
- Varadarajulu S, Wallace MB. Applications of endoscopic ultrasonography in pancreatic cancer. *Cancer Control* 2004;11:15-22.
- Wang PJ, Shang MY, Qian Z, Shao CW, Wang JH, Zhao XH. CT-guided percutaneous neurolytic celiac plexus block technique. *Abdom Imaging* 2006;31:710-8.
- Caratozzolo M, Lirici MM, Consalvo M, Marzano F, Fumarola E, Angelini L. Ultrasound-guided alcoholization of celiac plexus for pain control in oncology. *Surg Endosc* 1997;11:239-44.
- Ward EM, Rorie DK, Nauss LA, Bahn RC. The celiac ganglia in man: Normal anatomic variations. *Anesth Analg* 1979;58:461-5.
- Zhang XM, Zhao QH, Zeng NL, Cai CP, Xie XG, Li CJ, et al. The celiac ganglia: Anatomic study using MRI in cadavers. *AJR Am J Roentgenol* 2006;186:1520-3.
- Mercadante S, Nicosia F. Celiac plexus block: A reappraisal. *Reg Anesth Pain Med* 1998;23:37-48.
- Loukas M, Klaassen Z, Merbs W, Tubbs RS, Gielecki J, Zurada A. A review of the thoracic splanchnic nerves and celiac ganglia. *Clin Anat* 2010;23:512-22.
- Soweid AM, Azar C. Endoscopic ultrasound-guided celiac plexus neurolysis. *World J Gastrointest Endosc* 2010;2:228-31.
- Hoffman BJ. EUS-guided celiac plexus block/neurolysis. *Gastrointest Endosc* 2002;56:S26-8.
- Gerke H, Silva RG Jr, Shamoun D, Johnson CJ, Jensen CS. EUS characteristics of celiac ganglia with cytologic and histologic confirmation. *Gastrointest Endosc* 2006;64:35-9.
- Ha TI, Kim GH, Kang DH, Song GA, Kim S, Lee JW. Detection of celiac ganglia with radial scanning endoscopic ultrasonography. *Korean J Intern Med* 2008;23:5-8.
- Gleeson FC, Levy MJ, Papachristou GI, Pelaez-Luna M, Rajan E, Clain JE, et al. Frequency of visualization of presumed celiac ganglia by endoscopic ultrasound. *Endoscopy* 2007;39:620-4.
- Levy MJ, Wiersema MJ. EUS-guided celiac plexus neurolysis and celiac plexus block. *Gastrointest Endosc* 2003;57:923-30.
- Murad F, Levy MJ, Topazian M. Indications, preparation, risks, and complications. In: Hawes RH, Fockens P, Varadarajulu S, editors. *Endosonography*. 2nd ed. Philadelphia: Elsevier Saunders; 2011. p. 29-37.
- Wiechowska-Kozłowska A, Boer K, Wójcicki M, Milkiewicz P. The efficacy and safety of endoscopic ultrasound-guided celiac plexus neurolysis for treatment of pain in patients with pancreatic cancer. *Gastroenterol Res Pract* 2012;2012:503098.
- LeBlanc JK, Al-Haddad M, McHenry L, Sherman S, Juan M, McGreevy K, et al. A prospective, randomized study of EUS-guided celiac plexus neurolysis for pancreatic cancer: One injection or two? *Gastrointest Endosc* 2011;74:1300-7.
- Ascunce G, Ribeiro A, Reis I, Rocha-Lima C, Sleeman D, Merchan J, et al. EUS visualization and direct celiac ganglia neurolysis predicts better pain relief in patients with pancreatic malignancy (with video). *Gastrointest Endosc* 2011;73:267-74.
- Wyse JM, Carone M, Paquin SC, Usatii M, Sahai AV. Randomized, double-blind, controlled trial of early endoscopic ultrasound-guided celiac plexus neurolysis to prevent pain progression in patients with newly diagnosed, painful, inoperable pancreatic cancer. *J Clin Oncol* 2011;29:3541-6.
- Iwata K, Yasuda I, Enya M, Mukai T, Nakashima M, Doi S, et al. Predictive factors for pain relief after endoscopic ultrasound-guided celiac plexus neurolysis. *Dig Endosc* 2011;23:140-5.
- Gunaratnam NT, Sarma AV, Norton ID, Wiersema MJ. A prospective study of EUS-guided celiac plexus neurolysis for pancreatic cancer pain. *Gastrointest Endosc* 2001;54:316-24.
- Sakamoto H, Kitano M, Kamata K, Komaki T, Imai H, Chikugo T, et al. EUS-guided broad plexus neurolysis over the superior mesenteric artery using a 25-gauge needle. *Am J Gastroenterol* 2010;105:2599-606.
- Santosh D, Lakhtakia S, Gupta R, Reddy DN, Rao GV, Tandan M, et al. Clinical trial: A randomized trial comparing fluoroscopy guided percutaneous technique vs. endoscopic ultrasound guided technique of coeliac plexus block for treatment of pain in chronic pancreatitis. *Aliment Pharmacol Ther* 2009;29:979-84.
- Gress F, Schmitt C, Sherman S, Ciaccia D, Ikenberry S, Lehman G. Endoscopic ultrasound-guided celiac plexus block for managing abdominal pain associated with chronic pancreatitis: A prospective single center experience. *Am J Gastroenterol* 2001;96:409-16.
- Gress F, Schmitt C, Sherman S, Ikenberry S, Lehman G. A prospective randomized comparison of endoscopic ultrasound- and computed tomography-guided celiac plexus block for managing chronic pancreatitis pain. *Am J Gastroenterol* 1999;94:900-5.
- Wiersema MJ, Wiersema LM. Endosonography-guided celiac plexus neurolysis. *Gastrointest Endosc* 1996;44:656-62.
- Puli SR, Reddy JB, Bechtold ML, Antillon MR, Brugge WR. EUS-guided celiac plexus neurolysis for pain due to chronic pancreatitis or pancreatic cancer pain: A meta-analysis and systematic review. *Dig Dis Sci* 2009;54:2330-7.
- Gunaratnam NT, Wong GY, Wiersema MJ. EUS-guided celiac plexus block for the management of pancreatic pain. *Gastrointest Endosc* 2000;52:S28-34.
- O'Toole TM, Schmulewitz N. Complication rates of EUS-guided celiac plexus blockade and neurolysis: Results of a large case series. *Endoscopy* 2009;41:593-7.
- Gafanovich I, Shir Y, Tsvang E, Ben-Chetrit E. Chronic diarrhea-induced by celiac plexus block? *J Clin Gastroenterol* 1998;26:300-2.
- Iftikhar S, Loftus EV Jr. Gastroparesis after celiac plexus block. *Am J Gastroenterol* 1998;93:2223-5.
- Navarro-Martinez J, Montes A, Comps O, Sitges-Serra A. Retroperitoneal abscess after neurolytic celiac plexus block from the anterior approach. *Reg Anesth Pain Med* 2003;28:528-30.
- Loeve US, Mortensen MB. Lethal necrosis and perforation of the stomach and the aorta after multiple EUS-guided celiac plexus neurolysis procedures in a patient with chronic pancreatitis. *Gastrointest Endosc* 2013;77:151-2.
- Nagels W, Pease N, Bekkering G, Cools F, Dobbels P. Celiac plexus neurolysis for abdominal cancer pain: A systematic review. *Pain Med* 2013;14:1140-63.
- Lieb JG 2nd, Forsmark CE. Review article: Pain and chronic pancreatitis. *Aliment Pharmacol Ther* 2009;29:706-19.

How to cite this article: Choudhary NS, Puri R. EUS-guided celiac plexus neurolysis/block. *J Dig Endosc* 2013;4:99-102.

Source of Support: Nil, **Conflict of Interest:** None declared.