Published online: 2019-09-26

Case Report

Cystic lesion of pancreas – Intraductal papillary mucinous neoplasm

Rajiv Baijal, Praveen Kumar H. R., Deepakkumar T. Gupta, Nimish Shah, D. Amarapurkar, Parijat Gupte

Department of Gastroenterology, Jagjivanram Hospital, Mumbai, Maharashtra, India

Abstract

Intraductal papillary mucinous neoplasm (IPMN) of the pancreas is an intraductal mucin-producing epithelial neoplasm that arises from the main and/or branched pancreatic duct. It usually presents as cystic lesion of pancreas. There are well known differential diagnosis of cystic pancreatic lesion. Pancreatic cystic neoplasms are detected at an increasing frequency due to an increased use of abdominal imaging. The diagnosis and treatment of intraductal papillary mucinous tumors (IPMN) of the pancreas has evolved over the past decade. IPMN represents a spectrum of disease, ranging from benign to malignant lesions, making the early detection and characterization of these lesions important. Definitive management is surgical resection for appropriate candidates, as benign lesions harbor malignant potential. IPMN has a prognosis, which is different from adenocarcinoma of the pancreas. We report a case of a 58-year-old male with intraductal papillary neoplasm involving main duct and side branches presenting to us with clinical symptoms of chronic pancreatitis with obstructive jaundice and cholangitis treated surgically.

Key words

IPMN, mucinous cystadenocarcinoma, pancreatic cystic neoplasm, pseudocyst, serous cystadenoma

Introduction

Intraductal papillary mucinous neoplasm (IPMN) is a rare pancreatic cystic neoplasm accounting for 5% of all pancreatic neoplasm. It presents as a cystic lesion of pancreas and is increasingly being diagnosed with the advent of recent advances in imaging even in asymptomatic patients. It has to be differentiated from pseudocyst of pancreas for which treatment is entirely different. We report a case of intraductal papillary neoplasm who presented to us with clinical symptoms of chronic pancreatitis with obstructive jaundice and cholangitis.

Access this article online	
Website: www.jdeonline.in	Quick Response Code
DOI: 10.4103/0976-5042.129987	

Case Report

A 58-year-old male nonalcoholic, normotensive patient with history of type 2 diabetes mellitus since 4 years presented to us with complaints of intermittent epigastric pain radiating to back since 2 years, with worsening of pain since past 3 months associated with occasional nonbilious vomiting and jaundice. The jaundice has been progressively increasing and was not associated with itching or pale stools. He noticed a significant weight loss of 18 kg in the past 2 years associated with decrease in appetite due to sitophobia. Patient also had intermittent high grade fever associated with chills for which he was treated with antibiotics by the local practitioner. Investigations done at another hospital showed Hb 11.2 g%; WBC, 16700; platelets 170000; PT INR 1.24; total serum bilirubin 12.5 mg% with direct bilirubin of 8.2 mg%; serum alkaline phosphatase 463 IU/L; serum SGOT/SGPT 68/62 IU/L; and serum total protein 6.3g% with serum albumin of 2.8 g%. Ultrasonography abdomen showed dilated common bile duct (CBD) in its entire course with multiple cystic lesion in body and head region, largest measuring 8 cm in diameter containing debris with dilated pancreatic duct in the tail region suggestive of multiple pseudocysts of pancreas with chronic pancreatitis with suspicion of stricture in distal CBD.

Address for correspondence:
Dr. Deepak kumar Gupta, Jagjivanram Hospital Doctors Hostel D-71, Room No. 102, Mumbai Central, Mumbai, Maharashtra, India. E-mail: dkgt@rediffmail.com

Patient underwent further evaluation at our centre and a computed tomography (CT) scan was done that showed a mass of 7.6 × 4.8 cm in the head and body with predominantly cystic component with solid component and debris within the mass; the tail of the pancreas appeared atrophic with rest of the pancreatic parenchyma replaced by the mass and dilated CBD possibly due to compression by the mass with intrahepatic biliary radicles dilated and mildly enlarged liver [Figure 1]. Tumor markers revealed CA19-9 of 1020 U/ml, carcino-emryonic antigen (CEA) of 38 ng/ml and alpha fetoprotein of 10 ng/ml. In view of the mass, endoscopic ultrasonography (EUS) was performed, which showed multiple cystic lesions with thick fluid interspersed with solid component. EUS-guided fine needle aspiration cytology (FNAC) and cystic fluid aspiration [Figure 2] were done, which were negative for malignant cells but positive for mucin and elevated CA19-9 and CEA level. In view of cholangitis, the patient was treated with antibiotics and underwent endoscopic retrograde cholangiopancreatography (ERCP). At ERCP, a thick, viscous whitish mucin-like fluid was seen coming out of the protruding papilla [Figure 3], however, CBD could not be cannulated and patient underwent percutaneous transhepatic biliary drainage

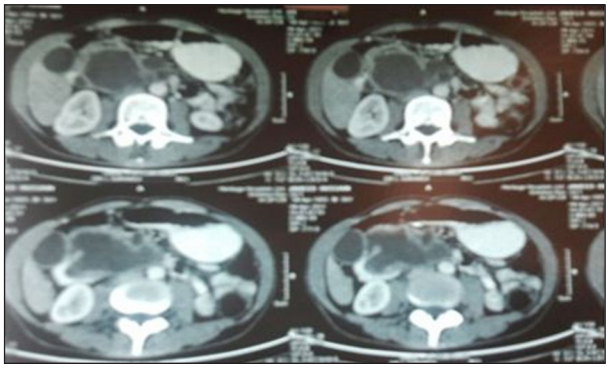

Figure 1: CT Abdomen

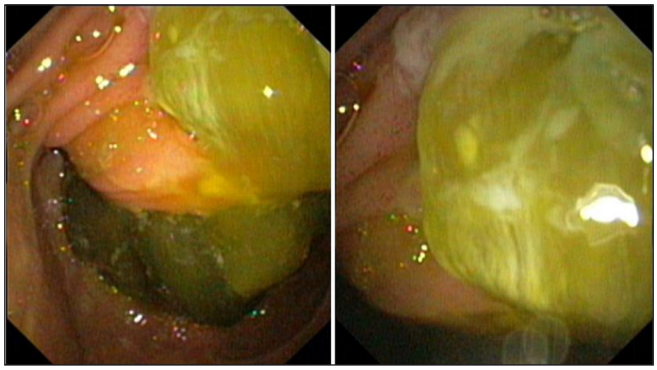

Figure 3: Endoscopic Images

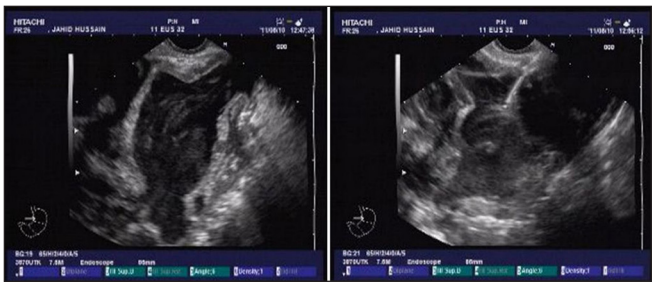

Figure 2: EUS and EUS-guided Aspiration

Figure 4: PTBD

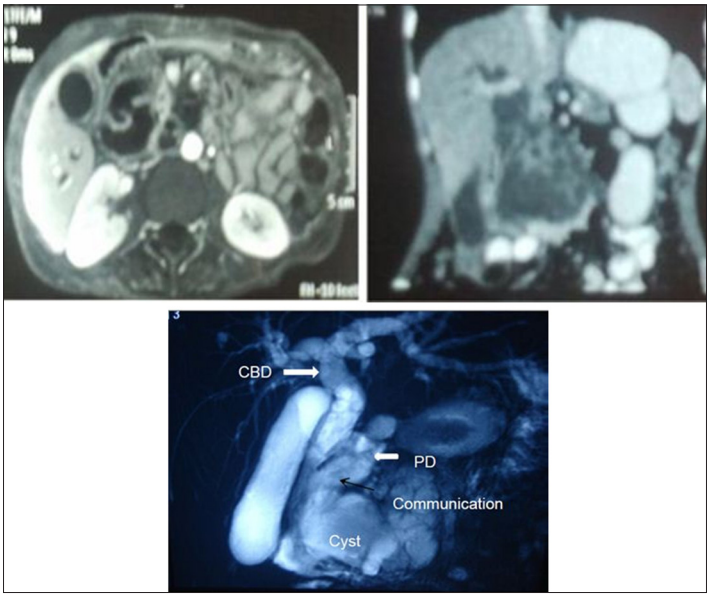

Figure 5: MRI images 5a, MRI Images 5b, MRI images 5c

Figure 6: Resected specimen

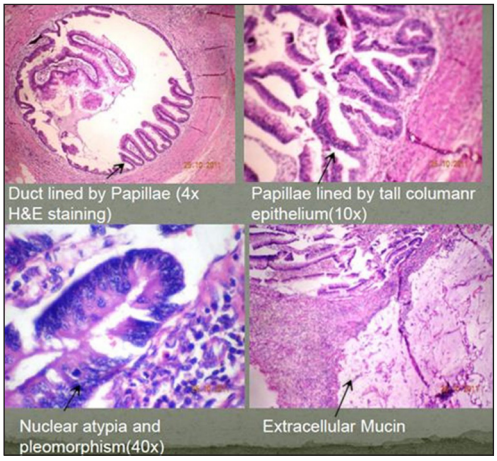

Figure 7: Histological Photos

(PTBD) in the right hepatic duct to treat cholangitis [Figure 4]. Patient underwent MRCP for defining the ductal anatomy of pancreas, which showed it to be a main duct IPMN with side branches involvement and eroding the right hepatic duct [Figure 5]. Patient's symptoms improved with drainage procedure and became afebrile with a drop in bilirubin. After taking care of his nutritional status, he underwent near total pancreactectomy [Figures 6 and 7].

Discussion

Cystic lesions of the pancreas include pseudocysts, congenital cysts, and cystic neoplasms. The major histologic subtypes of cystic neoplasm include (a) serous cystic neoplasm (SCN), (b) mucinous cystic neoplasm (MCN), (c) IPMN, and (d) solid pseudopapillary neoplasms (SSPN).[1]

IPMN – first reported by Ohashi,[2] accounts for 5% of pancreatic neoplasm.[3-7] Based on the pattern of involvement of pancreatic duct, IPMN can be classified as main duct-IPMN, branched duct-IPMN and mix-IPMN with frequencies of main duct – IPMN in 57–97% cases, and branched duct – IPMN in 6–46%. The mix type has 35–40% malignant potential in surgically resected specimen.[2,8,9] It is necessary to differentiate cystic neoplasm from pseudocyst of pancreas. Diagnosis of IPMN is usually done by imaging such as multidetector CT scan and MRCP. EUS with fine needle aspiration along with cystic fluid for analysis for viscosity and tumor markers can be used for confirming the diagnosis.(Table no.1) Aspiration cytology of cystic fluid showed thick mucin in IPMN[10-12] and branching papillae and a myxoid stroma in SSPN[13] Treatment of IPMN is mainly resection except for branch duct – IPMN, which is less than 3 cm and does not show any malignant features.

Acknowledgment

The authors acknowledge the assistance of Dr. P.J. Halder, HOD Department of GI Surgery and Dr. I Bhattacharya, HOD Department of Pathology.

References

Table 1: Characteristics of pancreatic cystic lesions

	Pseudocyst	SCN	MCN	IPMN	SPPN
Age	Any	7th decade	4–5th decade	7th decade	2–3rd decade
Sex	Any	Female	Female	Any	Female
Location	Head/body	Any	Body/tail	Head	Any
Diagnosis	Macrocystic, thick walled, unilocular, internal debris	Conglomerate multiple small cystic collection (honey comb appearance)	Unifocal, unilocular macrocystic lesion	MD-IPMN: diffusely or segmentally dilated tortuous pancreatic duct with filling defects	Large well-encapsulated lesion with mixed solid and cystic components giving rise to a heterogeneous appearance
Cystic fluid	Clear, nonmucinous	Clear, glycogen rich cells	Thick, mucin+ ovarian stroma on histology[8]	Thick mucin+[10-12]	Clear, branching papillae and a myxoid stroma may be diagnostic[13]
CEA	Variable	Low	High	High	Variable
Amylase	High	Low	Low	High	-

1. Bassi C, Sarr MG, Lillemoe KD, Reber HA. Natural history of intraductal papillary mucinous neoplasms (IPMN): Current evidence and implications for management. J Gastrointest Surg 2008;12:645-50.
2. Ohashi K, Murakami Y, Mardyama M. Four cases of "mucin producing" cancer of the pancreas on specific findings of the papilla of Vater. Prog Dig Endosc 1982;20:348-51.
3. Sohn TA, Yeo CJ, Cameron JL, Hruban RH, Fukushima N, Campbell KA, *et al*. Intraductal papillary mucinous neoplasms of the pancreas: An updated experience. Ann Surg 2004;239:788-97.
4. Chari ST, Yadav D, Smyrk TC, DiMagno EP, Miller LJ, Raimonda M, *et al*. Study of recurrence after surgical resection of intraductal papillary mucinous neoplasm of the pancreas. Gastroenterology 2002;123:1500-7.
5. Bernard P, Scoazec JY, Joubert M, Kahn X, Le Borgne J, Berger F, *et al*. Intraductal papillary-mucinous tumors of the pancreas: Predictive criteria of malignancy according to pathological examination of 53 cases. Arch Surg 2002;137:1274-8.
6. Maire F, Hammel P, Terris B, Paye F, Scoazec JY, Cellier C, *et al*. Prognosis of malignant intraductal papillary mucinous tumours of the pancreas after surgical resection. Comparison with pancreatic ductal adenocarcinoma. Gut 2002;51:717-22.
7. Schnelldorfer T, Sarr MG, Nagorney DM, Zhang L, Smyrk TC, Qin R, *et al*. Experience with 208 resections for intraductal papillary mucinous neoplasm of the pancreas. Arch Surg 2008;143:639-46.
8. Tanaka M, Chari S, Adsay V, Fernandez-del Castillo C, Falconi M, Shimizu M, *et al*. International consensus guidelines for management of intraductal papillary mucinous neoplasms and mucinous cystic neoplasms of the pancreas. Pancreatology 2006;6:17-32.
9. Salvia R, Fernandez-del Castillo C, Bassi C, Thayer SP, Falconi M, Mantovani W, *et al*. Main-duct intraductal papillary mucinous neoplasms of the pancreas: Clinical predictors of malignancy and long-term survival following resection. Ann Surg 2004;239:678-85.
10. D'Angelica M, Brennan MF, Suriawinata AA, Klimstra D, Conlon KC. Intraductal papillary mucinous neoplasms of the pancreas: An analysis of clinicopathologic features and outcome. Ann Surg 2004;239:400-8.
11. Levy P, Jouannaud V, O'Toole D, Couvelard A, Vullierme MP, Palazzo L, *et al*. Natural history of intraductal papillary mucinous tumors of the pancreas: Actuarial risk of malignancy. Clin Gastroenterol Hepatol 2006;4:460-8.
12. Kobari M, Egawa S, Shibuya K, Shimamura H, Sunamura M, Takeda K, *et al*. Intraductal papillary mucinous tumors of the pancreas comprise 2 clinical subtypes: Differences in clinical characteristics and surgical management. Arch Surg 1999;134:1131-6.
13. Bardales RH, Centeno B, Mallery JS, Lai R, Pochapin M, Guiter G, *et al*. Endoscopic ultrasound-guided fine-needle aspiration cytology diagnosis of solid-pseudopapillary tumor of the pancreas: A rare neoplasm of elusive origin but characteristic cytomorphologic features. Am J Clin Pathol 2004;121:654-62.

How to cite this article: Baijal R, Praveen Kumar HR, Gupta DT, Shah N, Amarapurkar D, Gupte P. Cystic lesion of pancreas - Intraductal papillary mucinous neoplasm. J Dig Endosc 2013;4:93-6.

Source of Support: Nil, **Conflict of Interest:** None declared.

Staying in touch with the journal

1) Table of Contents (TOC) email alert

Receive an email alert containing the TOC when a new complete issue of the journal is made available online. To register for TOC alerts go to **www.jdeonline.in/signup.asp.**

2) RSS feeds

Really Simple Syndication (RSS) helps you to get alerts on new publication right on your desktop without going to the journal's website. You need a software (e.g. RSSReader, Feed Demon, FeedReader, My Yahoo!, NewsGator and NewzCrawler) to get advantage of this tool. RSS feeds can also be read through FireFox or Microsoft Outlook 2007. Once any of these small (and mostly free) software is installed, add **www.jdeonline.in/rssfeed.asp** as one of the feeds.