Published online: 2019-09-26

Case Report

Open safety pin ingestion – Usual method of removal in an unusual way

Sathya G., Balamurali R., Ganesh P., Jeevankumar S.

Department of Digestive Health and Diseases, Government Peripheral Hospital, Annanagar, Chennai, India

Abstract

Single foreign body ingestion is a common scenario that is commonly encountered by gastroenterologists. The symptoms tend to be nonspecific and most of the foreign bodies pass spontaneously. Ingestion of sharp foreign bodies is also not uncommon. It can lead to complications like impaction or perforation. Most of these ingested foreign bodies can be retrieved with endoscopy. We report a 25-year-old patient who underwent successful endoscopic removal of an open safety pin that was ingested accidentally 3 months previously and was impacted at the junction of first and second parts of the duodenum, using a side-view duodenoscope. The presentation of a sharp foreign body without complications which is impacted for 3 months is unusual and its endoscopic extraction without complication is equally uncommon.

Key words

Duodenum, impacted open safety pin, side-viewing scope

Introduction

Foreign body ingestion is common in children and adults. Single or multiple foreign bodies can be encountered. Alcohol and psychiatric conditions are usually associated in adults with foreign body ingestion. Endoscopic intervention is essential at the right time to prevent complications.[1,2]

Case Report

A 25-year-old male, referred from a private hospital, presented with complaints of mild abdominal pain, non-specific in character, in the periumbilical region of 1 week duration. Past history was remarkable for accidental ingestion of an open safety pin 3 months back, and the patient had remained asymptomatic since ingestion until now. Physical examination revealed no abnormality. Abdominal examination was found to be normal.

Access this article online	
Website: www.jdeonline.in	Quick Response Code
DOI: 10.4103/0976-5042.129984	

The patient had already been investigated outside our hospital with plain X-ray abdomen and ultrasonography of the abdomen. Both imaging modalities revealed an open safety pin in the abdomen with no evidence of perforation. To confirm these findings, an erect plain X-ray abdomen was obtained which also revealed the same findings of open safety pin [Figure 1].

So, we planned for endoscopic removal of the safety pin. Written consent was obtained from the patient, and the risks and complications of endoscopic removal were also explained to the patient and his family members.

First we used forward-viewing endoscopy which showed an impacted open safety pin at the junction of first and second parts of the duodenum [Figure 2]. The spiral end was seen and the head end of the safety pin was impacted in the duodenal mucosa. As it was difficult for us to access the impacted foreign body with forward-viewing scope, we attempted removal of the impacted safety pin with side-viewing scope and rat tooth forceps [Figures 3 and 4] by catching the spiral end of the safety pin, and the scope was withdrawn successfully with retrieval of the pin. The hood was not used as it could not be fitted to a side-viewing scope. The open safety pin was retrieved without any injury to the upper gastrointestinal tract (GIT) [Figure 5]. The patient was kept under close monitoring, and check X-ray abdomen was obtained the next day which was normal.

Address for correspondence:
Dr. Sathya G., Department of Digestive Health and Diseases, Government Peripheral Hospital, Annanagar, Chennai- 600 102, India. E-mail: vrragb@rediffmail.com

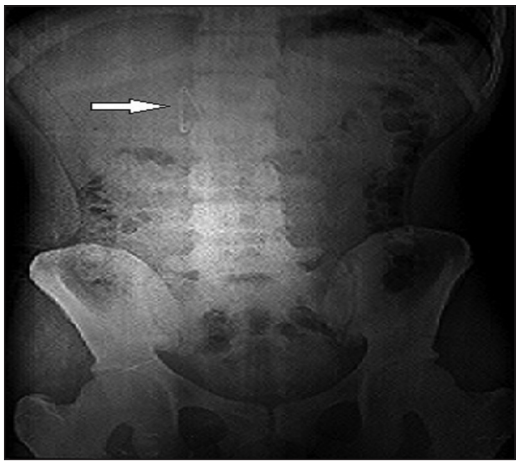

Figure 1: Plain X-ray abdomen showing open safety pin

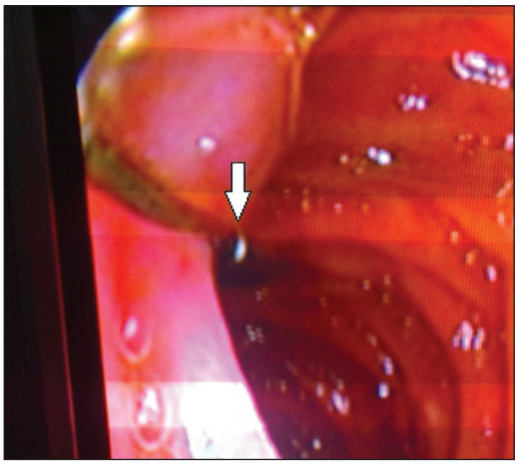

Figure 2: View with forward-viewing scope

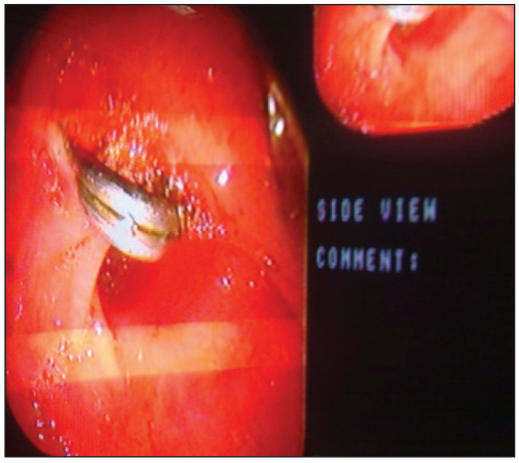

Figure 3: Spiral end of pin with side-viewing scope

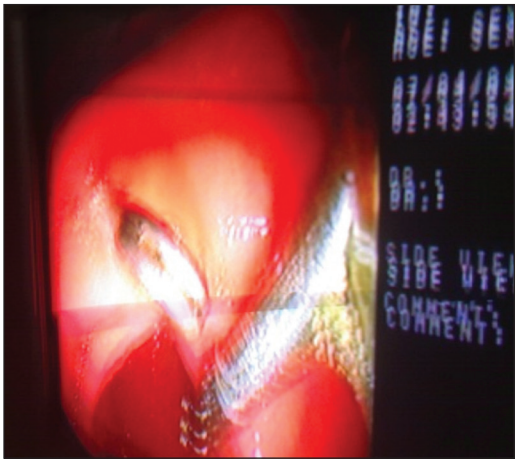

Figure 4: Removal with rat tooth forceps

Figure 5: Retrieved safety pin

We are presenting this interesting case report, as our patient who had an accidental ingestion of an open safety pin 3 months back had no symptoms and signs of perforation, even though the open safety pin was found impacted in the duodenum. The sharp foreign body was removed with side-viewing endoscope and rat tooth forceps without any complications and the need for surgical intervention was obviated.

Discussion

Unintentional foreign body ingestion is common in both children and adults. Accidental ingestion is more common with children. Influence of alcohol and psychiatric disorders are common predispositions in adults to foreign body ingestion.[1] Coins, pins, button batteries, rings, stones, and nails are some of the commonly ingested things. Majority of the objects pass uneventfully through the GIT and the overall risk of perforation is 1%.[2] In adults, the foreign body ingestion is usually involuntary and can present as an emergency. Nevertheless, the clinical signs may vary and patients may present within hours to years of ingestion,[3,4] like our patient who presented after 3 months. Sharp objects should be removed immediately as they may lead to inadvertent complications like perforation, migration, and impaction in the bowel, as happened in our case.

Even though our patient presented to us 3 months after ingestion, the impacted safety pin was removed with the help of side-viewing scope and rat tooth forceps. Retrieval of the impacted safety pin by endoscopy is technically demanding. Bullaboy *et al.,*[5] in their case report, described the endoscopic retrieval of impacted safety pin by holding the rounded spring

end with a pair of rat tooth forceps with the help a forward-viewing scope, but in our case, the impacted safety pin was removed with rat tooth forceps using side-viewing scope which is still more technically challenging.

Gun *et al.,*[6] in their series of 49 patients with open safety pin (esophageal) impaction, have shown that endoscopic removal was possible in 14 patients. Kalayci *et al.,*[7] concluded in their study that open surgery or other invasive removal methods are not necessary in infants with open safety pin ingestion, and in their opinion, the best way to extract an open safety pin from the esophagus, stomach, or duodenum is by using a flexible endoscopic device. El Hajj *et al.,*[8] reported retrieval of a long foreign body from the stomach with a duodenoscope.

Morrissey *et al*.,[9] in their case report of a rare cause of upper gastrointestinal bleeding due to bread bag clip ingestion, have shown that endoscopic removal of the impacted foreign body with side-viewing scope and snare failed and the extraction was performed surgically.

Conclusions

Our patient in whom the open safety pin was impacted for 3 months in the junction of the first and second parts of the duodenum was asymptomatic until 1 week and endoscopic extraction with the help of side-viewing duodenoscope and rat tooth forceps was successful; no complications occurred. Flexible endoscopy is best used for removal of foreign bodies. In some cases, the blind spots and angulations encountered during forward-viewing endoscopy result in inadequate visualization and inaccessibility. In such cases, side-viewing scope may be helpful. This technique can be a safe and effective method in the hands of a skilled endoscopist in the right setting.

References

1. Webb WA. Management of foreign bodies of the upper gastrointestinal tract: Update. Gastrointest Endosc 1995;41:39-51.
2. Chang JJ, Yen CL. Endoscopic retrieval of multiple fragmented gastric bamboo chopsticks by using a flexible overtube. World J Gastroenterol 2004;10:769-70.
3. Green SM, Schmidt SP, Rothrock SG. Delayed appendicitis from an ingested foreign body. Am J Emerg Med 1994;12:53-6.
4. Sar S, Mahawar KK, Marsh R, Small PK. Recurrent appendicitis following successful conservative management of an appendicular mass in association with a foreign body: A case report. Cases J 2009;24:7776.
5. Bullaboy CA, Derkac WM, Johnson DH, Jennings RB Jr. False aneurysm of the aorta secondary to an esophageal foreign body. Ann Thorac Surg 1985;39:275-6.
6. Gun F, Salman T, Abbasoglu L, Celik R, Celik A. Safety pin ingestion in children. A cultural fact. Pediatr Surg Int 2003;19:482-4.
7. Kalayci A, Tander B, Kocak S, Rizalar R, Bernay F. Removal of open safety pins in infants by flexible endoscopy is effective and safe. J Laparoendosc Adv Surg Tech A 2007;17:242-5.
8. El Hajj II, Clarke BW, Slivka A. Retrieval of a long foreign body from the stomach with a duodenoscope. Endoscopy 2011;43:E107-8.
9. Morrisey SK, Thakkar SJ, Weaver ML, Farah K. Bread Bag Clip Ingestion: A rare cause of upper gastrointestinal bleeding. J Gastroenterol Hepatol 2008;4:499-500.

How to cite this article: Sathya G, Balamurali R, Ganesh P, Jeevankumar S. Open safety pin ingestion - Usual method of removal in an unusual way. J Dig Endosc 2013;4:87-9.
Source of Support: Nil, **Conflict of Interest:** None declared.

Announcement

Android App

A free application to browse and search the journal's content is now available for Android based mobiles and devices. The application provides "Table of Contents" of the latest issues, which are stored on the device for future offline browsing. Internet connection is required to access the back issues and search facility. The application is compatible with all the versions of Android. The application can be downloaded from https://market.android.com/details?id=comm.app.medknow. For suggestions and comments do write back to us.