Published online: 2019-09-26

Original Article

Button battery ingestion in children: An emerging hazard

Mayank Jain, Chandrashekhar Waghmare, Sagar Adkar, Shohini Sircar, Ajay K. Jain

Department of Gastroenterology, Choithram Hospital and Research Centre, Indore, Madhya Pradesh, India

Abstract

Button battery ingestion is an emerging hazard. In this retrospective study, we report six cases of lithium button battery ingestion in pediatric age group (mean age 2.8 years). Three button batteries were removed from stomach and three from esophagus. Esophageal site was associated with significant local injury, and one button battery was impacted in the esophagus, requiring rigid esophagoscopy for removal. Small battery size, used batteries, and early removal (<12 h after ingestion) were associated with lesser mucosal injury. No long-term complications were noted. Our study emphasizes that early diagnosis and urgent removal of ingested button battery are the only measures which prevent complications.

Key words

Button battery, foreign body ingestion, ingestion, injury

Introduction

Battery ingestion in children is an emerging hazard. With the use of button batteries in toys and easy accessibility to these batteries, the incidence of accidental ingestions is increasing.[1]

In the United States, 3461–3758 battery ingestions were reported between 2007 and 2009. Around 70% events occurred in children less than 6 years of age and 21% events occurred in children between 6 and 19 years.[2] Though the incidence of manganese dioxide, zinc air, mercuric oxide, and silver oxide ingestion is coming down, there has been a steady rise in the incidence of lithium battery ingestion.

There is no data from India regarding this clinical scenario. We hereby report six patients with lithium button battery ingestion seen by us in a 2-year period.

Access this article online

Website: www.jdeonline.in

Quick Response Code

DOI: 10.4103/0976-5042.129969

Case Reports

While reviewing the endoscopic records of the department of 2 years (2011 and 2012), we identified six cases of button battery ingestion (five batteries shown in Figure 1). The records of all the six cases were analyzed in terms of age, sex, time of presentation to hospital and time of endoscopy, severity of injury, and outcome. Follow-up data were collected from the outpatient files and long-term complications were studied.

Data of our six patients are shown in Table 1.

Case 1

A 1-year-old female child presented with history of ingestion of button battery 9 h before presentation. Baby was completely asymptomatic and history revealed ingestion of used battery from a toy. Chest X-ray revealed radio-opaque round foreign body just below the cricopharynx.

Esophagogastroduodenoscopy was performed within 4 h of hospitalization. A single, 12-mm button battery was removed endoscopically with the help of tripod forceps. Near-circumferential, superficial, non-bleeding ulceration with black pigmentation was noted 4 cm below the cricopharynx. Patient was started on oral feeds after 12 h.

On follow-up at 2 months, the child was asymptomatic, feeding well, and had a normal endoscopy.

Address for correspondence:
Dr. Mayank Jain, Department of Gastroenterology, Choithram Hospital and Research Centre, 297, Indrapuri, Near Bhanwarkuan, Indore- 452 017, Madhya Pradesh, India. E-mail: mayank4670@rediffmail.com

Table 1: Clinical data of our patients

Age in years and sex	Interval between ingestion and presentation (in hours)	Interval between ingestion and endoscopy (in hours)	Location of battery	Size of battery (in mm)	Used or unused battery	Severity of injury
1 F	9	13	Esophagus: 4 cm below cricopharynx	12	Used	Circumferential ulceration with black spot Removed endoscopically
5 M	4	4	Stomach	12	Used	Few erosions Removed endoscopically
4 M	8	12	Esophagus: at 15 cm from incisors	20	Unused	Circumferential ulcers, necrosis, and slough Required removal using rigid esophagoscope
2 F	4	6	Esophagus	6	Used	No mucosal injury
3 F	6	10	Stomach	12	Used	No mucosal injury
2 M	8	4	Stomach	12	Used	No mucosal injury

Figure 1: Various sized batteries removed and the size compared to that of a two rupee coin

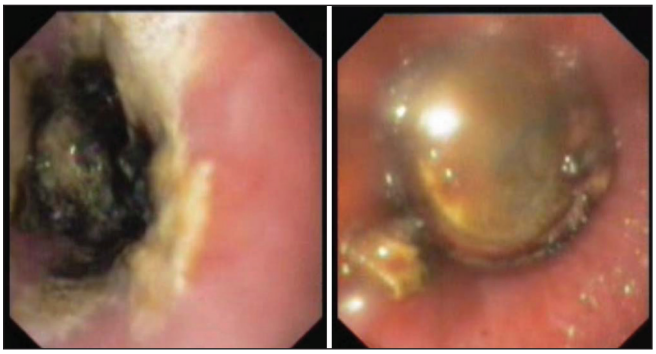

Figure 2: Endoscopic image of the impacted battery and surrounding ulceration in the esophagus

Case 2

A 5-year-old male child presented with history of accidental button battery ingestion. Patient was asymptomatic and immediate endoscopic removal was done within 4 h of hospitalization. No mucosal injury was noted in the esophagus, stomach, and duodenum.

Case 3

A 4-year-old boy presented 8 h after ingestion of button battery, with the complaint of cough with expectoration. He had no history of fever, breathlessness, chest pain, or hematemesis. He underwent esophagogastroduodenoscopy after 12 h of hospitalization. Circumferential ulcers with necrosis and lots of slough were noted at 15 cm. Battery was impacted in the esophageal mucosa and could not be removed [Figure 2]. Rigid esophagoscopy was performed and a 20 mm button battery was removed. Post removal, the patient was kept nil by mouth for 24 h. Barium study done after 1 day showed no obvious fistula and he was started on liquids. Later, he was switched over to normal feeds. On follow-up at 2 months, he was asymptomatic and barium study showed no stricture or fistula.

Cases 4–6

Three children, aged between 2 and 3 years, presented with history of accidental ingestion of used button batteries. These foreign bodies were removed using tripod forceps and Roth net. The children had no mucosal injury and had uneventful recovery.

Discussion

With increasing use of batteries in household items, they have become a major cause of accidental foreign body ingestion. About 90% of patients remain asymptomatic and pass battery in stool within 2–7 days after ingestion and the remaining patients present with minor upper gastrointestinal (GI) symptoms like refusal to take fluids, increased salivation (often with black flecks in the saliva), dysphagia, vomiting, and occasionally hematemesis. Thus, a high degree of clinical suspicion is required.

Most battery ingestions are benign, although large-diameter cells may produce serious injury and must be removed. Button cells of 15–18 mm in diameter generally pass

Table 2: Guidelines for management of button battery ingestion[3-7]

Index of suspicion should be high because many cases are asymptomatic
Plain radiography of chest and abdomen not only confirms the diagnosis but also locates the site of the battery
Avoid cathartics and vomiting as both are ineffective
Assays of blood or urine for mercury or other battery ingredients are not required
The battery located within the esophagus should be removed within 2 h of ingestion because of the potential to cause mucosal injury. This is much shorter time period compared to previous reports, as lithium batteries have higher capacitance and voltage. Hemorrhage occurs within 12–14 h of ingestion and may be fatal
Batteries which have passed into the stomach need not to be extracted on emergent basis. Such batteries must be removed if they fail to cross pylorus in 8 h, if patients have GI symptoms or when the size of the battery is large
Specific complications like tracheoesophageal fistula and aortoesophageal fistula occur between 9 and 18 days of ingestion, depending upon the location of negative pole
Length of observation, duration of esophageal rest, and need for serial imaging and endoscopy/bronchoscopy are determined based on the location and severity of injury
Complications include esophageal perforation, tracheoesophageal fistula, mediastinitis, vocal cord paralysis, tracheal stenosis, aspiration pneumonia, empyema, abscess, pneumothorax, spondylodiscitis, and perforation into large vessels

through the gut uneventfully and their removal is rarely indicated if they pass beyond the esophagus and are asymptomatic.[1]

We came across six lithium button battery ingestion cases in 2 years (2011 and 2012). Mean age at presentation was 2.8 years (range 1–5 years). Male to female ratio was 1:1. Three button batteries were removed from the stomach and three from the esophagus. Esophageal site was associated with significant local injury, and one button battery was impacted in the esophagus, requiring rigid esophagoscopic removal. Small-sized batteries, used batteries, and early removal (less than 12 h after ingestion) were associated with lesser mucosal injury. One patient who underwent delayed endoscopic removal had severe mucosal injury, but fortunately, there were no long-term complications. We did not come across any case of neglected battery ingestion during our study period, though it has been reported in the literature.[3]

Literature review shows that the risk factors for more severe outcome include the following:[2] (i) size of the battery more than 20 mm; (ii) age less than 4 years; (iii) chemical system of the battery being more severe with lithium batteries; (iv) new cells produce 3.2 times more severe injury compared to spent cells; and (v) concomitant ingestion of battery with magnet. Lithium battery ingestion causes injury as a result of mechanisms which include the following:[3-7] (i) generation of an external electrolytic current that hydrolyzes the tissue fluid and produces hydroxides at the negative pole of the battery – lithium cells are 3 V cells and generate more current than ordinary cells; (ii) leakage of alkaline electrolyte; and (iii) physical pressure on the adjacent tissues. The clinical outcome of these cases is guided by[3-7] the following factors: (i) negative battery pole, identifiable as narrow side on lateral radiograph, causes more severe injury; (ii) necrosis is associated with worse outcome; and (iii) position of narrower negative pole identified on a lateral radiograph.

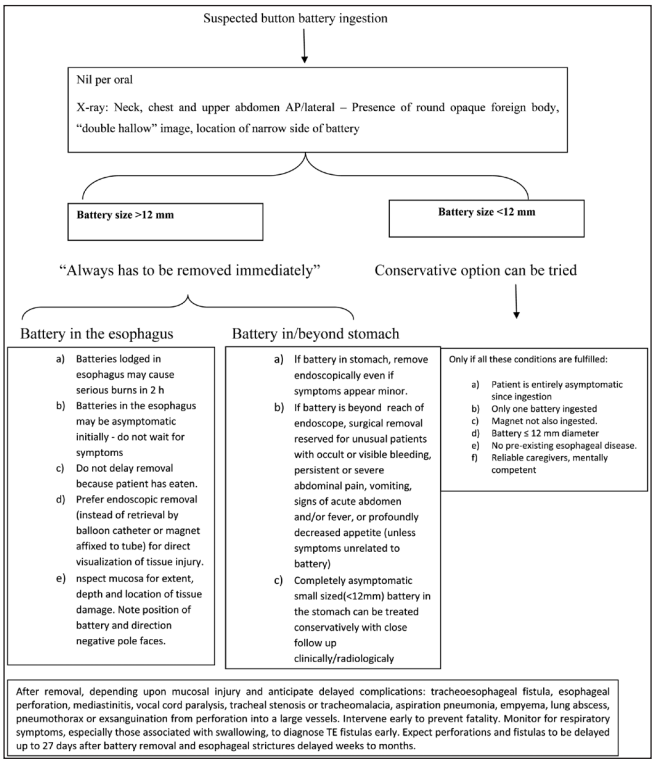

Figure 3: Algorithm in the management of button battery ingestion[2]

The management issues have been summarized in Table 2 and Figure 3.[3-7]

Conclusion

To conclude, early diagnosis of ingestion of button battery is important to avoid life-threatening complications. Presence of battery in esophagus is an emergency. Parents, primary health care workers, and pediatricians need to be educated about the hazards related with button battery ingestion. Moreover, we need to have data on the incidence and complications in India. This would help us to formulate better management strategies and reduce morbidity.

References

1. Litovitz T, Whitaker N, Clark L, White NC, Marsolek M. Emerging battery-ingestion hazard: Clinical implications. Pediatrics 2010;125:1168-77.
2. Available from: http://pediatrics.aappublications.org/cgi/content/full/peds.2009-3037/DC1 [Last accessed on 2012 Sep 19].
3. Abdollahi Fakhim S, Bayazian G, Sohrabpour M. Neglected esophageal button battery ingestion: Local protocol for management. Egypt J Ear Nose Throat Allied Sci 2013;14:27-31.
4. Yamashlta M, Saito S, Koyama K, Hattori H, Ogata T. Esophageal electrochemical burns by button type alkaline batteries in dogs. Vet Hum Toxicol 1987;29:226-30.
5. Yoshikawa T, Asai S, Takekawa Y, Kida A, Ishikawa K. Experimental investigation of battery induced esophageal burns in rabbits. Crit Care Med 1997;25:2039-44.
6. Yasui T. Hazarous effects due to alkaline button battery ingestion: An experimental study. Ann Emerg Med 1986;15:901-6.
7. Langkau JF, Noesges RA. Esophageal burns from battery ingestion. Am J Emerg Med 1985;3:265.

How to cite this article: Jain M, Waghmare C, Adkar S, Sircar S, Jain AK. Button battery ingestion in children: An emerging hazard. J Dig Endosc 2013;4:71-4.

Source of Support: Nil, **Conflict of Interest:** None declared.

Author Help: Reference checking facility

The manuscript system (www.journalonweb.com) allows the authors to check and verify the accuracy and style of references. The tool checks the references with PubMed as per a predefined style. Authors are encouraged to use this facility, before submitting articles to the journal.

- The style as well as bibliographic elements should be 100% accurate, to help get the references verified from the system. Even a single spelling error or addition of issue number/month of publication will lead to an error when verifying the reference.
- Example of a correct style
  Sheahan P, O'leary G, Lee G, Fitzgibbon J. Cystic cervical metastases: Incidence and diagnosis using fine needle aspiration biopsy. Otolaryngol Head Neck Surg 2002;127:294-8.
- Only the references from journals indexed in PubMed will be checked.
- Enter each reference in new line, without a serial number.
- Add up to a maximum of 15 references at a time.
- If the reference is correct for its bibliographic elements and punctuations, it will be shown as CORRECT and a link to the correct article in PubMed will be given.
- If any of the bibliographic elements are missing, incorrect or extra (such as issue number), it will be shown as INCORRECT and link to possible articles in PubMed will be given.