

Adult Hepatic Mesenchymal Hamartoma: An Unusual Case

Madhawi Sharma, Preeti Bansal, Neeraj Krishna Goyal

Department of Laboratory Medicine, Fortis Escorts Hospital, SRL Ltd., Jaipur, Rajasthan, India

Address for correspondence: Dr. Preeti Bansal, E-mail: drpreeti2000@gmail.com

ABSTRACT

Mesenchymal hamartoma is a benign hamartomatous lesion with unknown histogenesis. It generally occurs in pediatric population and has been rarely reported in adults. We report an unusual case of a cystic mesenchymal hamartoma of liver in an 81-year-old elderly male. A provisional diagnosis of liver abscess was made and definitive histopathology confirmed the diagnosis. This case has been reported because of its rarity.

Key words: Left lobectomy, liver, mesenchymal hamartoma

INTRODUCTION

Mesenchymal hamartoma is a pediatric tumor occurring uncommonly in patients older than 5 years and is rarely reported in adult population.^[1,2] It usually presents as an abdominal mass or with symptoms of compression of adjacent organs.^[1] In certain cases, it presents as an asymptomatic mass and incidentally detected during radiological investigations. This tumor is usually cystic but can be solid or mixed.^[3] The cystic nature of the tumor is attributed to the cystic degeneration of myxomatous mesenchyme or cystic dilatation of malformed bile ducts. Routine hematoxylin and eosin staining and immunohistochemistry studies have revealed mesenchymal hamartoma to be composed of spindle cells (positive for smooth muscle actin and vimentin; negative for CD31, CD34 and S-100) and bile ducts (positive for cytokeratin-7 [CK-7] and negative for CK-20).^[4]

CASE REPORT

An 81-year-old, elderly male patient presented to our hospital with a history of abdominal discomfort and

distension for 20 days. His laboratory investigations, including complete blood count, prothrombin time, activated partial thromboplastin time, serum bilirubin, serum alpha-fetoprotein and viral markers serology were within the normal limits. Liver enzymes were slightly elevated (aspartate aminotransferase [serum glutamic oxaloacetic transaminase]: 40 U/L [N: 15-37 U/L], alanine aminotransferase [serum glutamic-pyruvic transaminase]: 70 U/L [N: 30-65 U/L], alkaline phosphatase: 277 U/L [N: 50-136 U/L] and gamma-glutamyl transferase: 105 U/L [N: 5-85 U/L]).

On abdominal sonography, a large cystic lesion in the left lobe of liver with thinned out peripheral hepatic parenchyma and few well-defined small hepatic cysts in right lobe of liver were reported. The computed tomography scan was suggestive of abscess in left lobe with perilesional edema (approximately 21.8 × 12.3 × 18.6 cm) and few small cysts in right lobe of liver. On the basis of signs and symptoms and radiological investigations, a provisional clinical diagnosis of liver abscess was made and taken up in the OT for abscess drainage.

Per operatively, a large cystic space occupying lesion containing turbid fluid was seen replacing the whole left lobe and so the patient underwent resection of left lobe with drainage. Left lobectomy specimen was received in our lab for histopathological examination. Gross examination revealed a flap like wall of a cyst measuring 21 × 10 cm with wall thickness ranging from 0.5 to 1.5 cm. Its outer surface was smooth grayish

Access this article online	
Quick Response Code: 	Website: www.jlponline.org
	DOI: 10.4103/0974-2727.141514

brown. Appearance of inner surface was dirty grayish brown rough with multiple small protrusions varying in size from 0.3 to 1 cm in diameter [Figure 1]. Normal liver tissue of size 6 × 2 × 2 cm was also identifiable at periphery of the specimen.

On light microscopy, representative sections revealed mixture of hepatocytes arranged in clusters and fibromyxoid stroma. Ductular structures embedded in fibrous stroma along with adipose tissue, nerve bundles, and congested blood vessels were also seen [Figure 2]. Sections from normal looking liver tissue were unremarkable with normal liver histology. The final histological diagnosis of mesenchymal hamartoma was made.

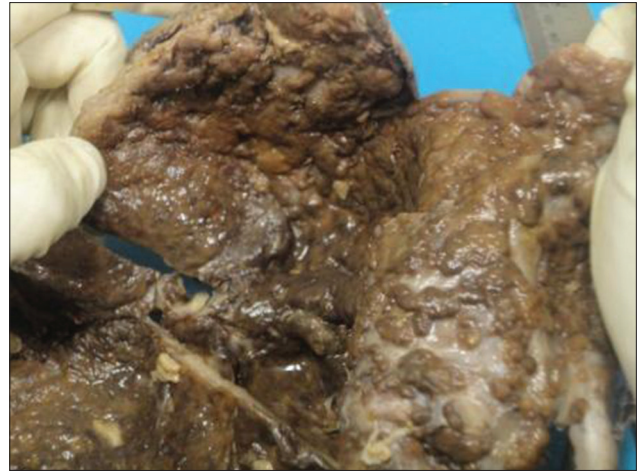


Figure 1: Gross picture of specimen of mesenchymal hamartoma

DISCUSSION

Mesenchymal hamartoma is an uncommon benign hepatic lesion. It constitutes approximately 8% of all pediatric tumors and only a few cases have been reported in adults.

Only 31 cases of adult mesenchymal hamartoma have been previously reported as individual case reports in the English literature.^[5-7] Of these, 23 (74%) cases have been reported in females and only 8 (26%) in males with an average age of 40 and 57 years, respectively. As per literature review, there seems no predilection for a particular lobe involvement in the adult hepatic mesenchymal hamartoma. It has been equally (38.7%) reported in the right and left lobes of liver. However, in 22.6% cases involvement of both lobes of liver was seen. In 16 cases (51.6%), gross appearance of mesenchymal hamartoma was cystic, in 9 (29%) cases was solid and in 6 cases (19.4%) was both solid and cystic. Our patient was an 81-year-old elderly male presented with abdominal discomfort. In this case, mesenchymal hamartoma in the left lobe of liver with cystic gross appearance has been reported.

Currently, the pathogenesis of mesenchymal hamartoma is still under study, the hypothesis of its origin from synchronous abnormal mesodermal development has been postulated. It gradually enlarges up to large sizes, some can spontaneously regress and few can undergo malignant transformation to undifferentiated (embryonal) sarcoma. Karyotype study of undifferentiated embryonal sarcoma has revealed chromosomal rearrangement in 19q13.4, which is similar to that in mesenchymal hamartoma.^[8] This can be the probable explanation for the fact that mesenchymal hamartoma is potentially a premalignant lesion and might be a precursor lesion to undifferentiated embryonal sarcoma.

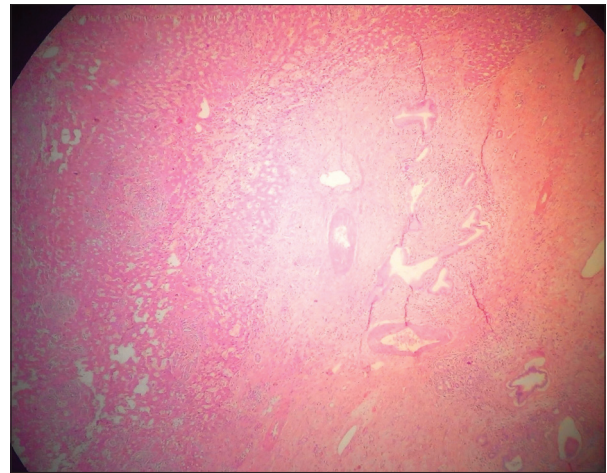


Figure 2: H and E stained microscopic section showing bile duct proliferation embedded in fibromyxoid stroma along with hepatocytes

CONCLUSION

Mesenchymal hamartoma is a rare hepatic lesion in adults, usually presents as a cystic lesion and can be a premalignant lesion. Biochemical findings are noncontributory in making its diagnosis and radiography is variable. Surgical excision is the main therapeutic modality and necessary to make final definitive histopathological diagnosis.

REFERENCES

1. Yen JB, Kong MS, Lin JN. Hepatic mesenchymal hamartoma. *J Paediatr Child Health* 2003;39:632-4.
2. Wada M, Ohashi E, Jin H, Nishikawa M, Shintani S, Yamashita M, *et al.* Mesenchymal hamartoma of the liver: Report of an adult case and review of the literature. *Intern Med* 1992;31:1370-5.
3. Karpelowsky JS, Pansini A, Lazarus C, Rode H, Millar AJ. Difficulties in the management of mesenchymal hamartomas. *Pediatr Surg Int* 2008;24:1171-5.
4. Cook JR, Pfeifer JD, Dehner LP. Mesenchymal hamartoma of the liver in the adult: Association with distinct clinical features and histological changes. *Hum Pathol* 2002;33:893-8.

Sharma, *et al.*: Adult hepatic mesenchymal hamartoma: An unusual case

5. Klaassen Z, Paragi PR, Chamberlain RS. Adult mesenchymal hamartoma of the liver: Case report and literature review. *Case Rep Gastroenterol* 2010;4:84-92.
6. Chung JH, Cho KJ, Choi DW, Lee BH, Chi JG. Solid mesenchymal hamartoma of the liver in adult. *J Korean Med Sci* 1999;14:335-7.
7. Hernández JC, Alfonso C, González L, Samada M, Ramos L, Cepero-Valdez M, *et al.* Solid mesenchymal hamartoma in an adult: A case report. *J Clin Pathol* 2006;59:542-5.
8. Talmon GA, Cohen SM. Mesenchymal hamartoma of the liver with an interstitial deletion involving chromosome band 19q13.4: A theory as to pathogenesis? *Arch Pathol Lab Med* 2006;130:1216-8.

How to cite this article: Sharma M, Bansal P, Goyal NK. Adult hepatic mesenchymal hamartoma: An unusual case. *J Lab Physicians* 2014;6:124-6.

Source of Support: Nil. **Conflict of Interest:** None Declared.