

## Case Report-III

# Non Hodgkin's Lymphoma of Tongue – A Case Report

BHARAT VASWANI, MITHUN SHAH, PM SHAH, BJ PARIKH, AS ANAND, GOPAL SHARMA

### ABSTRACT

**Primary non-Hodgkin's lymphoma (NHL) of the oral region is rare. Oral manifestations are present in 3-5% of cases of NHL and oral lesions are rarely the initial manifestation. We describe a 40 year old male who presented with a mass lesion primarily involving the tongue and was diagnosed as diffuse large B cell lymphoma. The patient was treated with CHOP chemotherapy with complete disappearance of lesion after first cycle. Pertinent literature is being reviewed.**

### INTRODUCTION

Extra nodal lymphomas represent 20-30% of non-Hodgkin' lymphoma (NHL).<sup>1</sup> Oral manifestations are seen in 3-5% of cases. An oral lesion as an initial manifestation is very rare. NHL commonly involves oropharyngeal lymphoid tissue comprising Waldeyer's ring but occasionally involves other oral tissues.<sup>2,3</sup> The paucity of cases makes the understanding of the biological behaviour and therapeutic options of lymphoma involving the oral region difficult. A proper clinical evaluation, histopathologic and immunohistochemical evaluation may aid in the diagnosis and thus help in management.

**CASE:** A 40 year male patient presented with history of slowly growing swelling on right lateral border of tongue of 2 months duration. He had no other symptoms like fever, night sweats, weight loss. Local examination revealed 5cm x 4cm firm nodular lesion involving lateral margin of right half of tongue (Fig 1). Other parts of oral cavity, oropharynx, and neck were normal. Systemic examination including

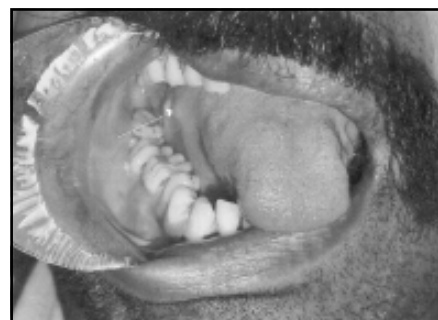

Figure 1 Lesion on lateral border of tongue (before Chemotherapy)

respiratory, cardiac, abdominal and central nervous system were normal. Investigations: Hb 12.4gm %, TLC  $8.2 \times 10^3$ /uL, DLC P- 80% L 20% platelets of  $2.17 \times 10^6$  /uL. Chest radiograph, head, neck and abdominal computed tomography were normal. CSF examination was unremarkable. HIV was non reactive. Bone marrow was uninvolved.

Histopathological examination of tongue lesion revealed discretely placed round cells with hyperchromic irregular nuclei, inconspicuous nucleoli, scanty to moderate amount of cytoplasm (Fig 2). Immuno-

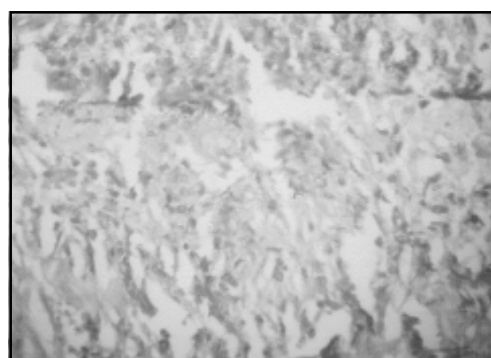


Figure 2 Biopsy from tange lesion: Discretely placed round cells with hyperchromatic irregular nuclei, inconspicuous nucleoli, scanty to moderate amount of cytoplasm (H & E 40x)

histochemical evaluation was positive for LCA and CD 20 (Fig 3) and negative for Cytokeratin



Figure 3 Immunohistochemical evaluation positive for CD 20 (40x)

(CK), CD-3, Vimentin, S-100 suggestive of Primary Non Hodgkin's Lymphoma Large B cell type. He was staged as IE. He was put on CHOP (cyclophosphamide, vincristine, adriamycin, prednisolone) chemotherapy. Post first cycle of chemotherapy, the lesion completely disappeared. (Fig 4). Further, he received 3 more cycles of CHOP, after which he did not turn up for subsequent radiotherapy.

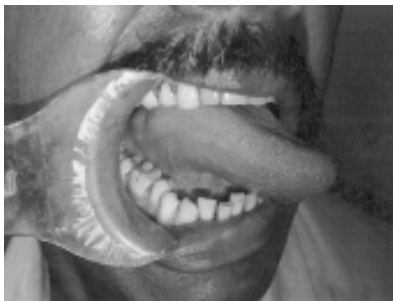

Figure 4 Complete Regression of lesion (After 1<sup>st</sup> cycle of chemotherapy)

## DISCUSSION

About 20%-30% of non-Hodgkin's lymphomas (NHL) arise from extra nodal sites.<sup>1</sup> Although lymphomas represent third most common group of malignant lesion of oral region following squamous cell carcinoma and salivary gland neoplasm,<sup>4</sup> their incidence is only 3-5% of which NHL of tongue is extremely rare.<sup>5</sup> NHL commonly involves oropharyngeal lymphoid tissue comprising Waldeyer's ring but occasionally involves other oral tissues.<sup>2,3</sup>

One such case of NHL tongue has been reported earlier from our Institute in 2001 by Maheshwari et al. She was a 30 year female with 2cm x 2cm nodular swelling of the right side of the tongue, diagnosed as T cell lymphoma. The patient was treated with wide excision followed by chemotherapy and radiotherapy.<sup>6</sup>

Touboul et al<sup>7</sup> found one case of NHL of tongue among 35 cases of head and neck NHL. Haidar<sup>8</sup> found 7 cases of NHL of tongue among 94 patients with extra nodal NHL of head and neck region. Wolvius et al<sup>9</sup> found 1 case of tongue involvement in 34 cases of oral primary extra nodal NHL. Slootweg et al,<sup>5</sup> Fukuda et al,<sup>10</sup> and Economopoulos et al,<sup>11</sup> on the other hand, found no tongue involvement respectively, in 20, 15 and 52 patients with extra nodal NHL of head and neck.

Little is known about the etiological factors for primary lymphoma of oral region. Few cases of oral lymphoma have been reported in association with AIDS. It generally affects the elderly, especially over 6<sup>th</sup> decade of life.<sup>5</sup> The most common symptoms are local swelling, pain and discomfort in the throat and ulcer.<sup>12</sup> Oral NHL may mimic more commonly benign oral and dental pathologic conditions. Because of its rarity, primary NHL of tongue is often misdiagnosed in beginning.<sup>2</sup> Most of the head and neck Non Hodgkin's lymphomas including oral lesions are of B cell origin and diffuse large cell type is the most common type.<sup>12</sup> The diagnosis of NHL can be made only by biopsy.

Like Lymphoma at other head and neck sites, oral lesions seem to be quite sensitive to both, chemotherapy and radiotherapy. The prognosis of NHL is related to the stage of the tumour, the aggressiveness of the malignant cell type, and the response to treatment.<sup>6</sup> Wolvius et al<sup>9</sup> reported median survival of 34 months with no difference in prognosis between patients with bone and soft tissue lymphoma. In conclusion, although oral lymphoma of tongue is very uncommon, it should always be considered in differential diagnosis of various benign and malignant lesions in this region because treatment and prognosis of this condition is very different.

## REFERENCES:

1. Clearly KR, Batsakis JG. Sinonasal lymphomas. *Ann Otol Rhinol Laryngol* 1994;03:911-4.
2. Wilson TG, Wright JM. Non Hodgkin's lymphoma of the gingiva, Review of the literature. Report of a case. *J Periodontol* 1986;57:155-158.
3. Barber HD, Stewart JCB, Baxter WD. Non Hodgkin's lymphoma involving the inferior alveolar canal and mental foramen: report of a case. *J Oral Maxillofac Surg.* 1992;50:1334-1336.
4. Griffin TJ, Hurst PS, Swanson J. Non Hodgkin's Lymphoma: case involving four third molar extraction sites. *Oral Surg Oral Med Oral Pathol* 1988;65:671-674.
5. Slotweg P, Wittkampf ARM, Kluin PM, et al. Extra nodal Non Hodgkin's lymphoma of oral tissues. *J Oral Maxillofac Surg* 1985;13:85-92.
6. Maheshwari G, Baboo H, Shah N et al. Primary Non-Hodgkin's lymphoma of the oral tongue. *Turkish J Cancer* 2001; 31: 121-124.
7. Touboul E, Ghenim C, Chantelar JV, et al. Lymphomes nonhodgkinies de la tete et du cou, stades I et II : A propos de 35 cas. *Rev Stomatol Chir Maxillofac* 1985;86:300-309.
8. Haidar Z. A review of non-Hodgkin's lymphoma of the oral cavity 1950-1980. *J Oral Med* 1986;41:197-200.
9. Wolvius EB, Van der Valk P, Vander Wal JE, et al. Primary extranodal Non-Hodgkin's lymphoma of the oral cavity. An analysis of 34 cases. *Eur J Cancer & Oral Oncol* 1994;30:121-5.
10. Fukuda Y, Ishida T, Fujimoto M, et al. Malignant lymphoma of the oral cavity. Clinicopathological analysis of 20 cases. *J Oral Pathol* 1987;16:8-12.
11. Econopoulus T, Asprou N, Stathakis N, et al. Primary extra nodal Non Hodgkin's Lymphoma of the head and neck. *J Clin Oncology* 1992;49:484-488.
12. Shima N, Kobashi Y, Tsutsui K, et al. Extra nodal Non Hodgkin's Lymphoma of the head and neck. *Cancer* 1990;66:1190-1197.

