

Technical note: A simple and effective CO₂ delivery system for angiography using a blood bag

Mathew P Cherian, Pankaj Mehta, Prashant Gupta, Tejas M Kalyanpur, SR Jayesh, Rupa R
Department of Radiology, Kovai Medical Center and Hospital, Avinashi Road, Coimbatore, Tamil Nadu, India

Correspondence: Dr Mathew P Cherian, Department of Radiology, Kovai Medical Center and Hospital, Avinashi Road, Coimbatore- 641 014, Tamil Nadu, India. E-mail: dr.mathewcherian@gmail.com

Abstract

Several angiographic techniques have been developed to image the arterial system, the commonest using iodinated contrast media. Useful as they may be, they are not without disadvantages. One other modality is angiography using CO₂. Although CO₂ can be used as an alternative contrast medium, delivery systems are expensive to procure. We describe an indigenous and effective delivery system developed at our institute.

Key words: Carbon dioxide, CO₂, contrast, DSA

Introduction

Vascular diseases of the arterial system have long been a major cause of morbidity and mortality. Although several noninvasive techniques have evolved in recent times to image the arterial system, the gold standard remains the catheter digital subtraction angiography (DSA). Though the iodinated contrast media used today are relatively safe, they should, however, be used with caution in patients with compromised renal function and in diabetics. Patients with inadequate cardiac function are also poor candidates for angiography with iodinated contrast. Carbon dioxide (CO₂) has a role in this subset of patients as an effective and safe contrast agent.^[1]

Though gadolinium may be used as a substitute contrast agent^[1] in patients with chronic renal failure, there is a chance of developing a potentially fatal complication called nephrogenic systemic fibrosis.^[2,3]

CO₂ has received immense attention in recent times for its excellent safety profile. There is a paucity of studies, related to procedures using CO₂ in the Indian medical literature; a PubMed search in fact yielded no study from India regarding the use of CO₂ in vascular procedures; this is probably due to the fact that dedicated delivery systems for

CO₂ are expensive to procure and maintain. This problem has been solved by developing an indigenous injection system at our institute.

Materials and Methods

The system developed at our institute has been used for CO₂ angiograms for many years now. It consists of a standard blood bag (readily available) connected to a CO₂ cylinder [Figure 1]; this is done in order to avoid direct transmission of pressure from the cylinder to the vasculature under

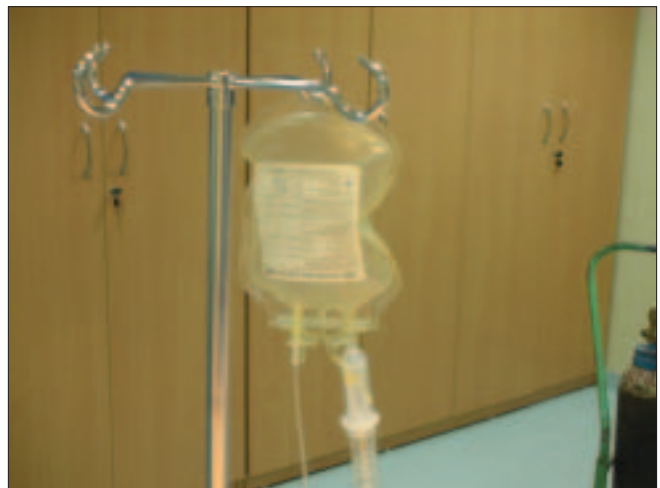

Figure 1: The blood bag inflated with CO₂ is depicted

DOI: 10.4103/0971-3026.54881

examination. The blood bag is then connected to a three-way stopcock [Figure 2], to which are connected a 50-cc plastic syringe and the angiographic catheter to be used [Figure 3].

The blood bag is first filled with CO₂ and the knob on the cylinder is closed. The bag now acts as a CO₂ reservoir. CO₂ is then allowed to freely flow for some time through the three ways in a basin containing sterile saline. This ensures that the tubings are free of air. The blood bag is intermittently filled to ensure that there is adequate CO₂ in this low pressure reservoir. With the CO₂ flowing through the ports of the three ways, a luer lock syringe is connected ensuring that the syringe is kept upside down. A 50 cc syringe is used if the injection has to be made in the renal or infra renal aorta. We would use a 20 cc syringe in the iliac and femoral arteries. Seventy five percent of the syringe is filled with CO₂ by gentle aspiration. The catheter is flushed with about 3 cc of CO₂ to prevent explosive delivery of the agent. According to Caridi *et al.*,^[1] this explosive delivery is a major cause of patient discomfort. Once the catheter has been

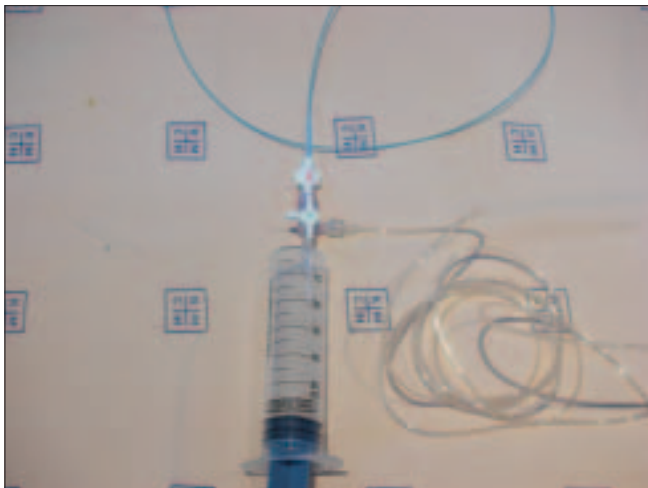


Figure 2: The syringe, three-way, and catheter assembly are shown

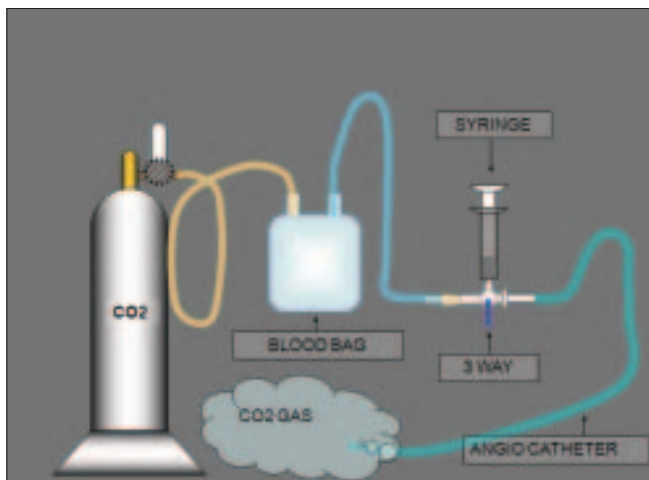


Figure 3: This schematic shows our delivery system

flushed, fifty percent of the CO₂ in the syringe is injected to adequately visualize the vessel. The CO₂ displaces blood in the vessel and provides 'negative contrast' [Figure 4]. The image quality can be enhanced by using 'stacking software'. Stacking software is used because the CO₂ column undergoes fragmentation as it travels distally; the software post-processes the images by stacking them one over the other, thus leading to an image in which the entire CO₂ column is visualized (minimum intensity stacking software). This injection system was employed in a prospective study between September 2005 and August 2007, wherein 44 patients underwent lower limb arterial angiograms with CO₂ and iodinated contrast (IC).

Results

Of the 44 cases evaluated with this system, we obtained diagnostic quality angiograms in 42 (95.5%) cases. The system was easy to use and required minimal manpower and expertise to maintain and setup. There was no system malfunction at any time and no complications were encountered.

Discussion

The commercially available delivery systems are not readily available in India and are difficult and expensive to procure. Hawkins *et al.*,^[4] developed a plastic bag system in 1995, which they later modified^[5] to include O-rings to reduce the possibility of a CO₂ leak; this system is commercially available as the Angioflush III. Our system has been indigenously developed and uses commonly available materials that are cheap to procure and maintain. The use

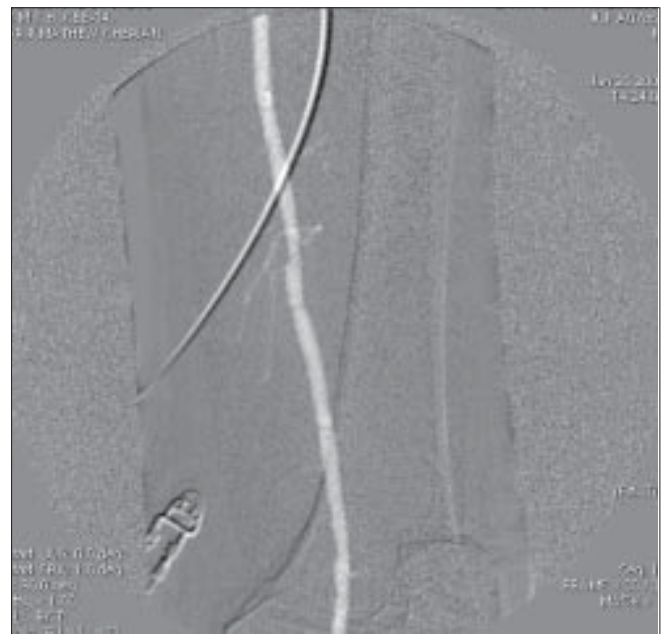

Figure 4: Angiogram with CO₂ using stacking software shows the superficial femoral artery (arrow)

of the blood bag as the reservoir avoids transmission of the high pressure of the gas in the cylinder to the vasculature; it also allows us to fill the syringe with a limited quantity of CO₂. We circumvented the problem of CO₂ leaks by using a three-way stopcock to which the catheter, syringe and the blood bag are attached. With proper operation of the stopcock, room air contamination can be completely avoided. This is an effective and cheap alternative to the commercially available CO₂ delivery systems.

References

1. Caridi JG, Hawkins IF Jr, Klioze SD, LeVein RF. Carbon dioxide digital subtraction angiography: The practical approach. *Tech Vasc Interv Radiol* 2001;4:57-65.
2. Thomsen HS, Morcos SK, Dawson P. Is there a causal relation between the administration of gadolinium based contrast media and the development of nephrogenic systemic fibrosis (NSF)? *Clin Radiol* 2006;61:905-6.
3. High WA, Ayers RA, Chandler J, Zito G, Cowper SE. Gadolinium is detectable within the tissue of patients with nephrogenic systemic fibrosis. *J Am Acad Dermatol* 2007;56:21-6.
4. Hawkins IF, Caridi JG, Kerns SR. Plastic bag delivery system for hand injection of carbon dioxide. *AJR Am J Roentgenol* 1995;165:1487-9.
5. Hawkins IF, Caridi JG, Klioze SD, Mladinich CR. Modified plastic bag system with O-ring fitting connection for carbon dioxide angiography. *AJR Am J Roentgenol* 2001;176:229-32.

Source of Support: Nil, **Conflict of Interest:** None declared.