

Chest

Anupam Lal, Ram Prakash Galwa, Mahesha Vankalakunti*, S Radhika*, N Khandelwal
Departments of Radiodiagnosis and *Cytology, Postgraduate Institute of Medical Education and Research (PGIMER), Chandigarh - 160 012, India

Correspondence: Dr. Anupam Lal, Department of Radiodiagnosis, PGIMER, Chandigarh – 160 012 (India), E-mail: dralal@rediffmail.com

A 60-year-old woman presented with a history of pain in the back of the chest, with occasional cough, for the last 3 months. She had a history of a radical mastectomy for carcinoma of the right breast 17 years ago. The routine blood counts were within normal limits.

The patient underwent a contrast-enhanced CT scan of

the chest [Figure 1A and B] and abdomen. A fine needle aspiration cytology (FNAC), using a 22-gauge spinal needle, was performed under CT guidance, which confirmed the diagnosis.

What is the diagnosis?

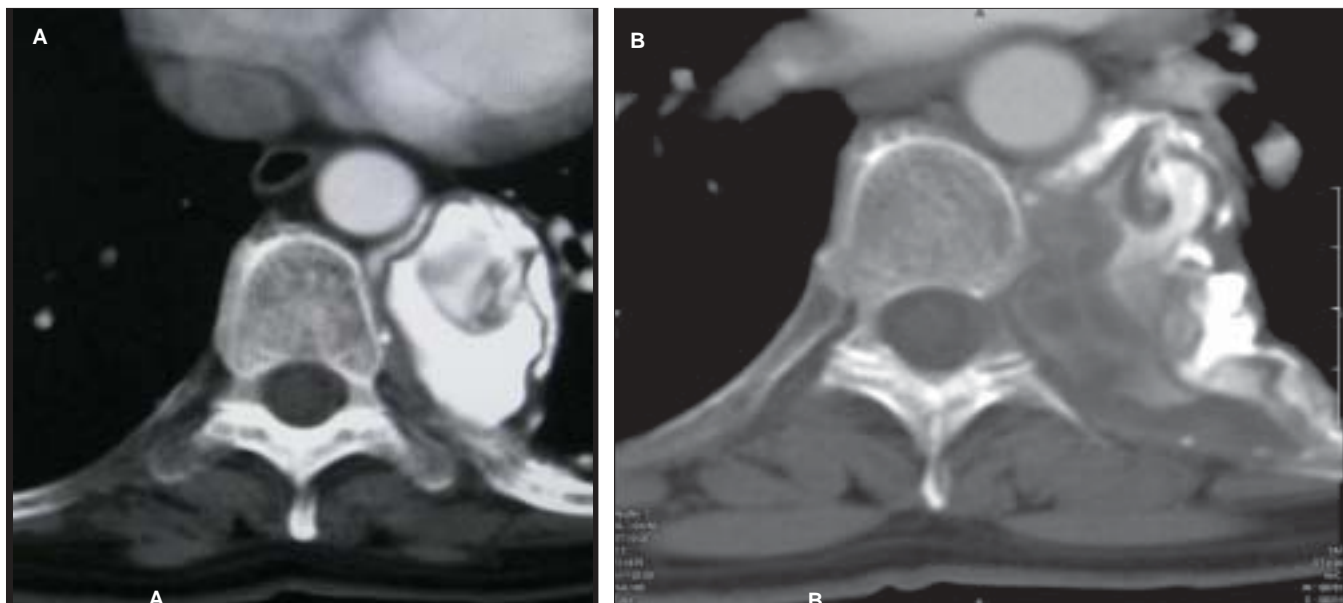


Figure 1 (A, B): Axial contrast-enhanced CT of the chest

There are two quizzes in this issue, this one and the next. Readers are requested to send in their answers to quiz@ijri.org, stating their name in full (first name and last name required, otherwise the answer will not be considered), quiz name and the answer. (e.g. Radiology Quiz: Abdomen, followed by the answer). Please do not give a differential diagnosis. The last date for submission of answers to this issue's quizzes, is January 15, 2008. The names of those who have answered correctly will be posted in the subsequent issue with the quiz answers. At the end of the year, those with the maximum correct answers will be given a special mention.