

# Case report: Lung lipoma

Ashish Atre, Swati Rajapure, John Joseph

Department of Radiodiagnosis, Grant Medical Foundation, Ruby Hall Clinic, Pune, India

**Correspondence:** Dr. Swati Rajapure, Department of Radiodiagnosis, Grant Medical Foundation, Ruby Hall Clinic, 40, Sassoon Road, Pune - 411 001, India. E-mail: swati.rajapure@rediffmail.com

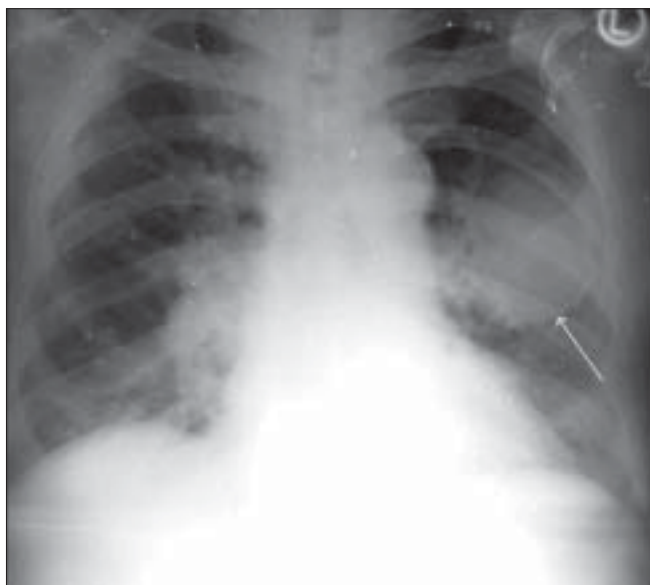
**Key words:** Lung lipoma..

## Case Report

A 66-year-old man suffering from an inguinal hernia had a routine, preoperative chest x-ray examination, which showed a well-defined, rounded pulmonary lesion in the left upper lobe, measuring approximately 6.0 cm in diameter [Figure 1].

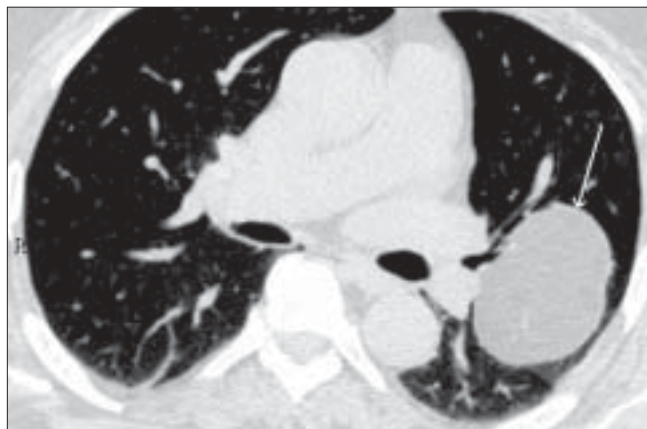
He had no symptoms. There was no relevant past medical history and clinical examination showed no abnormalities in the chest.

He underwent a CT scan of the chest, which demonstrated a well-defined, rounded, left upper lobe lesion, measuring 6.6 × 6.7 cm in the maximum transverse dimension [Figure 2]. The lesion had smooth outlines and was in close relation to the left apical segmental bronchus, minimally displacing it. It showed CT attenuation values of -100 to -110 HU,

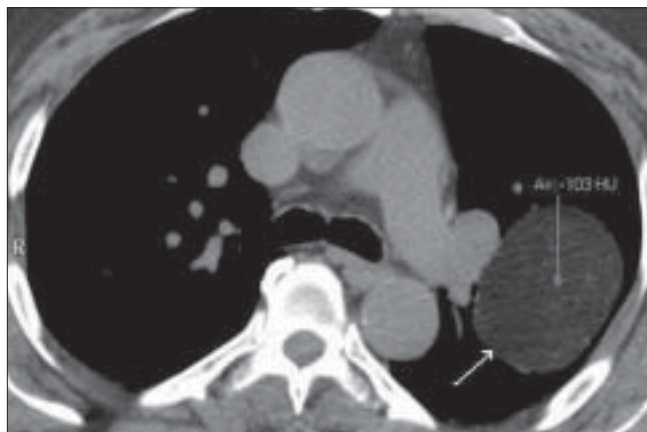


**Figure 1:** Chest radiograph, PA view, shows a well-defined, rounded pulmonary lesion in the left upper lobe (arrow)

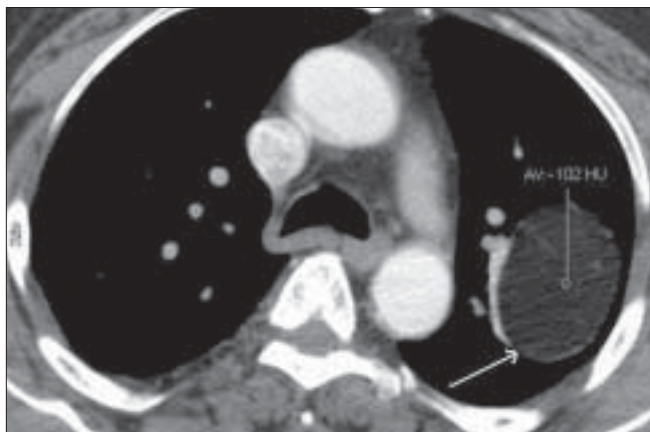indicating the presence of fat [Figure 3]. No other solid component, calcification, or any features of malignancy were seen in this lesion. Linear enhancing structures, representing either septae or vessels, were seen traversing it. There was no additional enhancement [Figure 4].



**Figure 2:** Plain axial CT scan shows a well-defined, rounded left upper lobe lesion (arrow) measuring 6.6 × 6.7 cm



**Figure 3:** Plain axial CT scan shows a well-defined, rounded left upper lobe lesion (arrow) with CT attenuation values of -100 to -110 HU, indicating the presence of fat



**Figure 4:** Contrast-enhanced CT scan does not reveal any enhancement in the lesion (arrow)

## Discussion

The presence of fat within the lesion is highly suggestive of a lipoma. Although lipomas are the commonest benign neoplasms of the soft tissues, their occurrence in the viscera, including the lungs,<sup>[1]</sup> is rare. In a review of 3,502 pulmonary tumors, 65 were benign and only 3 were lipomas.<sup>[1]</sup> In another review of 32 rare pulmonary tumors, Sekine et al. found 12 benign tumors, only 3 of which were lipomas.<sup>[2]</sup>

Intrapulmonary lipomas are divided into endobronchial and peripheral parenchymal lipomas. Endobronchial lipomas are more common, accounting for 80% of the cases,<sup>[3]</sup> and arise centrally from fatty tissue in the walls of the proximal lobar or segmental bronchi. The fatty tissue decreases with progressive bronchial branching and disappears when the bronchus is less than 1 mm in diameter,<sup>[1,4-7]</sup> which accounts for the rarity of peripheral lipomas. Over a 90-year period, as few as 8 cases of peripheral intrapulmonary lipomas have featured in the medical literature.<sup>[3,7-12]</sup> The first case was reported in 1911<sup>[8]</sup> and the most recent one in 2004.<sup>[13]</sup>

Peripheral lipomas are more frequent in men, with a peak incidence in the 5<sup>th</sup> and 6<sup>th</sup> decades and a predilection for the right side and the upper lobe of the lung.<sup>[3,7]</sup> The size varies from 1–7 cm. Parenchymal lipomas are asymptomatic because they are peripheral and are only found incidentally on routine radiographs. Endobronchial lipomas, on the other hand, may cause pulmonary changes due to atelectasis and secondary suppuration.<sup>[3]</sup> Imaging criteria for differentiation between endobronchial and parenchymal lipomas include their location as well as the presence of secondary obstructive changes in cases of endobronchial lipomas.

Benign, peripheral intrapulmonary lipomas usually present as solitary opacities on chest radiographs, indistinguishable on plain films from malignant neoplasms. CT scan is, however, diagnostic and shows a well-defined, homogenous lesion containing fat. This is confirmatory and no further diagnostic evaluation is required.

The previous seven reported patients underwent thoracotomy to establish the diagnosis, as malignancy could not be confidently excluded. In one patient, CT scan was diagnostic and a review of the previous images demonstrated a lesion that had persisted unchanged for 12 years, making malignancy unlikely. In our case, the patient was asymptomatic. The tumor was an incidental finding and showed CT attenuation values of –100 to –110 HU, indicating the presence of fat, with no features of malignancy. As a result, no intervention was performed.

The differential diagnosis of fat-containing peripheral lung masses includes fibrolipomatous hamartoma<sup>[14]</sup> and liposarcoma.<sup>[15,16]</sup> These tumors, however, contain other soft tissue elements and calcium, in addition to fat.<sup>[17]</sup>

## References

1. Politis J, Funahashi A, Gehlsen JA, DeCock D, Stengel BF, Choi H. Intrathoracic lipomas: Report of three cases and review of the literature with emphasis on endobronchial lipoma. *J Thorac Cardiovasc Surg* 1979;77:550-6.
2. Sekine I, Kodama T, Yokose T, Nishiwaki Y, Suzuki K, Goto K, et al. Rare pulmonary tumors: A review of 32 cases. *Oncology* 1998;55:431-4.
3. Plachta A, Hershey H. Lipoma of the lung: Review of the literature and report of a case. *Am Rev Respir Dis* 1962;86:912-6.
4. Watts AF, Clagett OT, MacDonald JR. Lipoma of the bronchus: Discussion of benign neoplasm and report of a case of endobronchial lipoma. *Thorac Surg* 1946;15:132-44.
5. Satub EW, Barker WL, Langston HT. Intrathoracic fatty tumors. *Dis Chest* 1965;47:308-13.
6. Bango A, Coulbi L, Molinos L, Fernandez R, Justo E, Martinez J. Endobronchial lipomas. *Respiration* 1993;60:297-301.
7. Hirata T, Reshad K, Itoi K, Muro K, Akiyama J. Lipomas of the peripheral lung: A case report and review of the literature. *Thorac Cardiovasc Surg* 1989;37:385-7.
8. Buchmann E. Zur Lehre der totalen Lungenatektase und der totalen Bronchiektase. *Frankfurt Zschr F Path* 1911;8:263-303.
9. Touroff AS, Seley GP. Lipoma of the bronchus and the lung. *Ann Surg* 1951;134:244-50.
10. Shapiro R, Carter MG. Peripheral lipoma of the lung: Report of a case. *Am Rev Tuberc* 1954;89:1042-4.
11. Jones L, Lucey JJ, Taylor AB. Intrapulmonary lipoma associated with multiple pulmonary hamartomas. *Br J Surg* 1973;60:75-8.
12. Zafirakopoulos P, Zorbas J, Creatsas G, Tosios J. Intrabronchial lipoma. *Int Surg* 1977;62:399-400.
13. Wood J, Henderson RG. Peripheral intrapulmonary lipoma: A rare lung neoplasm. *Br J Radiol* 2004;77:60-2.
14. Taniyama K, Sasaki N, Ymaguchi K, Motohiro K, Tahara E. Fibrolipomatous hamartoma of the lung: A case report and review of the literature. *Jpn J Clin Oncol* 1995;25:159-63.
15. Sawamura K, Hashimoto T, Nanjo S, Nakamura K, Lioka S, Mori T, et al. Primary liposarcoma of the lung: Report of a case. *J Surg Oncol* 1982;19:243-6.
16. Krygier G, Amado A, Salisbury S, Fernandez I, Maedo N, Vazquez T. Primary lung liposarcoma. *Lung Cancer* 1997;17:271-5.
17. Vassallo M, Rana Z, Allen S. A large transmural thoracic lipoma easily mistaken for pulmonary malignancy. *Br J Clin Pract* 1996;50:285-6.

**Source of Support:** Nil, **Conflict of Interest:** None declared.