

The role of combining MR cholangiopancreatography and T1W imaging in detecting common bile duct micro-stones

Yin Xindao, Wang Liping, Lu Lingquan, Zhang Taisheng, Wu Qianzhi, Gu Jianping

Department of Radiology, Nanjing First Hospital, Affiliated to Nanjing Medical University, Nanjing, Jiangsu Province 210006, P. R. China

Correspondence: Dr. Gu Jianping, 68 Chang Le Road, Department of Radiology, Nanjing First Hospital, (Nanjing Medical University Nanjing), Jiangsu Province P.R. China 210006. E-mail: yinxindao1965152@sohu.com

Abstract

Objective: To assess the role of adding T1W images to MR cholangiopancreatography (MRCP) in detecting common bile duct (CBD) micro-stones. **Subjects and Methods:** From January 2005 to December 2006, a total of 104 patients with CBD stones were preoperatively studied by routine MRI and MRCP. Micro-stones, measuring less than 5 mm, were proven at surgery or ERCP following the MRI scans, within one to five days in 56/104 patients. Routine MRI scans included RF-FAST axial T1W images (TR/TE 155 ms/3.4 ms) and EXPRESS axial T2W (15000 ms/81 ms) as well as coronal T2W (15000 ms/81 ms) images. Features of CBD micro-calculi on T1W and MRCP images and the sensitivities of T1W images and MRCP for the diagnosis of CBD micro-stones were analyzed. **Results:** Among these 56 patients, gallbladder stones coexisted with choledocholithiasis in 30 patients and 7 patients had a past history of cholecystectomy for gallstones. The signal intensities of CBD micro-calculi on T1W images were high, relative to the low signal intensity of the bile in 47 patients. Filling defects on MRCP images were shown in 33 patients. Both T1W images alone and a combination of MRCP with T1W images had a higher sensitivity in detecting CBD micro-calculi than MRCP alone. Statistical analysis showed significant differences between the combination of MRCP with T1W images and MRCP alone in the ability to detect micro-stones (Fisher's exact test, $P < 0.01$). **Conclusion:** For MRCP, adding a T1W sequence is helpful in increasing the sensitivity for diagnosing micro-calculi of the common bile ducts.

Key words: CBD calculi; micro-calculi; MRCP

Magnetic resonance cholangiopancreatography (MRCP) is a new, noninvasive imaging technique for visualizing the intra- and extrahepatic bile ducts and the pancreatic duct. Many studies have confirmed the value of MRCP in bile duct disease. The literature reports an accuracy of between 90% and 97% for MRCP in the diagnosis of common bile duct (CBD) calculi,^[1,2] but poor spatial resolution still limits its performance in the diagnosis of small CBD calculi. Some authors have reported that MRCP shows poor results for stones less than 3 mm in diameter.^[3,4]

MRCP typically employs heavily T2W images of the biliary tree and pancreatic duct, in which bile, pancreatic juices, or other stationary or slowly moving fluids appear hyperintense relative to the abdominal tissues. The use of T1W imaging in detecting bile duct system diseases, especially for the diagnosis of bile duct stones, has been neglected up to

now. Our study combines MRCP and T1W images for detecting CBD micro-stones in 56 cases; the findings being confirmed by surgery or an endoscopic retrograde cholangiopancreatography (ERCP) sphincterotomy probe. The aim of this study is to assess the value of adding T1W images to MRCP in diagnosing CBD micro-stones.

Materials and Methods

A series of 104 patients with choledocholithiasis was hospitalized and routine MRI and MRCP were performed preoperatively between January 2005 and December 2006. Of these, 56 patients had CBD stones measuring less than 5 mm (referred to as CBD micro-stones), which was confirmed by surgery or an ERCP sphincterotomy probe, following MRCP, within one to five days (mean 2.8 days). Of these, 21 patients were men and 35 were women, their

ages ranging from 15–85 years (mean age 57 ± 16 years). Clinical findings included jaundice in 48 patients, abdominal pain or discomfort in 36, and abnormal liver function test results in 43.

Routine MRI and MRCP were performed on a 1.5-T scanner (Picker Eclipse; Marconi Medical System) using the VIA 2.0E software (Marconi). A body coil was used in all patients. Routine MRI included an RF-Fourier acquired steady-state technique (RF-FAST) axial T1W (TR/TE155/3.4) sequence and an extended phase-conjugate symmetric rapid spin-echo T2W (15000/81) sequence (EXPRESS) in the axial and coronal planes. Breath-hold T2W EXPRESS fat-suppressed imaging was performed for MRCP, using the following parameters: TR/effective TE, 18,000/80; matrix, 256×256 ; acquisitions, 1; scanning time, 16 s. EXPRESS is a rapid spin-echo sequence and a single-shot acquisition technique that collects all the data in one TR period in a single 16 s breath-hold and uses half-Fourier acquisition. Axial images were acquired first with 6 mm slice thickness and 1 mm gap. Five 45 mm sections were then acquired in the oblique coronal planes along the course of the bile duct (as seen on the axial images), using a field of view of 36 cm. The scanning time for each thick section was 8 s. Next, 4 mm thick coronal images without a gap were obtained. Three-dimensional images were generated from the coronal source images using maximum intensity projection (MIP) algorithms and multiplanar reformatting techniques. The total scanning time in all patients was about 15 min.

Routine MRI and MRCP images were analyzed by two senior doctors who have worked in MRI for more than 5 years; they were not aware of the results of surgery or ERCP. If there was a controversy about the diagnosis, a consensus decision was reached. The criterion for judging bile duct dilation was based on a report written by Kim et al., in which dilatation of the biliary tree was defined as a CBD with a maximum diameter of more than 7 mm in patients younger than 60 years and without a history of cholecystectomy, 9 mm in patients who were 60 years of age or older, and 10 mm in patients with a prior cholecystectomy.^[5]

SPSS VIA 13.0 software was used for statistical analysis. All data were expressed as mean \pm SD and results between groups were compared with the Fisher's exact test; $P < 0.05$ was taken to be indicative of a statistically significant difference.

Results

A total 56 patients with CBD micro-stones were found. The sizes of the calculi were between 1 and 5 mm, averaging 3 ± 1 mm. Gallstones coexisted with choledocholithiasis in 30 patients and seven patients had a past history of cholecystectomy for gallstones. On MRCP, mild bile duct dilation was found in 31 patients and moderate to high

dilation in 7. Relative hypointense filling-defects were seen in the CBD on MRCP in 33 patients [Figures 1A and 2A]. Twenty-three patients showed normal findings [Figures 3A and 4A]. On T1W imaging, the signal intensities of CBD micro-calculi were high, relative to the low signal intensity of bile in 47 of 56 patients. The CBD micro-calculi showed spot hyperintensities in 15 patients [Figures 3B and 4B] and small nodular hyperintensities in 20 [Figure 1B], with sand-like hyperintensities in 12 [Figure 2B]. The residual stones were invisible or isointense.

Among these 56 patients, CBD micro-calculi were diagnosed in 83.9% (47/56) on T1W images as against 58.9% (33/56) on MRCP alone. The sensitivity for detecting micro-stones was as high as 91.9% (51/56) when T1W imaging was added to MRCP. A combination of MRCP and T1W imaging for the diagnosis of micro-calculi in the CBD was more sensitive than MRCP alone, with a statistically significant difference ($P < 0.01$) (Table 1).

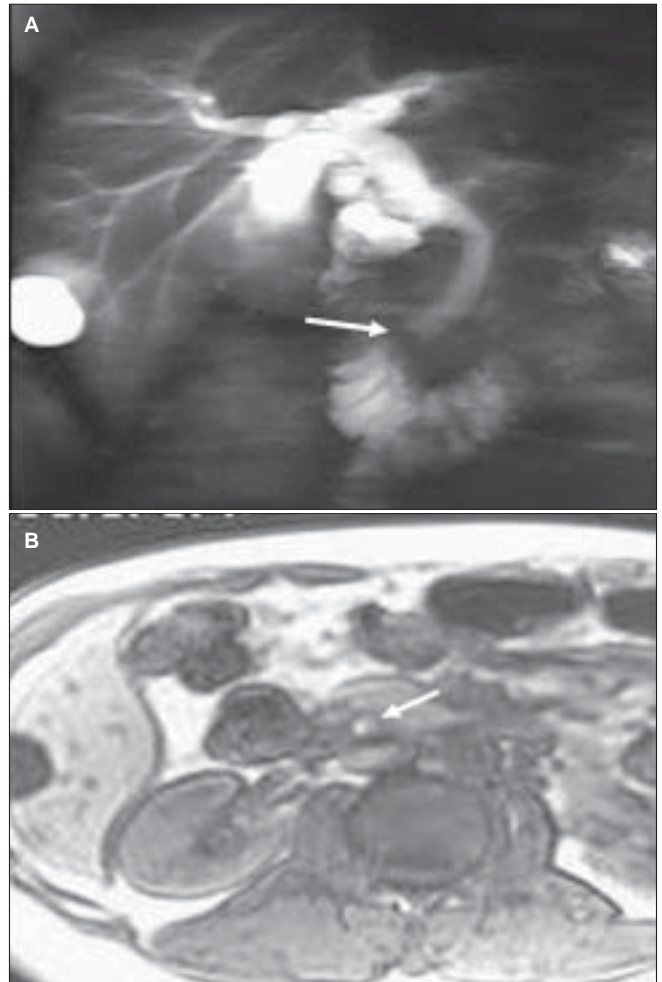


Figure 1 (A, B): MRCP (A) in a 49-year-old man with right upper abdomen pain and jaundice shows the signal void of a micro-stone in the distal end of the dilated CBD duct (arrow). The T1W image (B) in the same patient shows a small hyperintense nodule (arrow)

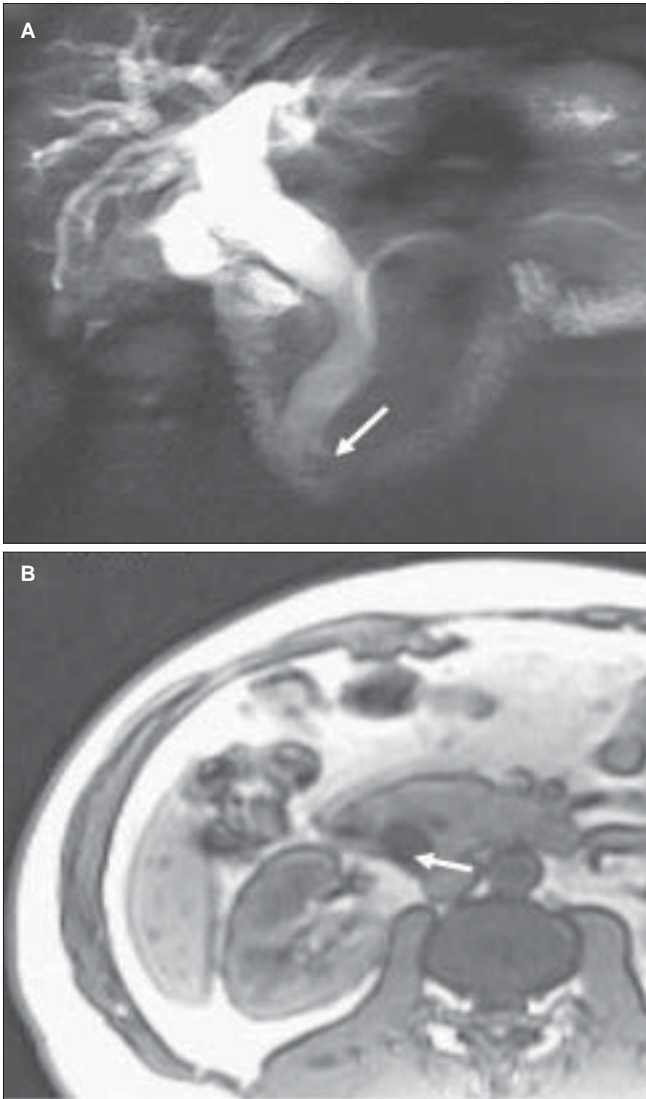


Figure 2 (A, B): MRCP (A) in a 49-year-old man with jaundice after cholecystectomy for gallstones shows filling defects at the distal end of the dilated CBD. The T1W image (B) in the same patient shows sand-like hyperintense micro-calculi

Table 1: MRCP with and without TIW in detecting CBD micro-stones

CBD Micro-Stones (56 cases)	
Imaging Type	Positive/ Negative
MRCP	33/ 23
T1W images	47/ 9
Combined*	51/ 5

*includes MRCP and T1W images. Fisher's exact test: T1W images or combined shows statistically significant differences compared to single MRCP, with *P* values of 0.006 and 0.000, respectively.

Discussion

Biliary lithiasis is the most common biliary tree disease, and it is reported that at the time of cholecystectomy for symptomatic cholelithiasis, 8–15% of patients less than

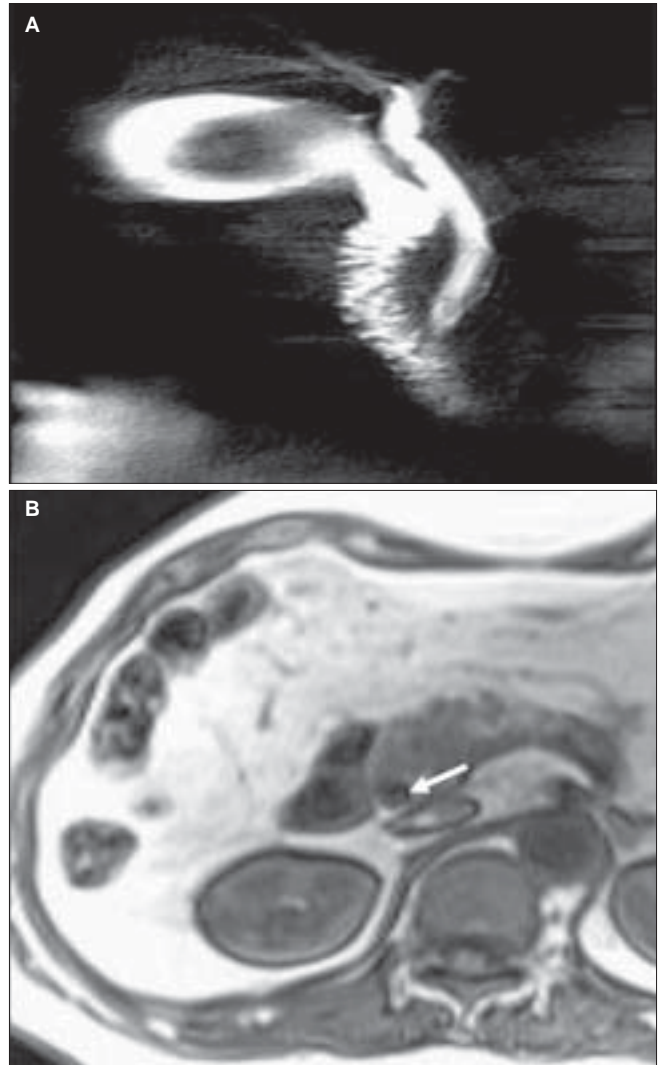


Figure 3 (A, B): MRCP (A) in a 67-year-old woman with pain below the xiphoid process shows a filling defect in the gallbladder, but a normal CBD. The T1W image (B) shows a spot hyperintensity at the level of the pancreatic head (arrow)

60 years and 15–60% of patients over 60 years have CBD stones.^[6] ERCP has long been considered the gold standard for diagnosing bile duct stones. However, diagnostic ERCP may be associated with significant morbidity and mortality^[7] and, moreover, has a technical failure rate of approximately 4%.^[8] The diagnostic accuracy of MRCP is now comparable to that of ERCP in the evaluation of choledocholithiasis. MRCP has, therefore, gained acceptance as an alternative to ERCP for imaging the biliary tract and the pancreatic duct. ERCP is now mainly performed to withdraw calculi and diagnose difficult biliary and pancreatic tract disease.

On MRCP, the diagnosis of bile duct stones is based on the visualization of round, ovoid, or irregularly-shaped signal voids within the hyperintense bile duct lumen. MRCP is negative mainly in small CBD stones, especially those less than 5 mm.^[3,4,9–11] Our investigation shows only a 58.9% sensitivity and 41.1% specificity for detecting micro-stones

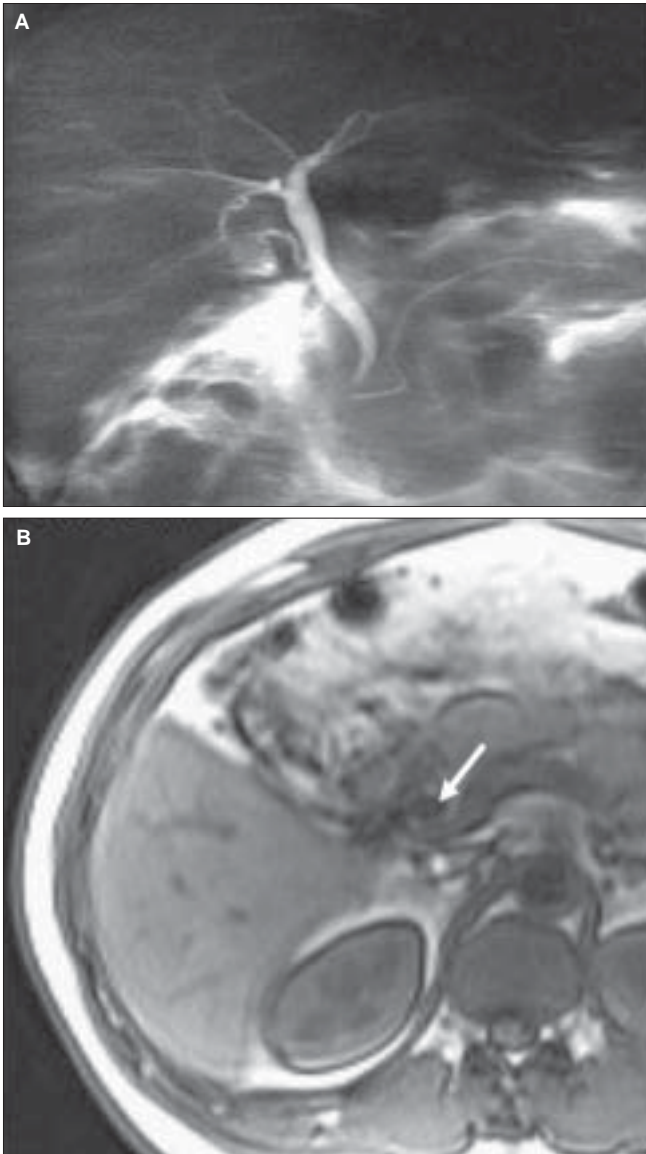


Figure 4 (A, B): MRCP (A) in a 39-year-old man with right upper abdomen pain and fever shows gallstones, but a normal CBD. The T1W image (B) in the same patient shows two spot hyperintensities (arrow) in the CBD at the level of the pancreatic head

in the CBD. This may be due to poor spatial resolution or due to the presence of pigment, with a large fluid component, or due to the stones being poorly outlined by hyperintense bile. A recent report suggests that adding T1W imaging to MRCP increases its sensitivity for diagnosing CBD stones. The sensitivity of this combination of MRCP and a T1W sequence was significantly better than that of MRCP alone for detecting intrahepatic stones whose signal intensities on the T1W axial images were high, relative to the adjacent bile or liver parenchyma, in 134 of 158 stones (84.8%).^[12] In our study, CBD micro-calculi were invisible on MRCP alone in 23/56 (41.9%) patients, but on T1W imaging, micro-stones could be delineated in 47/56 (83.9%) patients. Only in nine patients were the micro-calculi not visible. The sensitivity for detecting micro-stones increased to 91.9%

(51/56) when a T1W sequence was added to MRCP. Our results show that it is better to combine MRCP and a T1W sequence for diagnosing CBD micro-stones rather than using MRCP alone.

CBD stones are classified into two types: primary and secondary. Secondary CBD stones are due to gallstones passing into the common duct. Previous reports show that gallstones were complicated by biliary tract stones in 15–20% of patients.^[13,14] Our results show that this may occur in up to 53.6% (30/56) of patients. It may be hypothesized that the smaller the CBD stone, the more it is likely to be of gall bladder origin. In some cases, the stones form in the common duct itself (primary stones); these are mostly pigment calculi and are seen in Chinese and Asian populations. The treatment of primary and secondary stones differs. Various clinical, biochemical, and investigative procedures may be used to identify ductal calculi.^[15] Biochemical tests have poor sensitivity and specificity. USG is an easily available, noninvasive, and a low-cost investigation, which does not entail exposure to ionizing radiation. However, it is highly operator dependent,^[6] can fail to detect stones in two out of three patients, and USG imaging is subject to interference from bowel gas. It is particularly poor in detecting smaller, partially obstructing calculi. The distal CBD may not routinely be examined if there is no extrahepatic biliary dilatation, and this may further diminish the sensitivity.

To the best of our knowledge, a combination of MRCP and T1W imaging can increase the sensitivity for diagnosing CBD micro-stones and help in improving the clinical decision-making process.

References

1. Varghese JC, Liddell RP, Farrell MA, Murray FE, Osborne DH, Lee MJ. Diagnostic accuracy of magnetic resonance cholangiopancreatography and ultrasound compared with direct cholangiography in the detection of choledocholithiasis. *Clin Radiol* 2000;55:25-35.
2. Liu TH, Consorti ET, Kawashima A, Ernst RD, Black CT, Greger PH, *et al.* The efficacy of magnetic resonance cholangiography for the evaluation of patients with suspected choledocholithiasis before laparoscopic cholecystectomy. *Am J Surg* 1999;178:480-4.
3. Chan YL, Chan AC, Lam WW, Lee DW, Chung SS, Sung JJ, *et al.* Choledocholithiasis: Comparison of MR cholangiography and endoscopic retrograde cholangiography. *Radiology* 1996;200:85-9.
4. Scheiman JM, Carlos RC, Barnett JL, Elta GH, Nostrant TT, Chey WD, *et al.* Can endoscopic ultrasound or magnetic resonance cholangiopancreatography replace ERCP in patients with suspected biliary disease? A prospective trial and cost analysis. *Am J Gastroenterol* 2001;96:2900-4.
5. Kim MJ, Mitchell DG, Ito K, Outwater EK. Biliary dilation: differentiation of benign from malignant causes-value of adding conventional MR imaging to MR cholangiopancreatography. *Radiology* 2000;214:173-81.
6. Diagnosis and treatment of common bile duct stones (CBDs). Results of a consensus development conference. Scientific

Committee of the European Association for Endoscopic Surgery (E.A.E.S.). *Surg Endosc* 1998;12:856-64.

7. Misra SP, Dwivedi M. Complications of endoscopic retrograde cholangiopancreatography and endoscopic sphincterotomy: Diagnosis, management and prevention. *Nat Med J India* 2002;15:27-31.
8. Bilbao MK, Dotter CT, Lee TG, Katon RM. Complications of endoscopic retrograde cholangiopancreatography (ERCP): A study of 10,000 cases. *Gastroenterology* 1976;70:314-20.
9. Laokpessi A, Bouillet P, Sautereau D, Cessot F, Desport JC, Le Sidaner A, *et al.* Value of magnetic resonance cholangiography in the preoperative diagnosis of common bile duct stones. *Am J Gastroenterol* 2001;96:2354-9.
10. Jendresen MB, Thorboll JE, Adamsen S, Nielsen H, Grønvald S, Hart-Hansen O. Preoperative routine magnetic resonance cholangiopancreatography before laparoscopic cholecystectomy: A prospective study. *Eur J Surg* 2002;168:690-4.
11. Kondo S, Isayama H, Akahane M, Toda N, Sasahira N, Nakai Y, *et al.* Detection of common bile duct stones: Comparison between endoscopic ultrasonography, magnetic resonance cholangiography and helical-computed-tomographic cholangiography. *Eur J Radiol* 2005;54:271-5.
12. Kim YK, Kim CS, Lee JM, Ko SW, Chung GH, Lee SO, *et al.* Value of adding T1-weighted image to MR cholangiopancreatography for detecting intrahepatic biliary stones. *AJR Am J Roentgenol* 2006;187:W267-74.
13. Duensing RA, Williams RA, Collins JC, Wilson SE. Managing choledocholithiasis in the laparoscopic era. *Am J Surg* 1995;170:619-21.
14. Widdison AL, Longstaff AJ, Armstrong CP. Combined laparoscopic and endoscopic treatment of gallstones and bile duct stones: A prospective study. *Br J Surg* 1994;81:595-7.
15. Menezes N, Marson LP, debeaux AC, Muir IM, Auld CD. Prospective analysis of a scoring system to predict choledocholithiasis. *Br J Surg* 2000;87:1176-81.

Source of Support: Nil, **Conflict of Interest:** None declared.