

Radiological quiz - Obstetrics

H Satishchandra, Namitha

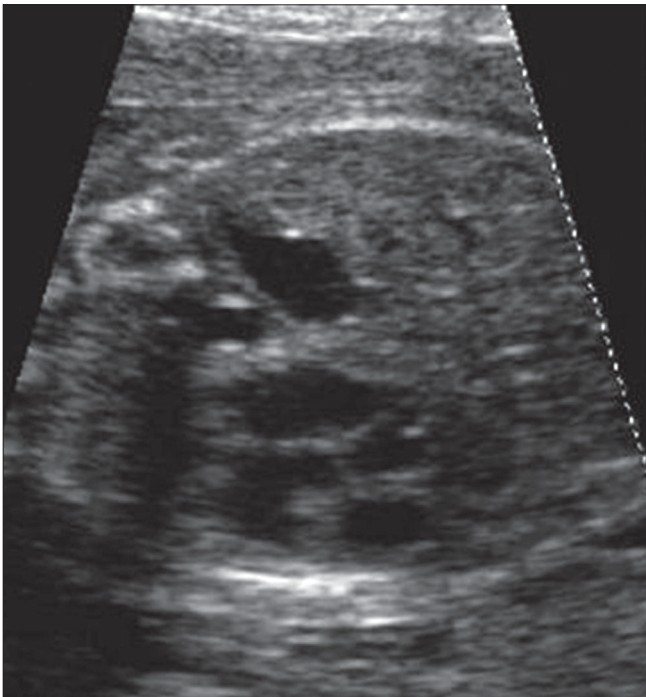
Department of Radiodiagnosis, Bowring and Lady Curzon Hospitals, Bangalore Medical College and Research Institute, Bangalore, India

Correspondence: Dr. Namitha, 77/4, II Floor, Puttanna Road, Basavanagudi, Bangalore - 560 004, India. E-mail: namitha_holla@yahoo.co.in

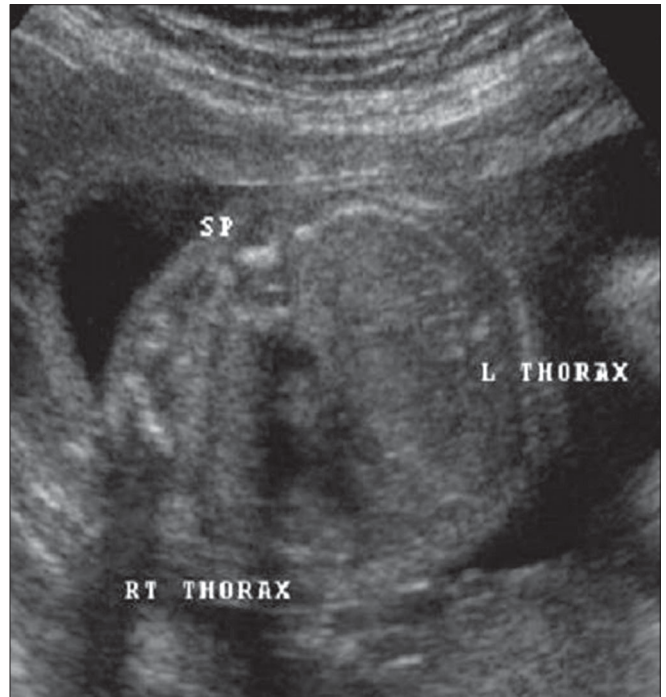A 27-years-old woman, G₃P₂L₂, came for a routine second trimester anomaly scan. Gestational age was determined to be 24 weeks. USG images of the fetal thorax [Figures 1 and

2] are shown. What is the complete antenatal diagnosis?

What is your diagnosis?



Figures 1: Transverse USG of the fetal thorax - four chamber cardiac view.



Figures 2: Transverse USG of the fetal thorax - four chamber cardiac view captured five minutes later.