

# Ultrasonography of shoulder [rotator cuff]

Nitin G Chaubal

Thane Ultrasound Centre, Thane, Jaslok Hospital and Research Centre, Mumbai, India.

**Correspondence:** Dr. Nitin G Chaubal, Thane Ultrasound Centre, Shanti Niwas, Dr. Moose Road, Talaopali, Thane (W) - 400 601, India  
E-mail: chaubal@bom3.vsnl.net.in

The commonest musculoskeletal (MSK) USG examination request is for the shoulder joint. It can be very easily assessed because of anatomical reasons. Improvement in the resolution of USG machines, refined techniques, and better understanding of the pathology have contributed to high accuracy in the diagnosis of rotator cuff pathology.<sup>[1]</sup> With an experienced sonologist and good equipment, accuracy of USG equals that of MRI for full-thickness tears and is slightly better than MRI for partial-thickness tears.<sup>[2]</sup> USG's real-time capability is a big advantage; dynamic studies can be easily done. USG is preferred over MRI in several institutes.

## Clinical background

Patients with rotator cuff problems present with a variety of symptoms including a painful arc, night pains, weakness, and decreased range of motion. Though there are various causes for shoulder pain, including adhesive capsulitis, cervical nerve root compression and acute joint inflammation, 60% of shoulder abnormalities have been attributed to rotator cuff disease, which is the most common cause of shoulder pain and dysfunction in patients above 40 years of age.<sup>[3,4]</sup> A degenerated rotator cuff is seen in 60% of cadavers above 40 years and 50–70% of individuals above the age of 65 may have a rotator cuff tear.<sup>[5]</sup>

Cuff fiber failure is a degenerative process, starting as a tendinopathy and progressing through a partial-thickness tear to a full-thickness tear. This generally involves the supraspinatus tendon first and then, gradually, the other tendons.<sup>[6]</sup>

Physical findings include muscle deformity, anterolateral shoulder tenderness, muscle atrophy, weakness, and decreased range of motion.

## Gross anatomy and biomechanics

The shoulder joint is a shallow ball-and-socket joint, which permits a great range of movement. Compared to other ball-and-socket joints, it is inherently unstable and depends on ligament and tendon support, as opposed to

just bony support.

The power muscles around the shoulder are the deltoid, pectoralis major, and trapezius. The deltoid is the primary abductor of the arm. It is attached to the scapular spinous process, acromion, and the distal clavicle. Its main vector of action is vertical. When contracted, the deltoid tends to pull the humerus vertically rather than outwards. The ligaments and tendons of the rotator cuff provide 'antagonist' action to the deltoid, so as to hold the humeral head against the glenoid.

There are 3 levels of support:

1. The rotator cuff
2. Biceps tendon
3. Capsular ligaments

This enables the humeral head to pivot at the correct level and to abduct freely.<sup>[7]</sup>

The rotator cuff is composed of four muscles and their corresponding tendons: (1) subscapularis, (2) supraspinatus, (3) infraspinatus, and (4) teres minor. These four muscles primarily provide dynamic stability to the intrinsically unstable genohumeral joint and also assist in internal and external rotation and in abduction of the shoulder. The subscapularis is the anterior-most component and is a large triangular, multipennate muscle arising from the subscapular fossa. Fibers of this tendon extend across the glenohumeral joint, converge into a broad, short tendon that inserts on the lesser tuberosity. The supraspinatus is the superior-most muscle. Arising from the supraspinatus fossa, it passes under the acromion, crosses over the humeral head, and inserts as a tendon into the anterior aspect of the greater tuberosity. The infraspinatus muscle originates from the infraspinatus fossa; its tendon extends laterally to insert on the greater tuberosity, posterior and inferior to the supraspinatus tendon. The teres minor is a narrow muscle that arises from a narrow strip on the lateral border of the scapula and inserts just posterior and inferior to the infraspinatus tendon. These three tendons of the rotator cuff together insert on the greater tuberosity of the humerus.<sup>[8]</sup> The tendon of the long head of the biceps brachii arises

from the posterosuperior aspect of the glenoid labrum. It is covered in a synovial sheath. It crosses the shoulder joint obliquely and arches over the head of the humerus and descends into the bicipital groove. Tendinous slips from the subscapularis and supraspinatus tendons form a sheath around the biceps tendon and anchor it in the proximal end of the groove. The coracohumeral ligament originates from the lateral aspect of the base of the coracoid process and inserts into the rotator cuff at the interval between the supraspinatus and subscapularis tendons.

The deltoid is a thick, triangular muscle. It originates from the anterosuperior aspect of the clavicle, superolateral aspect of the acromion, and inferior aspect of the scapular spine. Its tendon inserts in the lateral aspect of the proximal humeral shaft. The subacromial-subdeltoid bursa lies between the rotator cuff and the deltoid muscle. It normally does not communicate with the shoulder joint.<sup>[1]</sup>

The coracoacromial arch is the superior limit of the shoulder; it consists of the acromion process, coracoacromial ligament, coracoid process, acromioclavicular joint, and subdeltoid bursa. The rotator cuff must pass smoothly under this area, the subacromial outlet.<sup>[7]</sup>

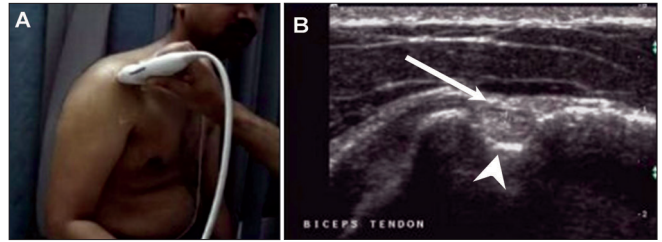
### Scanning technique

Typically, a linear high-frequency probe is used; a broadband probe like L5-12 is ideal. The best way to examine the shoulder joint is to sit on a high revolving chair, with the patient sitting opposite the examiner on a similar chair. The basic principles of MSK USG, i.e., examining each structure in 2 planes and maintaining perpendicularity to tendon fibers, should be followed. It is necessary to follow the curve of the bone, and useful landmarks include the acromion process, biceps tendon, and the labrum.<sup>[9-11]</sup>

Personally, I prefer to follow the following sequence when examining the shoulder joint: biceps tendon, subscapularis, supraspinatus (including test for impingement), infraspinatus, teres minor, posterior glenoid labrum and glenohumeral space, coraco-acromial ligament and, finally, the acromioclavicular joint.

### Biceps tendon

Palpate the bicipital groove with your left thumb and place the transducer perpendicularly at the exact point. The bicipital groove is identified as a concave bright area on the bony surface of the humerus. The tendon of the long head of the biceps is visualized as a hyperechoic oval structure within the bicipital groove. The biceps tendon is traced superiorly in its intraarticular position and inferiorly up to the musculotendinous junction in both transverse and longitudinal planes. Even a small amount of fluid may indicate a rotator cuff injury [Figure 1].



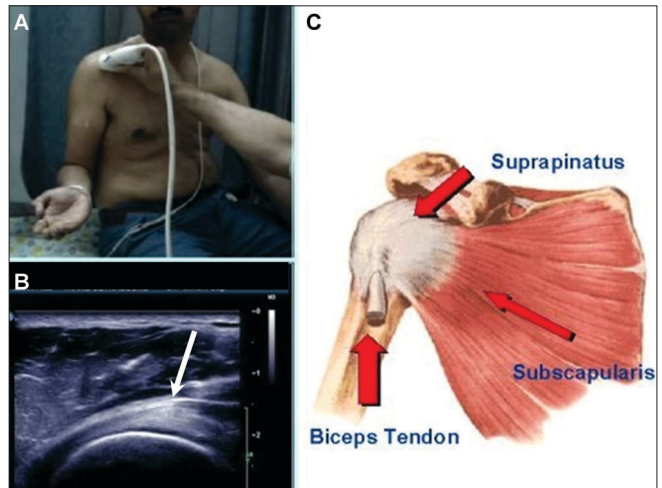
**Figure 1 (A, B):** Biceps tendon. The photograph (A) shows the position of the transducer for a transverse scan of the bicipital tendon. The tendon (arrow) is well visualized in the groove (arrowhead) on the transverse USG scan (B).

### Subscapularis tendon

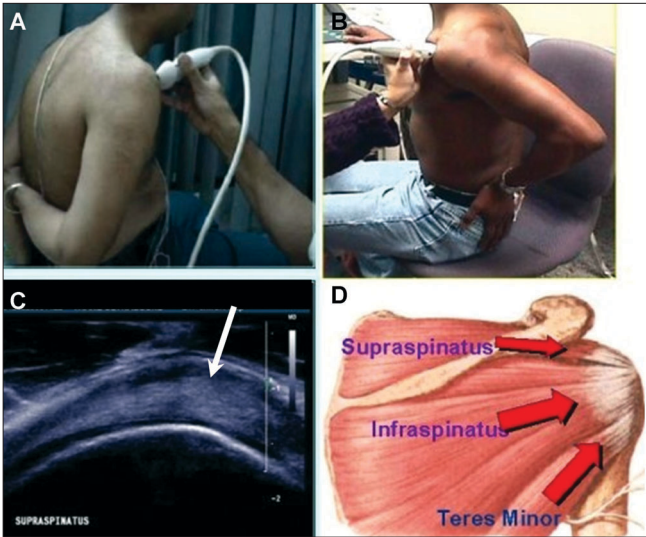
The subscapularis tendon is best examined while performing passive external rotation and internal rotation. In external rotation the tendon becomes more prominent, as it is medial to the biceps tendon [Figure 2A]. It must be examined in two planes. Injuries of the subscapularis are rare, except in the event of direct trauma [Figure 2].

### Supraspinatus tendon

Scanning of the supraspinatus tendon is best done by keeping the arm in extension and internal rotation [12]. Asking the patient to hold the opposite upper arm from behind [Figure 3A] or positioning the arm on the hip [Figure 3B] is the best way to evaluate the supraspinatus tendon, which is the most important tendon. Patients with rotator cuff pathology are unable to position themselves properly. The tendon is scanned perpendicular to its axis (transverse scan) by moving the transducer laterally and posteriorly. It is visualized as a band of medium-level echoes deep to the subdeltoid bursa and superficial to the bright echoes originating from the bony surface of the greater



**Figure 2 (A-C):** Subscapularis tendon. The photograph (A) shows the position of the transducer for a longitudinal scan of the subscapularis tendon. The tendon (arrow) is well visualized on the B-mode image (B). An anatomical diagram is shown (C), the thin arrow showing the plane of orientation of the transducer for a longitudinal view of the tendon.

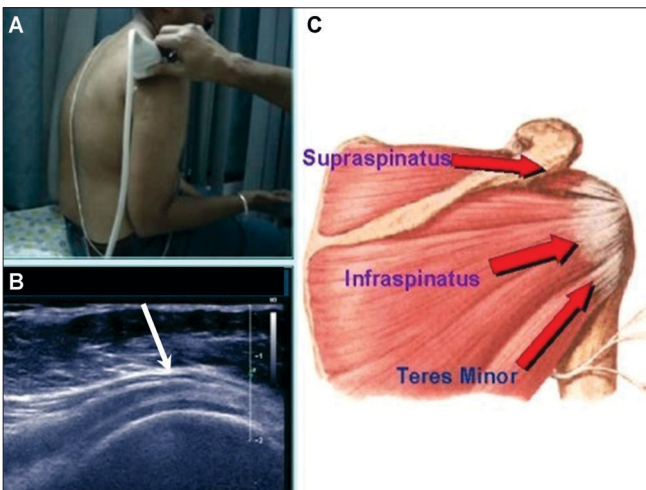


**Figure 3 (A-D):** Supraspinatus tendon. The photograph (A) shows the arm of the patient being held by the opposite arm behind the back, whereas (B) shows the position of the hand on the hip. The supraspinatus tendon (arrow) is well seen on the B-mode image (C), in its longitudinal plane. (D) shows the anatomy of the rotator cuff, the arrows showing the longitudinal planes of the tendons.

tuberosity [Figure 3C]. It is important to demonstrate the critical zone, the area most susceptible to injury, which is the portion of the tendon that is situated approximately 1 cm posterolateral to the biceps tendon; it is a common site for an artifact.

**Infraspinatus tendon**

The infraspinatus tendon is visualized by positioning the probe posteriorly. It appears as a beak-shaped, soft tissue structure that attaches to the posterior aspect of the greater tuberosity. Passive internal and external rotation may be useful in evaluating this tendon.<sup>[12]</sup> A portion of the



**Figure 4 (A-C):** Infraspinatus tendon. The photograph (A) shows the plane of examination of the infraspinatus and the corresponding image (B) along the longitudinal axis of the tendon. An anatomical diagram is shown (C), the thin arrow showing the plane of orientation of the transducer for a longitudinal view of the tendon.

posterior glenoid labrum is seen as a hyperechoic, triangular structure. The articular cartilage of the humeral head is seen as a thin, hypoechoic layer, superficial to the high-level echoes originating from the bony surface [Figure 4].

**Teres minor tendon**

The teres minor tendon is seen as a trapezoid structure. It can be seen by moving the transducer distally on the humerus. It can be differentiated from the infraspinatus by its oblique internal echoes. A tear of this tendon is very rare, but mild intraarticular fluid may be best visualized at this level.<sup>[13]</sup> Visualization of the teres minor ensures that the entire infraspinatus has been scanned.

**Acromioclavicular joint**

The acromioclavicular joint is best evaluated by keeping the probe perpendicularly on the joint.

**Test for Impingement**

The test for impingement is done by asking the patient to elevate his hand (as in the combing action). A smooth gliding of the supraspinatus tendon below the subacromial outlet rules out impingement [Figure 5].

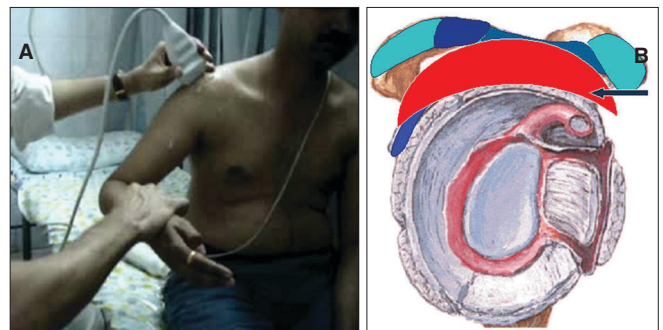
**Criteria for diagnosis of rotator cuff tear**

Over the years, major and minor criteria for rotator cuff tear have been described.

While evaluating the rotator cuff, one must always examine the integrity, thickness, and echogenicity of the cuff and look out for calcification. The criteria suggested by Middleton<sup>[14-16]</sup> are easy to follow and report. The size of the tear, its orientation, and its location relative to the biceps tendon have to be reported.

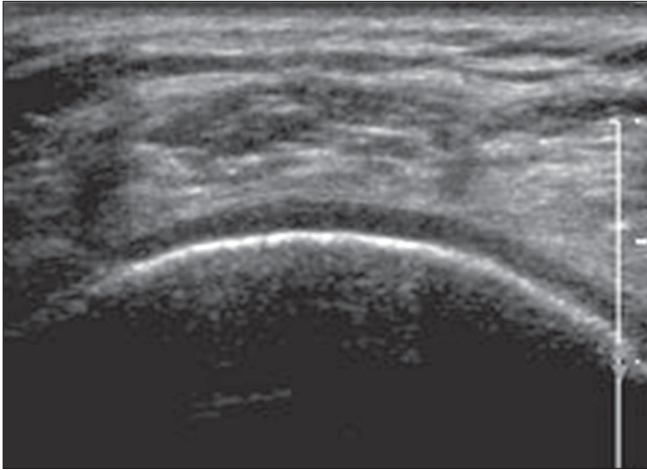
**Major criteria**

1. Nonvisualization of the cuff [Figure 6]: A total nonvisualization of the rotator cuff occurs often, suggesting a complete tear. This can be easily missed by



**Figure 5 (A, B):** Test for impingement. The photograph (A) shows the method of performing the impingement test, which assesses the ability of the supraspinatus tendon (B) to pass smoothly under the subacromial outlet (red), coracoid and acromion processes (light blue) coracoacromial ligament (dark blue).

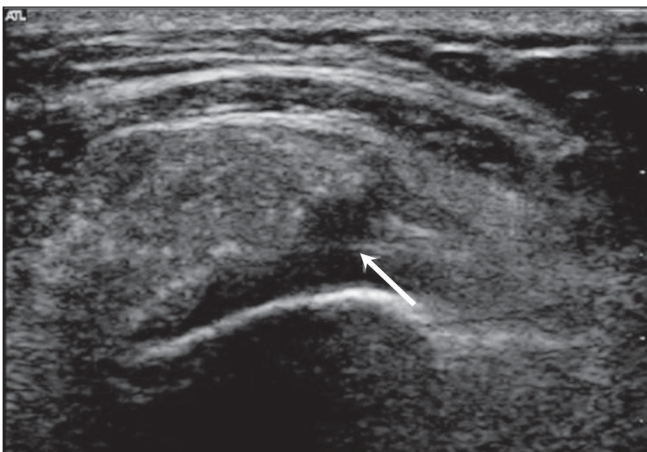




**Figure 6:** Full-thickness supraspinatus tear. Longitudinal scan of the supraspinatus shows complete absence of the tendon, the space filled by the deltoid muscle.

a novice since the entire supraspinatus tendon is missing and the deltoid with the subdeltoid bursa then rests on the head of the humerus. The best way to confirm this is by comparing with the other side. An important indirect clue in this situation is the loss of the normal convexity of the deltoid and bursa, with dipping of the same (with concavity) in the empty space. This is the most important indirect sign. Bursal thickness, and fluid in the subdeltoid bursa and along the biceps, are very commonly associated. The hyaline cartilage on the humeral head stands out. This is often referred to as the 'naked tuberosity' or 'double arc' sign.

2. Focal nonvisualization: Focal nonvisualization of the tendon is relatively easy to diagnose, as the remaining tendon is seen adjacent to it. Within this gap, the subdeltoid bursa can also dip. Confirmation in two planes is important. Most rotator cuff pathologies occur in the terminal 1 cm of the tendon, which is the critical zone.
3. Discontinuity [Figure 7]: Discontinuity of fibers may be



**Figure 7:** Full-thickness supraspinatus tear. Longitudinal scan of the supraspinatus tendon shows an obvious focal area of discontinuity (arrow), suggesting a tear.

seen, the gap filled with fluid or reactive tissue. A stress test, by positioning the elbow with the arm internally rotated, is the best way to check for discontinuity of the fibers. It is also apparent by the 'compressibility' of the tendon compared to a normal tendon, which is noncompressible.

4. Focal abnormal echogenicity: It has been associated with small full and partial-thickness tears. The area of increased echogenicity is thought to result from granulation tissue, hypertrophied synovium, and hemorrhage. The examiner must confirm that this is real and not an artifact or rotator cuff calcification.

**Partial-thickness tear**

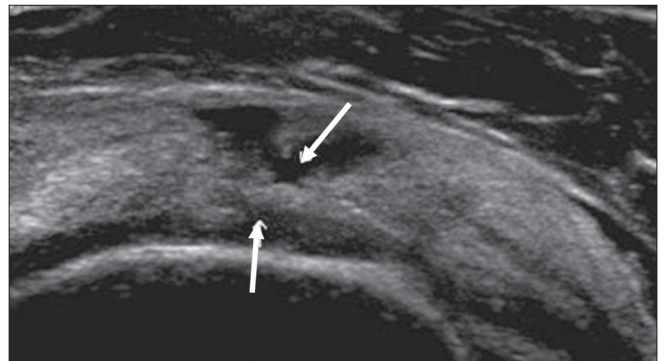
Middleton's group uses either a distinct hypoechoic or mixed hyper- and hypoechoic defect visualized in two planes at the deep articular side of the cuff, or minimal flattening of the bursal side of the cuff, as evidence of a partial-thickness tear. Partial tears can be classified as bursal surface, intrasubstance, or articular surface tears [Figure 8]. Accuracies of 80–92% have been described<sup>[17]</sup> in the diagnosis of partial-thickness tears. A recent report suggests that USG is a significantly better modality for the evaluation of partial-thickness tears than MRI.

Minor criteria for rotator cuff tear:

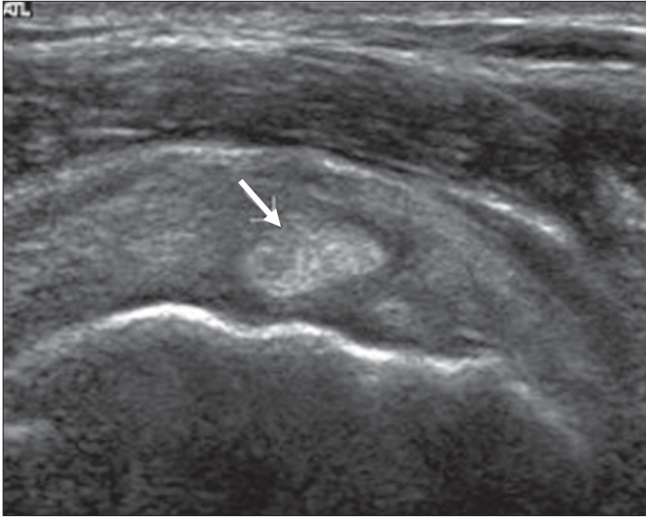
1. Fluid along the biceps tendon sheath and in the subdeltoid bursa and the joint is a very reliable sign of rotator cuff injury. Presence of fluid along the biceps tendon and in the joint suggests a 95% probability of a cuff tear.<sup>[16,17]</sup>
2. Concave subdeltoid bursal contour.
3. Irregularity of the greater tuberosity.<sup>[8]</sup>
4. Compressibility.

**Accuracy**

Accuracy of USG is operator and equipment dependent. USG has a sensitivity and specificity of 94% or greater for the detection of full-thickness tears,<sup>[18]</sup> and 93% or greater for partial-thickness tears [Weiner]. In comparison with



**Figure 8:** Partial-thickness tear of the supraspinatus. Longitudinal scan of the supraspinatus tendon shows a partial-thickness tear of the articular surface with intrasubstance involvement (arrows).



**Figure 9:** Calcific tendinitis. Longitudinal scan of the supraspinatus tendon shows focal calcification (arrow).

arthroscopy, USG has a 100% sensitivity and 85% specificity, with 95% overall accuracy.<sup>[19]</sup>

## Pitfalls

One of the major pitfalls in MSK USG is ‘anisotropy.’ An anisotropic artifact in the critical zone can result in an erroneous report. Other problems include poor understanding of the anatomy and wrong positioning of the patient and transducer. Normally, a hypochoic region is present on either side of the biceps tendon. This is the biceps tendon–rotator cuff interval and should not be confused with tendon disruption. The posterior cuff is thinner as compared with the anterior portion. This should not be mistaken for a tear. Age-related changes in the appearance of the tendon due to fibrofatty infiltration, are symmetrical.<sup>[6]</sup> As described earlier, a massive tear with an absent tendon may not be easily recognized by a novice.

## Other pathologies

### Calcific tendinitis [Figure 9]

The critical zone in the supraspinatus is the most common site for calcification, probably due to its hypovascularity. It is asymmetric in one-third of patients. USG is more reliable than x-rays for identifying calcification and judging its consistency and degree. Slurry calcifications found on USG have been proven to be nearly liquid in 93% of cases and can be successfully aspirated.<sup>[6]</sup> Dilution of calcific foci and their aspiration has also been shown to reduce symptoms.

### Acromioclavicular joint

Acromioclavicular joint inflammation often presents clinically in a similar fashion to rotator cuff disorders. The small amount of fluid that is usually present can be detected easily on USG.

## Impingement syndrome

Repetitive friction results in bursal thickening and is often accompanied by minimal fluid accumulation. The focal bursal thickening may be tender on USG palpation. During dynamic testing, the thickened bursal tissue may be seen to bunch up against the outer edge of the acromion, failing to pass beneath it. This can be easily demonstrated on USG during the impingement test.

Neer described impingement lesions in the following 3 progressive stages:

1. Edema and hemorrhage result from excessive overhead use and are observed in patients less than 25 years of age.
2. Fibrosis and tendinitis affect the bursa and the cuff, following repeated episodes of inflammation, in patients aged 25–40 years of age.
3. Bone spurs and incomplete and complete tears of the rotator cuff and the long head of the biceps tendon are found almost exclusively in patients who are more than 40 years old.

## Acknowledgement

Anatomical illustrations are from the Atlas of Human Anatomy 2nd Ed. 1997. By Frank H. Netter.

## References

1. Teefey SA, Middleton WD, Yamaguchi K. Shoulder sonography. State of the art. *Radiol Clin North Am* 1999;37:767-85.
2. Roy A. Rotator Cuff Disease: eMedicine.
3. Van Holsbeeck MT. *Musculoskeletal ultrasound*. 2nd ed. p. 46
4. Winter T. *Ultrasound of the rotator cuff*. Mumbai Ultrasound Course; 2003. p.124
5. Kolowich P, Holsbeeck M. The 16th annual conference of Musculoskeletal ultrasound society May 27-28, 2006
6. Van Holsbeeck MT, et al. *Musculoskeletal ultrasound*. 2nd ed. p. 464.
7. Ramm P. *Ultrasound of the Rotator Cuff*. ATL.
8. Wohlwend JR, van Holsbeeck M, Craig J, Shirazi K, Habra G, Jacobsen G, et al. The association between irregular greater tuberosities and rotator cuff tears: A sonographic study. *AJR Am J Roentgenol* 1998;171:229-33.
9. Mack LA, Nyberg DA, Matsen FA 3<sup>rd</sup>. Sonographic evaluation of the rotator cuff. *Radiol Clin North Am* 1988;26:161-77.
10. Crass JR, Craig EV, Feinberg SB. Ultrasonography of rotator cuff tears: A review of 500 diagnostic studies. *J Clin Ultrasound* 1988;16:313-27.
11. Winter TC, Richardson MI, Matsen FA. Rotator cuff ultrasound. *Radiologic Soc Am Electronic Jr* 1996.
12. Crass JR, Craig EV, Feinberg SB. The hyperextended internal rotation view in rotator cuff ultrasound. *J Clin Ultrasound* 1987;15:416-20.
13. van Holsbeeck M, Introcaso J, Hoogmartens M. Sonographic detection and evaluation of shoulder joint effusion. *Radiology* 1990;15:416-20.
14. Teefey SA, Hasan SA, Middleton WD, Patel M, Wright RW,

Yamaguchi K. Ultrasonography of the rotator cuff. A comparison of ultrasonographic and arthroscopic findings in one hundred consecutive cases. *J Bone Joint Surg Am*. 2000 Apr;82(4):498-504.

15. Middleton WD. Status of rotator cuff sonography. *Radiology* 1989;173:307-9.
16. Middleton WD, Reinus WR, Totty WF, Nelson GL, Murphy WA. Ultrasonographic evaluation of the rotator cuff and biceps tendon. *J Bone Joint Surg Am* 1986;68:440-50.
17. Hollister MS, Mack LM, Pattern RM, Winter TC 3rd, Matsen FA 3rd, Veith RR. The association of sonographically detected subacromial/subdeltoid bursal effusion and intraarticular fluid

with rotator cuff tear. *AJR Am J Roentgenol* 1995;165:605-8.

18. Wiener SN, Seitz WH Jr. Sonography of the shoulder in patients with tears of the rotator cuff: accuracy and value for selecting surgical options. *AJR Am J Roentgenol* 1993;160:103-7.
19. Teefey SA, Hasan SA, Middleton WD, Patel M, Wright RW, Yamaguchi K. Ultrasonography of the rotator cuff. A comparison of ultrasonographic and arthroscopic findings in one hundred consecutive cases. *J Bone Joint Surg Am* 2000;82:498-504.

**Source of Support:** Nil, **Conflict of Interest:** None declared.

## FORTHCOMING EVENTS

### 5<sup>th</sup> National Convention

Date: 2007-09-22  
 From: 2007-09-22 To: 2007-09-23  
 Venue: Krest Auditorium, Hyderabad  
 Organized by: Indian Society of Pediatric Radiology  
 Information: Pediatric Imaging. Tel: 040-23560005/65888459.  
 E-mail: vijayabhaskarnori@gmail.com

### Mumbai Ultrasound Course

From: 2007-09-27 To: 2007-09-30  
 Venue: Mumbai  
 Organized by: Dr. Mukund Joshi  
 Information: 37/900, Adarsh Nagar, Near Century Bazar, Worli P. O., Mumbai - 400 030. E-mail: muc2007@variance.com

### PET CT Conference

From: 2007-09-29 To: 2007-09-29  
 Venue: Place: - City Palace Udiapur. Durbar Hall  
 Organized by: Dr. Manas Mayank  
 Information: Ph - 09825780094.  
 Topics included: -Basics of FDG production (cyclotron), Basics of PET-CT technology. Normal variants. Disease specific topics by experts. Open discussion with oncologists using PET in their day-to-day clinical practice.

### FETAL ULTRASOUND UPDATE

Date: 2007-10-28  
 From: 2007-10-28 To: 2007-10-28  
 Venue: Hotel Fortune Landmark, Indore  
 Organized by: Ultrasound Study Foundation: Dr Sudheer Gokhale, Hon Secretary  
 Information: Focus on Fetal Anomalies & sick fetus, Live demo.  
 E-mail: ultrasoundadvice@hotmail.com

### 10<sup>th</sup> Annual Conference of ISVIR

From: 2007-11-01 To: 2007-11-04  
 Venue: Hotel Taj Deccan, Hyderabad  
 Organized by: ISVIR – Dr. S Rammurti  
 Information: Prof & Head, Dept. of Radiology & Imaging, Nizam's Institute of Medical Sciences, Panjagutta, Hyderabad – 500 082, A.P. T: 040-23320332 Ext – 431, M-9848019234. Website: www.isvir2007.org

### The 61<sup>st</sup> Annual Conference of IRIA

From: 2008-01-17 To: 2008-01-20  
 Venue: Bangalore International Exhibition Center, Bangalore, Karnataka.  
 Organized by: IRIA Karnataka State Branch  
 Information: E-mail: iriablr08@gmail.com

### USCON XVIII : Annual Conference of IFUMB

From: 2008-02-15 To: 2008-02-17  
 Venue: Hotel J. P. Palace, Agra  
 Organized by: Dr. Bhupender Ahuja  
 Information: Tel: 0562-3292959, 2852605.  
 E-mail: drahujab@sancharnet.in

### Dr. Harnam Singh mid Term CME

From: 2008-08-04 To: 2008-08-05  
 Venue: Hotel Clark's Shiraj, Agra  
 Organized by: drahujab@sancharnet.in  
 Information: Organized by UP & Uttarkhand State Chapter of IRIA.  
 E-mail: drahujab@sancharnet.in