

Abdomen

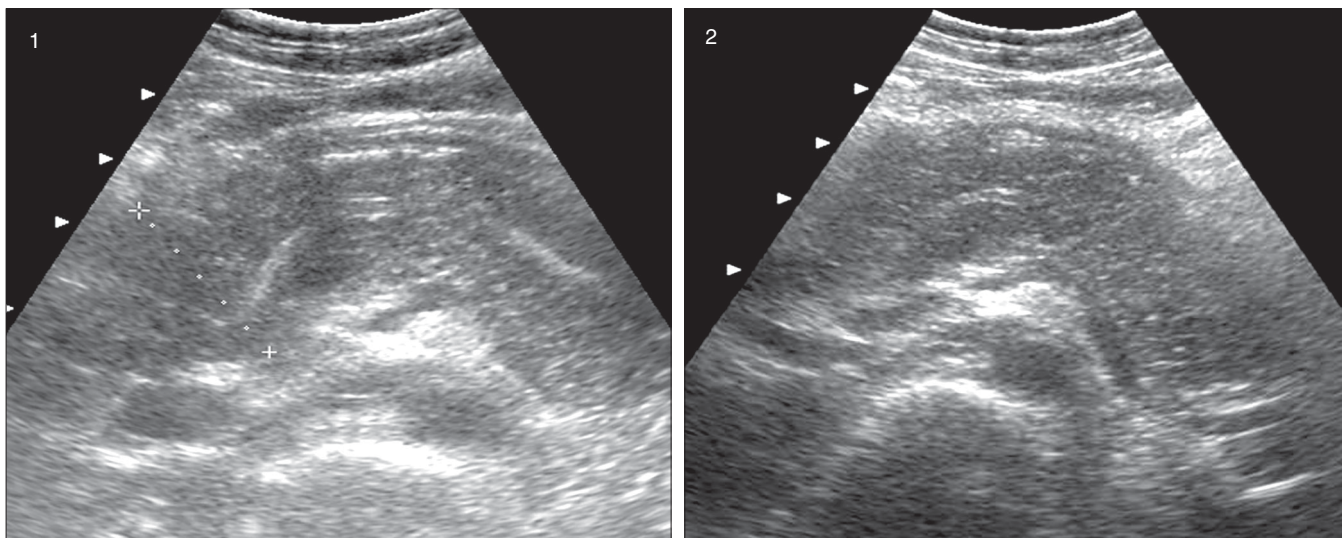
K. V. Rajagopal

Department of Radiodiagnosis and Imaging, Kasturba Medical College, Manipal affiliated to Manipal University, Manipal, India

Correspondence: Dr. KV Rajagopal, 180, KMC Quarters, Manipal, India. E-mail: rajagopalkv@yahoo.com

A 55-year-old lady presented with acute onset of pain in the epigastrium. Ultrasound of the abdomen was performed [Figures 1, 2].

What is the diagnosis?



Figures 1 and 2: USG of upper abdomen

There are two quizzes in this issue, this one and the next. Readers are requested to send in their answers to quiz@ijri.org, stating their name in full (first name and last name required, otherwise the answer will not be considered), quiz name and the answer. (e.g. Radiology Quiz: Abdomen, followed by the answer). Please do not give a differential diagnosis. The last date for submission of answers to this issue's quizzes, is June 15, 2007. The names of those who have answered correctly will be posted in the subsequent issue with the quiz answers. At the end of the year, those with the maximum correct answers will be given a special mention.