

Commentary: Ultrasonography of ocular tumors

Deepak Bhatt

Consultant Ophthalmic Sonologist, UBM Institute, A/1 Ganesh Baug, 214 Bhalchandra Road, Dadar, Mumbai - 400014, India

Correspondence: Dr. Deepak Bhatt, 8/664 Roshan Mansion Rd. No. 13, Parsee Colony, Dadar, Mumbai - 400 014, India.
E-mail: drbhatt@vsnl.com

Ocular tumors can be divided into two groups, namely tumors in infants and children and tumors in the adult age group. Retinoblastoma and its variants are seen in children, whereas choroidal melanomas and its variants are seen in adults. Two articles^[1,2] in this issue, highlight the use of USG in these two pathologies.

Retinoblastoma is seen from birth to five years of age. It has a strong genetic predisposition. Ultrasound (USG) plays a major role in the diagnosis of retinoblastoma as it shows calcification within the tumor. Calcification is seen in only 50% of retinoblastomas [Figure 1]. When present it is diagnostic of retinoblastoma, but when absent one has to resort to A-scan or CT scan to confirm the pathology.^[3]

It is very important to measure the axial length of the globe, in patients suspected to have retinoblastoma, as only retinoblastoma has normal or increased axial length, whereas all the other conditions mimicking retinoblastoma, show a reduced axial length. The only exception is when retinoblastoma involves the ciliary body and causes pthisis.

USG is an excellent tool for follow-up. Chemotherapy is the main method of treatment in retinoblastomas measuring less

than 10 mm in size. Enucleation should be the last resort, as patient compliance to enucleation is very poor and patients are then lost to follow-up. These patients often present at a later stage with metastases.^[4] As radiologists, we should not only make a diagnosis of retinoblastoma but should also impress upon the patient's parents that there is definitely a malignant lesion in the eye and that you need to take treatment for, to save the child's life. This is our social obligation and we may help in getting these children treated and saving lives.

Choroidal tumors are seen in adults [Figure 2]. Melanoma is the most common of these tumors, in the western population, but metastasis is more common in our population. The common primaries causing metastases to the choroid, are breast in women and prostate in men. Melanoma has a characteristic appearance on A-scan, color Doppler and MRI, hence these should be done before we rule out melanoma. Melanoma and choroidal metastases can be treated with chemotherapy.^[5]

Choroidal hemangiomas are also common choroidal tumors, to be considered in the differential diagnosis of melanoma and metastasis. They may be seen as solitary tumors or as part of Sturge-Weber's syndrome. The presence

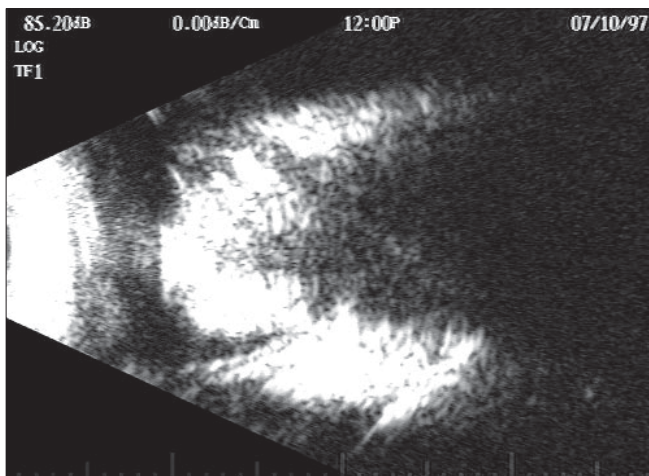


Figure 1: Retinoblastoma: USG shows a dense calcified mass lesion in the vitreous cavity.

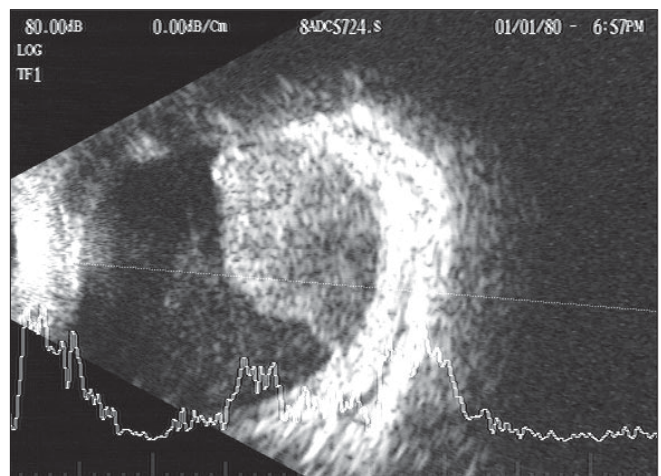


Figure 2: Choroidal metastasis: USG shows a large irregular choroidal tumor with mixed echotexture and choroidal infiltration.

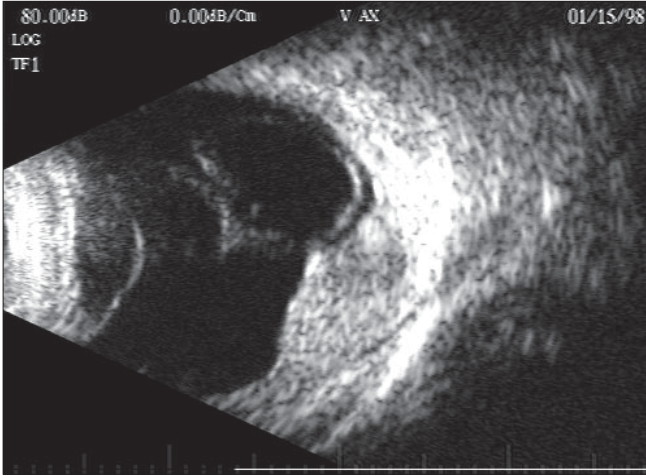


Figure 3: Choroidal hemangioma. USG shows a dome-shaped choroidal tumor with a phlebolith on its surface. There is usually vitreous hemorrhage associated with the hemangioma.

of a phlebolith is an important indicator of a choroidal hemangioma [Figure 3].

USG is the first imaging technique in suspected intraocular tumors. Other investigations such as CT and MR may be performed later to assist in further diagnosis and staging.

References

1. Aironi VD, Chougule SR, Singh J. Choroidal melanoma: A spectrum of manifestations in two cases on B-scan. *Indian J Radiol Imaging* 2007;17:8-10.
2. Aironi VD, Chougule S, Khetarpal S, Bhati G. Retinoblastoma: A spectrum of manifestations in three cases on B-scan. *Indian J Radiol Imaging* 2007;17:11-4.
3. Zilelioglu G, Gunduz K. Ultrasonic findings in intraocular retinoblastoma and correlation with histopathologic diagnosis. *Int Ophthalmol* 1995;19:71-5.
4. Shield JA, Shield CL, De Potter P. Clinical management of retinoblastoma. *Curr Opin Ophthalmol* 1994;5:83-8.
5. Perri P, Chiarelli M, Monari P, Ravalli L, Mazzeo V. Choroidal metastases. Echographic experience from 42 patients. *Acta Ophthalmol Suppl* 1992;204:96-98.

Source of Support: Nil, **Conflict of Interest:** None declared.