

# Transnasal tracheobronchial stenting for malignant airway narrowing under local anesthesia: Our experience of treating three cases using this technique

Jayanta Medhi, Akash Handique<sup>1</sup>, Amit Goyal<sup>2</sup>, Donbok Lynser<sup>1</sup>, Pranjal Phukan<sup>1</sup>, Kalyan Sarma<sup>1</sup>, Aswin Padmanabhan<sup>1</sup>, Manuj Kumar Saikia<sup>3</sup>, Happy Chutia<sup>4</sup>

Departments of Otorhinolaryngology, <sup>1</sup>Radiology and Imaging, <sup>3</sup>Cardiothoracic and Vascular Surgery and <sup>4</sup>Biochemistry, North Eastern Indira Gandhi Regional Institute of Health and Medical Sciences, Shillong, Meghalaya, <sup>2</sup>Department of Otorhinolaryngology, All India Institute of Medical Sciences, Jodhpur, Rajasthan, India

**Correspondence:** Dr. Akash Handique, Department of Radiology and Imaging, North Eastern Indira Gandhi Regional Institute of Health and Medical Sciences, Shillong - 793 018, Meghalaya, India. E-mail: drahandique@gmail.com

## Abstract

**Purpose:** To study the technical feasibility of tracheobronchial stenting via transnasal route under bronchoscopy and fluoroscopic guidance in severe malignant airway strictures using self-expandable nitinol stents. **Materials and Methods:** We describe three patients with malignant airway strictures, treated entirely via transnasal route under local anesthesia using bronchoscopic and fluoroscopic guidance. Nasal route allowed convenient access to the airway for the bronchoscope across the stricture and a guidewire was introduced through its working channel. The 18F tracheal stent and the 6F bronchial stent assembly could be easily introduced and deployed under bronchoscopic (reintroduced through the other nostril) and fluoroscopic guidance. **Results:** We achieved technical success in all the three patients with immediate relief of dyspnea. **Conclusion:** Transnasal airway stenting with self-expandable nitinol stent using bronchoscopic and fluoroscopic guidance under local anesthesia is a safe and effective method with minimal patient discomfort.

**Key words:** Fluoroscopy; local anesthesia; malignant tracheal stricture; self-expandable nitinol stent; transnasal bronchoscopy

## Introduction

Inoperable tracheobronchial malignant narrowing is increasingly managed with self-expanding metallic stents (SEMS).<sup>[1-3]</sup> The stent is usually deployed under general anesthesia through an orotracheal tube or by transtracheal (in tracheostomized patients) access. However, laryngeal mask, laryngoscopy, and conscious

sedation have been used to minimize patient discomfort time and procedure time.<sup>[2,4-7]</sup> We describe three patients with severe malignant central airway narrowing managed by self-expandable nitinol stent placement through endonasal route with the help of a flexible bronchoscope and fluoroscopic guidance under local anesthesia.

This is an open access article distributed under the terms of the Creative Commons Attribution-NonCommercial-ShareAlike 3.0 License, which allows others to remix, tweak, and build upon the work non-commercially, as long as the author is credited and the new creations are licensed under the identical terms.

**For reprints contact:** reprints@medknow.com

**Cite this article as:** Medhi J, Handique A, Goyal A, Lynser D, Phukan P, Sarma K, *et al.* Transnasal tracheobronchial stenting for malignant airway narrowing under local anesthesia: Our experience of treating three cases using this technique. *Indian J Radiol Imaging* 2016;26:103-7.

### Access this article online

#### Quick Response Code:



**Website:**  
www.ijri.org

**DOI:**  
10.4103/0971-3026.178357

## Materials and Methods

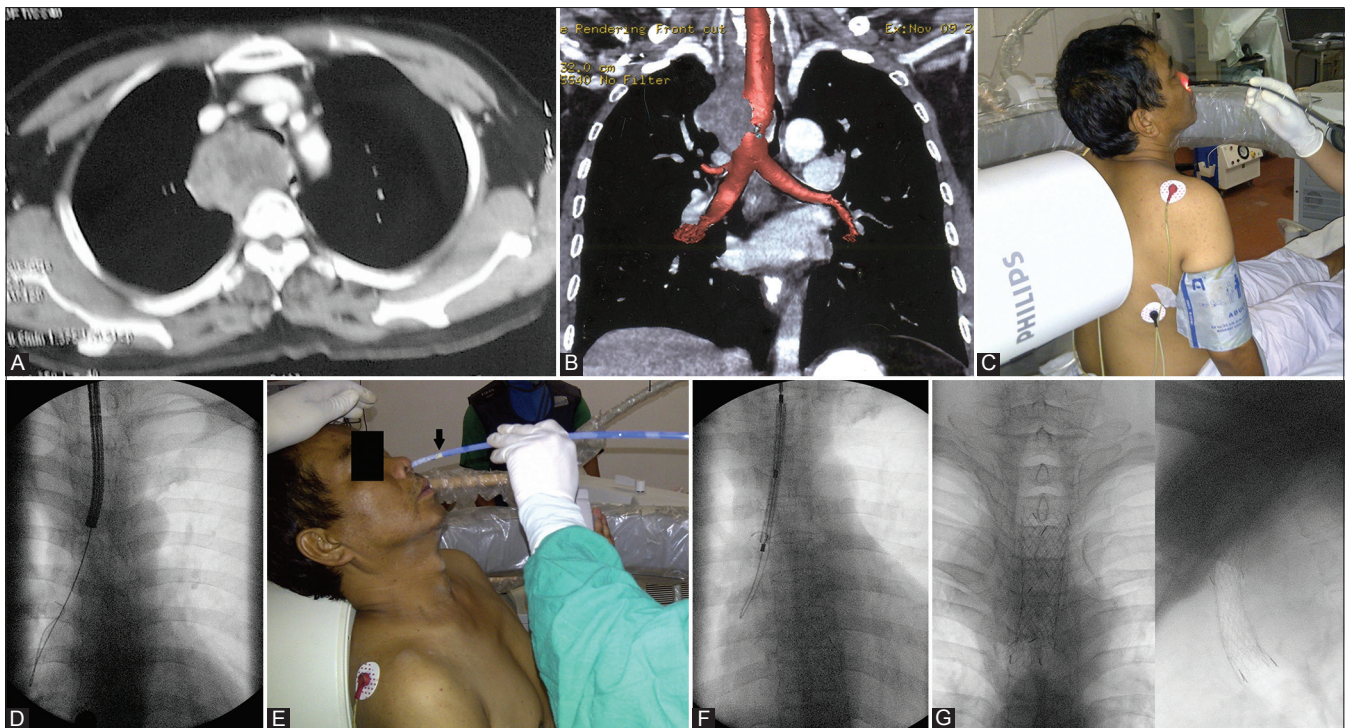
Three men with inoperable malignant severe tracheal or bronchial stenosis were treated between October 2012 and March 2015 [Table 1]. CT studies available showed >90% stenosis of trachea in patient no. 1 and 2 [Figures 1A and B, 2A] and left bronchial narrowing of 60% in patient no. 3 [Figure 3A and F]. The first two patients presented with significant dyspnea and

stridor, while the third patient had the complaint of tracheoesophageal fistula but was not symptomatic for left bronchial narrowing [Figure 3B]. However, this patient risked imminent left bronchial obstruction either due to disease progression or during esophageal stenting, as its radial force might further displace the infiltrating mass into the left bronchus. Therefore, left bronchial stenting prior to covered esophageal stent placement was planned. These procedures were approved by our institute review

**Table 1: Summary of the patients who underwent transnasal tracheobronchial stenting with bronchoscopic and fluoroscopic guidance under local anesthesia**

Patient number	Age (years)/sex	Etiology/site (all squamous cell carcinoma)	Clinical findings	Stent (diameter × length in mm, covered/uncovered, delivery system profile)	Relief of respiratory distress	Follow-up
1	40/male	Upper third esophagus growth with a right sided paratracheal nodal mass compressing and infiltrating the trachea just above the carina	Difficulty in breathing for 1 week, mild dysphagia 1 month, right vocal cord palsy	Niti-S tracheobronchial stent (20 mm × 60 mm, full covered, 18F)	Yes	2 months, died of massive hemoptysis
2	52/male	A right sided para-tracheal mass with infiltration and significant narrowing of the upper trachea	Difficulty in breathing for 5 days, moderate to severe restriction on PFT, neck swelling for 3 months, dysphagia 3 months	Niti-S tracheobronchial stent (20 mm × 60 mm, uncovered, 18F)	Yes	2 months, 26 days, died following aspiration while drinking water
3	67/male	Carcinoma upper third of esophagus infiltrating the left main bronchus. tracheo-esophageal fistula just above the carina	No difficulty in breathing, dysphagia 2 months with recent onset cough immediately after taking fluids	Maris Plus, (12 mm × 40 mm, bare nitinol, 6F)	Yes	Alive at 2 months and 10 days

PFT: Pulmonary function tests



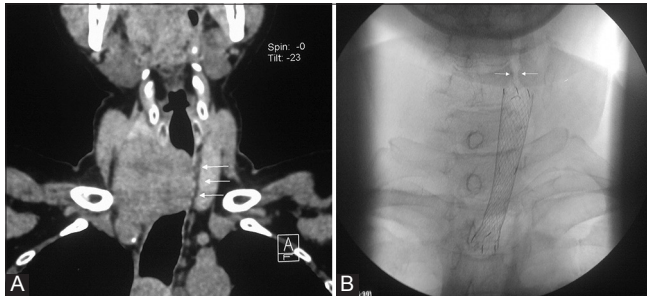
**Figure 1 (A-G):** CT findings and steps of transnasal stent deployment in patient no. 1. (A) Contrast-enhanced CT axial image and (B) coronal CT reconstruction image with volume-rendered tracheal lumen shows severe tracheal narrowing due to a nodal mass from the right side just above the carina. (C) Transnasal introduction of bronchoscope in sitting position. (D) Fluoroscopic image of guidewire placement via bronchoscope. (E) Transnasal introduction of Comvi™ covered tracheal stent. Note the position of the proximal yellow marker (black arrow). (F) Radiograph of stent assembly in position just before deployment. (G) Radiographs showing fully deployed tracheal stent in antero-posterior and lateral views

board and were performed in accordance with the ethical standards of our institute.

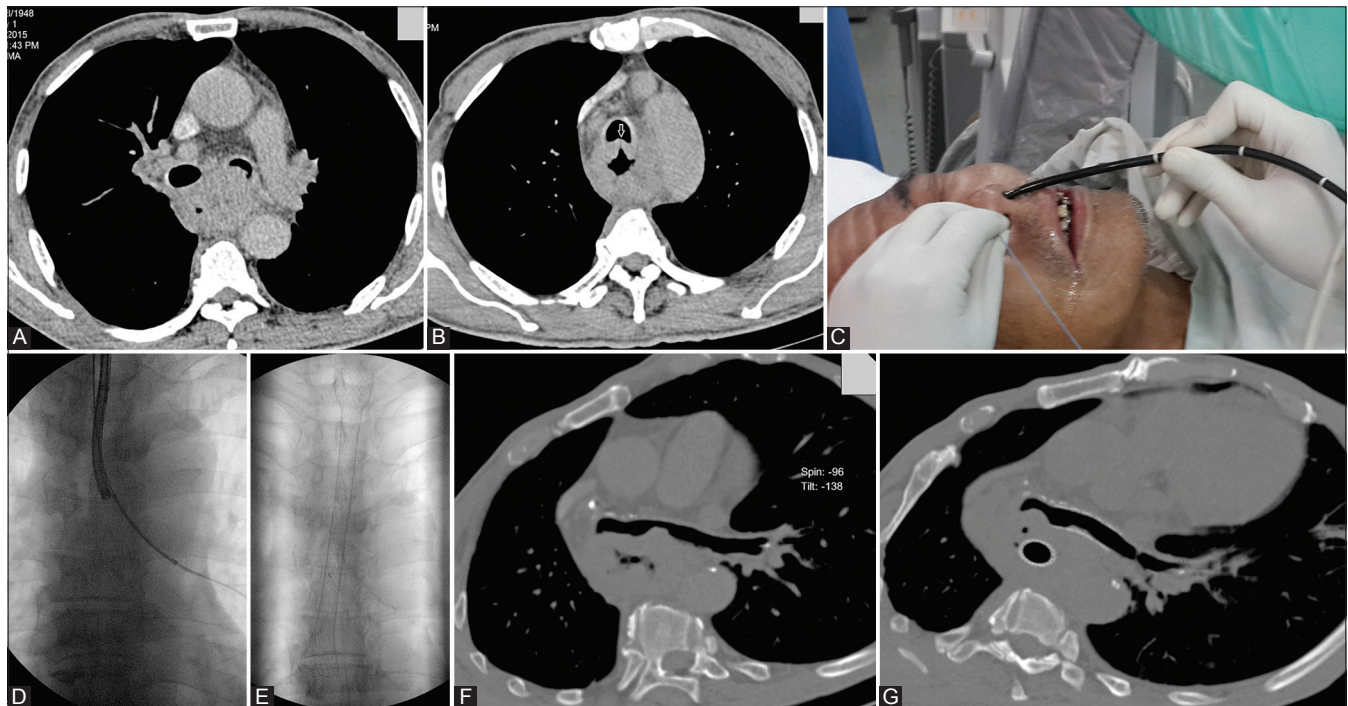
### Technique

An informed consent was obtained prior to the procedure. The procedure was performed on a C-arm compatible OT table with monitoring of vitals. In patient no. 1, the procedure was done with the patient in sitting position due to severe dyspnea. The other two patients were treated in supine position. Pharyngeal mucosa was desensitized

with aerosolized 4% lignocaine. Superior laryngeal nerve block was given to anesthetize the supraglottic larynx. Transtracheal 4% lignocaine was used for tracheal anesthesia and to inhibit cough. Flexible adult bronchoscope (Model 11001BN1; Storz, Tuttlingen, Germany) with a diameter of 5.2 mm and a working channel of 2.3 mm was introduced through a nostril to the site of narrowing and negotiated beyond the lesion [Figure 1C and D]. A guidewire (J-tip 0.035", 260 cm superstiff Amplatz guidewire (Cook, Bloomington, USA) was passed through the working channel of the bronchoscope across the stenosis up to a segmental bronchus under fluoroscopy (BV Endura mobile 9" C-Arm; Philips, DA Best, The Netherlands) [Figure 1D]. The bronchoscope was withdrawn carefully keeping the guidewire in place and re-introduced through the other nostril to monitor the stent deployment [Figure 3C]. For tracheal stenosis, a Niti-S™ Comvi™ tracheobronchial self-expandable nitinol stent 20 mm × 60 mm with 18F delivery system (Taewoong Medical, Gyeonggi-do, Korea) was used [Figures 1F and G, 2B]. This delivery device has a yellow marker at the proximal end of the stent to aid easy positioning without fluoroscopy. The yellow marker must be beyond the vocal cord to avoid accidental deployment at supraglottic or glottis level [Figure 1E]. For left bronchial stenting, a 12 mm × 40 mm Maris Plus self-expandable nitinol stent (Medtronic, Minneapolis, USA) with 6F



**Figure 2 (A and B):** (A and B) Tracheal stenting in high tracheal obstruction (patient no. 2). (A) Coronal CT reconstruction image showing upper tracheal narrowing due to an infiltrating paratracheal mass causing significant obstruction (white arrows). (B) Radiograph shows tracheal stent deployed across the obstruction. Note vocal cords indentations safely above the stent margin (white arrows)



**Figure 3 (A-G):** (A-G) Stenting for left bronchial narrowing (patient no. 3). CT images taken before and after the procedure with radiographs and photographs of the procedure. (A) CT images show left bronchial infiltration of the esophageal mass and (B) associated tracheoesophageal fistula (open white arrow). (C) Photograph shows transnasal access of left bronchus with the guidewire through the right nostril and bronchoscope re-introduced through the left nostril. (D) Radiograph shows transnasal bronchoscope proximal to the undeployed stent in the left bronchus. (E) Post-procedure radiograph shows the left bronchial and esophageal stents. (F) Pre-treatment and (G) Post-treatment oblique CT reconstructions along the left bronchus for comparison, showing the severity and extent of left bronchial narrowing which is resolved after stenting

delivery system was used [Figure 3D, E and G]. All stents could be easily negotiated over the guidewire across the stricture under bronchoscopic and fluoroscopic guidance and deployed. No balloon dilatation was necessary. In patient no. 3, a covered self-expandable nitinol esophageal stent (Expanse, Indus Medical, Kolkata, India) was deployed transorally under fluoroscopic guidance to treat the tracheoesophageal fistula [Figure 3E and G].

## Results

All procedures were technically successful. Immediate improvement in ventilation was noticed with disappearance of stridor following tracheal stenting. Esophageal stent placement after left bronchial stenting was uneventful. No stent migrations were observed.

## Discussion

Transnasal tracheobronchial interventions including bronchoscopic biopsies, lavage, balloon dilatation of tracheobronchial stenosis, and treatment of bronchobiliary fistula have been described;<sup>[8]</sup> however, to our knowledge, successful tracheal stenting through the nasal route has not been described earlier. Transnasal bronchoscopy is better tolerated than a transoral procedure. No prior intubation or general anesthesia is necessary, thereby significantly shortening the procedure time.<sup>[8,9]</sup> Smaller diameter fiber-optic bronchoscopes and smaller profile flexible stent introducer system have enabled us to perform these procedures in a quick and safe manner. In our institute, all adult bronchoscopies are done through transnasal route. Maximum diameter of covered Comvi tracheobronchial stent delivery system is 6 mm (18F), which is similar to most bronchoscopes, ultrathin endoscopes (4.9–6 mm),<sup>[10]</sup> and wide bore nasogastric tubes (up to 20F, 6.67 mm; Romsons Scientific, Agra, India) for transnasal use. Easy transnasal passage of our flexible bronchoscope, which has a diameter of 5.2 mm, ensured easy navigation of the 6 mm (18F) delivery device. A failed attempt to deploy tracheal stent transnasally has been described possibly due to a larger delivery system (9 mm, 27F) of 20 mm × 40 mm Ultraflex™ tracheal stent.<sup>[11]</sup> One possible limitation of our technique includes any significant obstruction in the nasal cavity including deviated nasal septum, nasal polyp, etc. In unilateral obstruction such as deviated nasal septum, initial access can be made through the other nostril for bronchoscopy followed by stent deployment, while bronchoscopic monitoring can be done via transoral access without any other modification. A variety of self-expandable stents are available to treat airway narrowing, the most common being wallstent and ultraflex stents (Boston Scientific, Marlborough, MA, USA).<sup>[1-7,11]</sup> Despite their limitations, silicone stents are also used by bronchoscopists, especially for benign diseases, and they require direct bronchoscopy under

general anesthesia for deployment.<sup>[4,12]</sup> Choice depends largely upon expertise, user preference, availability, and patient-specific requirements.

Tracheobronchial stenting is performed using various techniques utilizing a flexible or rigid endoscope often under general anesthesia<sup>[1,13,14]</sup> with endotracheal intubation or laryngeal mask.<sup>[7]</sup> Venovenous extracorporeal membrane oxygenation (VV ECMO) has also been used for critical stenoses.<sup>[15]</sup> Others have described the procedure under conscious sedation and local anesthesia with either fluoroscopic<sup>[2,3]</sup> or bronchoscopic guidance.<sup>[16]</sup> We consider fluoroscopic guidance absolutely necessary for accurate self-expandable nitinol airway stent placement.

Performing the procedure through the nasal route is convenient for the patient and easier for the therapist to manipulate the instruments even in awake patients. In addition, oral route is kept free for any anesthetic intervention during the procedure.

## Conclusion

To conclude, tracheobronchial stenting using self-expandable nitinol stent through transnasal route is safe, simple, straightforward, and least traumatic to the patient.

## Declaration of patient consent

The authors certify that they have obtained all appropriate patient consent forms. In the form the patient(s) has/have given his/her/their consent for his/her/their images and other clinical information to be reported in the journal. The patients understand that their names and initials will not be published and due efforts will be made to conceal their identity, but anonymity cannot be guaranteed.

## Acknowledgments

We sincerely thank Mr. Rupak Dutta, Mr. I. Shurchandra Singh, Ms. Zhavino Yesa and Mr. Atul Lagun for helping us plan, perform and document these procedures.

## Financial support and sponsorship

Nil.

## Conflicts of interest

There are no conflicts of interest.

## References

1. Breitenbücher A, Chhajed PN, Brutsche MH, Mordasini C, Schilter D, Tamm M. Long-term follow-up and survival after ultraflex stent insertion in the management of complex malignant airway stenoses. *Respiration* 2008;75:443-9.
2. Profili S, Manca A, Feo CF, Padua G, Ortu R, Canalis GC, *et al.* Palliative airway stenting performed under radiological guidance and local anesthesia. *Cardiovasc Intervent Radiol* 2007;30:74-8.

3. Shin JH, Kim SW, Shim TS, Jung GS, Kim TH, Ko GY, *et al.* Malignant tracheobronchial strictures: Palliation with covered retrievable expandable nitinol stent. *J Vasc Interv Radiol* 2003;14:1525-34.
4. Shin JH, Song HY, Shim TS. Management of tracheobronchial strictures. *Cardiovasc Intervent Radiol* 2004;27:314-24.
5. Conacher ID. Anaesthesia and tracheobronchial stenting for central airway obstruction in adults. *Br J Anaesth* 2003;90:367-74.
6. Finlayson GN, Brodsky JB. Anesthetic considerations for airway stenting in adult patients. *Anesthesiol Clin* 2008;26:281-91, vi.
7. Tanigawa N, Sawada S, Okuda Y, Sougawa M, Komemushi A, Kojima M, *et al.* Expandable metallic stent placement in upper tracheal stenosis: Value of laryngeal masks. *AJR Am J Roentgenol* 2001;177:1423-6.
8. Rees CJ. In-office unsedated transnasal balloon dilation of the esophagus and trachea. *Curr Opin Otolaryngol Head Neck Surg* 2007;15:401-4.
9. Verma SP, Smith ME, Dailey SH. Transnasal tracheoscopy. *Laryngoscope* 2012;122:1326-30.
10. ASGE Technology Committee, Rodriguez SA, Banerjee S, Desilets D, Diehl DL, Farraye FA, *et al.* Ultrathin endoscopes. *Gastrointest Endosc* 2010;71:893-8.
11. Juvekar NM, Neema PK, Manikandan S, Rathod RC. Anesthetic management for tracheal dilatation and stenting. *Indian J Anaesth* 2003;47:307-10.
12. Puma F, Ragusa M, Avenia N, Urbani M, Droghetti A, Daddi N, *et al.* The role of silicone stents in the treatment of cicatricial tracheal stenoses. *J Thorac Cardiovasc Surg* 2000;120:1064-9.
13. Saad CP, Murthy S, Krizmanich G, Mehta AC. Self-expandable metallic airway stents and flexible bronchoscopy: Long-term outcomes analysis. *Chest* 2003;124:1993-9.
14. Schmidt B, Olze H, Borges AC, John M, Liebers U, Kaschke O, *et al.* Endotracheal balloon dilatation and stent implantation in benign stenoses. *Ann Thorac Surg* 2001;71:1630-4.
15. Hong SH, Moon YE, Lee SR, Cho SJ, Kwon OK. Anesthetic management for the insertion of a self-expandable metallic tracheal stent under venovenous extracorporeal membrane oxygenation. *Korean J Anesthesiol* 2012;63:569-70.
16. Herth F, Becker HD, LoCicero J 3<sup>rd</sup>, Thurer R, Ernst A. Successful bronchoscopic placement of tracheobronchial stents without fluoroscopy. *Chest* 2001;119:1910-2.