

# Is decreased diameter of renal pelvis in prone position an indicator of successful pyeloplasty?

Gyanendra Sharma, Anshu Sharma<sup>1</sup>, Vivian Yee-Fong Leung<sup>2</sup>, Winnie Chiu-Wing Chu<sup>2</sup>

Departments of Urology, and <sup>1</sup>Radio-Diagnosis, Chitale Clinic Private Limited, Solapur, Maharashtra, India,

<sup>2</sup>Department of Imaging and Interventional Radiology, The Chinese University of Hong Kong, Prince of Wales Hospital, Hong Kong SAR, China

**Correspondence:** Dr. Gyanendra Sharma, Department of Urology, Chitale Clinic Private Limited, 165 D Railway Lines, Solapur - 413 001, Maharashtra, India. E-mail: dgrsharma@gmail.com

## Abstract

**Objective:** To evaluate patients who had undergone pyeloplasty for pelviureteric junction obstruction, by measuring the anteroposterior diameter (APD) of the renal pelvis in supine and prone positions, and determine whether a decrease in APD in prone position can exclude obstruction in dilated renal system. **Materials and Methods:** From January 2012 to December 2013, patients who had undergone pyeloplasty were evaluated by ultrasound in two centers. The difference of APD of the renal pelvis in supine and prone positions was obtained. Correlation was made with the pre- and post-pyeloplasty renal function by radionuclide renogram. **Results:** There were 42 patients (31 males, 11 females; age range 5 months to 18 years). Residual hydronephrosis was detected in 41 patients of whom 35 patients (85%) showed decrease in APD by >10% in prone position. These patients and the one without hydronephrosis showed either no deterioration or improvement in renal function. Six patients (15%) showed either no change or increase in APD in prone position. Three patients (7.5%) were confirmed to have decrease in renal function indicating obstruction. Three patients (7.5%) showed no deterioration of renal function, but sluggish drainage on radionuclide renogram. **Conclusion:** Demonstration of decreased APD of renal pelvis in prone position by ultrasound is useful to differentiate obstructed from non-obstructed dilated renal system, and it correctly identified 85% candidates with successful pyeloplasty. In patients with no decrease or increase in APD at prone position, further follow-up is recommended to rule out obstruction.

**Key words:** Hydronephrosis; pelvi ureteric junction obstruction; pyeloplasty; ultrasonography

## Introduction

Dismembered pyeloplasty for pelviureteric junction obstruction (PUJO) has a high success rate.<sup>[1-3]</sup> Considering that majority of patients will experience a favorable outcome following pyeloplasty, a large number of patients routinely undergo post-operative evaluation by which problems occurring in some patients can be

detected.<sup>[3]</sup> USG and radionuclide renograms are commonly used to document success following pyeloplasty.<sup>[3,4]</sup> While differential functions have been sufficiently evaluated, a number of studies have shown that the function and curve pattern do not always improve on renograms after pyeloplasty.<sup>[3-11]</sup> Ultrasound is a useful, non-invasive tool to assess hydronephrosis, but only few studies have evaluated its role after pyeloplasty.<sup>[3,4,9,12,13]</sup> Besides the inability to quantify the functional status of the kidney, the use of ultrasound as a marker of success of pyeloplasty is limited due to the persistence and, at times, worsening of dilatation of pelvicalyceal system after pyeloplasty.<sup>[4,12-15]</sup> To overcome these drawbacks, previous investigators have proposed using ultrasound to calculate pelvis/cortex ratio and percent improvement in anteroposterior diameter (APD) to predict the success of pyeloplasty.<sup>[3,4]</sup> But these have not gained widespread acceptance and the technique concerned has not been standardized.

### Access this article online

#### Quick Response Code:



**Website:**  
www.ijri.org

**DOI:**  
10.4103/0971-3026.178282

In this study, we used a standardized ultrasound technique to evaluate the APD of the renal pelvis in patients underwent pyeloplasty and compared the measurements between supine and prone positions with the aim to determine whether the difference between the two helps to exclude obstruction in dilated renal system post pyeloplasty and predict the success of pyeloplasty.

## Materials and Methods

### Patient selection

The study was carried out in two different sites with a standardized technique that has been described subsequently. The first institution is in a developing country with mobile population. Pediatric patients (age 0-15 years) who had undergone pyeloplasty (either in the same institute or other institutes) were consecutively recruited to the study from January 2012 to December 2013. These subjects attended the institute either for follow-up following pyeloplasty or for other non-urological problems. As there was no institutional review board, consents were obtained from the parents and management of the hospital. Those patients who did not have a pre-pyeloplasty renogram were excluded from the study. The second institution is a tertiary referral center for pediatric urology in a developed country. All subjects (age 0-15 years) underwent pre-operative assessment and pyeloplasty in the same institute, and were being regularly followed up after the surgery. As there is no Institutional Review Board in the first institute, consent of the management of the hospital was taken while in the second institute approval from the head of department of ultrasonography was taken. Consent from the parents was obtained after explaining the procedure to them.

### Technique of ultrasonography

Ultrasound examination was performed by a single operator (VYFL, sonographer >20 years of experience and AS, radiologist >7 years of experience) in each tertiary care center, respectively using the Prosound Alpha 6 machine from Hitachi-Aloka Medical America, Inc. The imaging procedure was standardized as follows:

All children were instructed to have adequate fluid intake prior to the study as the measurement of APD could be variably affected by hydration status of the subject, particularly in children.<sup>[3]</sup> Just before the ultrasound scanning, all subjects were instructed to void (in infants, we ensured an almost empty bladder was visualized before scanning started) as a full bladder could impair drainage of urine from the kidneys into the bladder and affect the APD measurement. APD was first measured in the transverse plane at the level of renal hilum with the patient in supine position and with the ultrasound probe placed laterally in mid-axillary line. Afterward, the measurement was repeated when the patient lay prone. Each APD was measured three times and the average was

taken. Appropriate magnification was done for correct measurements. During this examination, the presence or absence of calyceal dilatation was also recorded.

### Analysis of change in APD

At the end of each examination, the percentage change of APD was calculated with the following formula:

% change in APD = (average APD in supine position - average APD in prone position)/average APD in supine position × 100.

A % change of greater than +10% was taken to be an indicator of non-obstructed collecting system.

The reproducibility and degree of agreement of supine and prone APD measurements of 10 subjects were compared between the two operators [VYFL, WCWC (radiologist with >20 years experience)] in the second institute. To determine the intra-observer error, three measurements were obtained for APD in both supine and prone positions by each operator. To determine inter-observer error, the mean values from all APD measurements were compared between the two operators.

### Nuclear studies

All patients included in this study had also undergone a pre-operative and at least one post operative diuretic radionuclide renogram (Symbia E Gamma camera, Siemens; USA) using either EC[Ethylene Dicycysteine] or MAG3 [Mercapto acetyl triglycine]. The difference in differential renal functions before and after pyeloplasty was evaluated. In the second institute, reference was also made for patients who had more than one post-op pyeloplasty renograms performed. If there was no interval deterioration (in which deterioration was defined as an interval drop of >5% differential function) or there was improvement in differential renal function post pyeloplasty, and the patient was asymptomatic, the pyeloplasty was regarded as successful.

### Outcomes

The primary hypothesis of the study was to see if a decrease in APD in prone position was indicative of successful pyeloplasty. The secondary objective was to see if those who did not show a decrease in APD in prone position had deterioration of renal function by >5% suggesting persistent obstruction requiring a secondary pyeloplasty.

### Statistical analysis

The results were tested using Wilcoxon signed rank sum test for difference in APD between supine and prone positions. The relationship between change in APD and success of pyeloplasty as indicated by the results of diuretic radionuclide renogram was tested by Chi-square test. Both statistical tests were performed at 5% level of significance using the statistical analysis software SPSS version 19 [IBM Corp. Released 2010. IBM SPSS Statistics for Windows, Version 19.0. Armonk, NY: IBM Corp.].

## Results

In the first institution, out of 48 patients, 12 did not have a pre-pyeloplasty renogram and hence were excluded from the study. In the second institution, seven patients with complete record were recruited. In the total cohort of 43 patients included (31 males and 12 females; age from 5 months to 18 years), 33 had undergone left-sided and 9 had undergone right-sided dismembered pyeloplasty. The postoperative time period ranged from 3 months to 15 years. None of them had symptoms suggestive of obstruction. There was excellent correlation in repeated measurements made by the operators. The Intraclass correlation [ICC] for the single operator was 0.986 (95% CI 0.978-0.991). There was also very good reproducibility between the two operators (ICC = 0.85, 95% CI = 0.70-0.94).

There was no hydronephrosis seen in one patient and this patient did not show any deterioration of renal function in the post-pyeloplasty renogram [no. 18 in Table 1]. There were 36 patients who had a decrease of APD by >10% in prone position [Figures 1-3]. They had either improvement or no deterioration of renal function in their post-pyeloplasty renograms as compared to their pre-pyeloplasty renograms [Table 1, Figure 1]. This association was statistically significant ( $P < 0.005$  by Chi-square test). This confirmed the primary hypothesis of the study that a decrease in APD by >10% in prone position suggests a successful pyeloplasty.

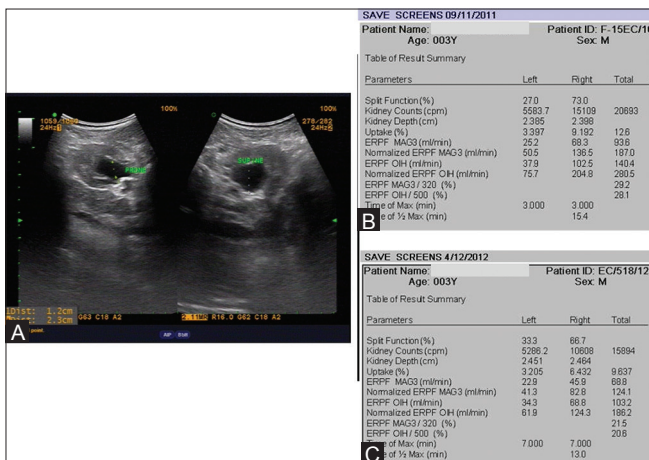
There were five patients who had an increase in APD in prone position [Figure 4], and in one patient, there was no change in APD in prone position [Table 2]. Three of these patients had deterioration of function of the operated kidney, as compared to the pre-pyeloplasty renograms [Figure 4]. Deterioration of differential renal function ranged from

6 to 12%. This was taken as indicative of secondary PUJO and these subjects were advised a second pyeloplasty. Calyceal dilatation was also noted these patients.

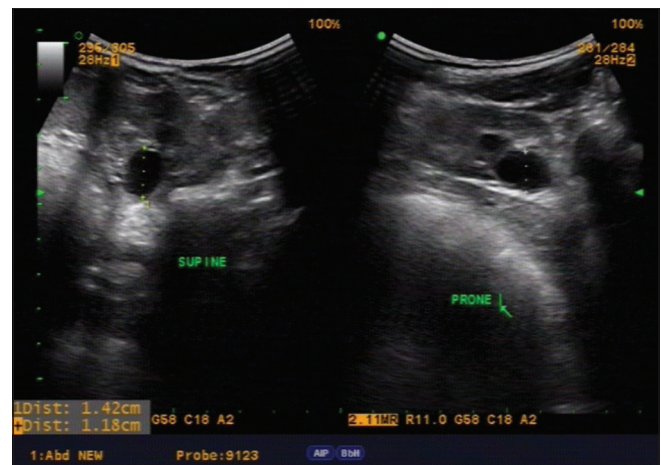
In three subjects who showed increase in APD (range from 8.8 to 27.4%) in prone position, the differential renal function on MAG3 renogram was either static or improved. Review of dynamic images of the radionuclide renogram showed sluggish drainage from the dilated pelvis into the ureter but no definite accumulation of tracer with time. All three subjects underwent another follow-up renogram within the next 6 months which confirmed static differential renal function. Thus, the secondary objective, that is, an absence of decrease in APD in prone position/increase in APD in prone position indicates a failed pyeloplasty, could not be ascertained as statistically significant.

## Discussion

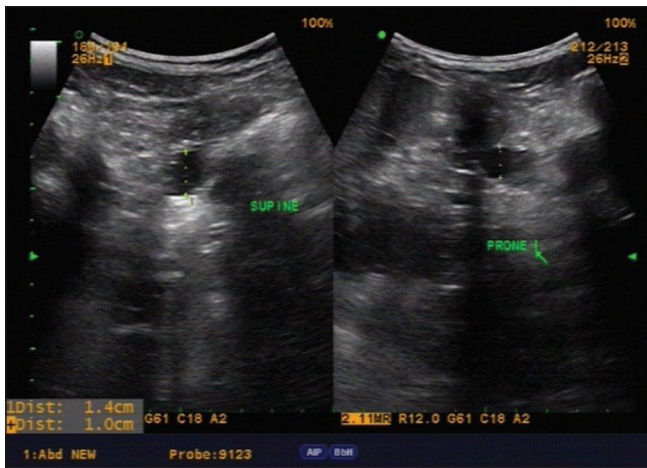
The success of pyeloplasty is conventionally evaluated with ultrasound by demonstrating a decrease in hydronephrosis and with radionuclide renograms by showing improvement in function and/or drainage pattern.<sup>[3,4,12]</sup> Diuretic renography has been regarded as the gold standard to document surgical success of pyeloplasty, but is invasive, expensive, and is associated with the risk of radiation. At times, despite pyeloplasty, the renal function and drainage pattern show no improvement on radionuclide renogram, leading to a diagnostic dilemma for the clinician and anxiety among patients and parents. Furthermore, residual hydronephrosis (even though to a lesser degree compared with the pre-op status) is common after pyeloplasty. Patients who undergo pyeloplasty later in life also have persistence of hydronephrosis and poor radiological improvement due to the decreased resilience of the renal pelvis.<sup>[9,12]</sup> Patients are, therefore, advised to have repeated assessment by ultrasound and/or diuretic renogram. Studies have shown that repeated nuclear



**Figure 1 (A-C):** (A) Post-pyeloplasty ultrasound showing APD of left kidney in supine 23 mm and in prone position 12 mm (B) Pre-pyeloplasty renogram showing left kidney having 23% differential function (C) Post-pyeloplasty renogram showing 33.3% of left kidney – improved renal function suggesting a successful pyeloplasty



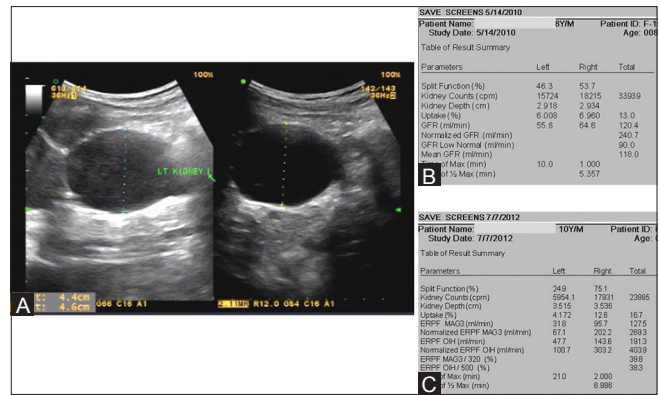
**Figure 2:** Post Pyeloplasty ultrasound showing APD of 1.42 cm in supine and 1.18 cm in prone position



**Figure 3:** Post Pyeloplasty ultrasound showing APD of 14 mm in supine and 10 mm in prone position

studies are not necessary as it is uncommon for patients to have significant fluctuations in split function.<sup>[3,11]</sup> Also, given the >95% success rate of pyeloplasty, the large number of renograms currently performed in daily practice are not cost-effective for identifying just a small portion of patients who might be benefitted; therefore, a more selective approach is advocated. Some investigators have also questioned the value of routine radionuclide renogram after pyeloplasty. Ultrasound alone has been proposed for the initial assessment after pyeloplasty, with renogram reserved for those patients who do not show improvement on ultrasonography.<sup>[12,16]</sup>

Though ultrasound is easily accessible and non-invasive, it is, by nature, operator dependent. The status of pre-ultrasound hydration and the amount of urine in the bladder can affect the degree of hydronephrosis.<sup>[3,13]</sup> The degree of hydronephrosis is also very variable postoperatively. Amling *et al.* found that hydronephrosis could remain the same or worsen in the first several months following pyeloplasty even in those kidneys which show good response to surgery ultimately.<sup>[12]</sup> Kis *et al.* found slow improvement in the pelvic dilatation in the first postoperative year.<sup>[15]</sup> Park *et al.* found faster improvement in grade III hydronephrosis as compared to grade IV hydronephrosis, but even when all grades of hydronephrosis were considered, only 56% of patients achieved normalization.<sup>[9]</sup> Nest *et al.* found that majority of cases took more than 6 months to improve on ultrasound.<sup>[14]</sup> To the best of our knowledge, currently there is no international recommended standardized protocol to guide ultrasound measurement for determining the severity of hydronephrosis.<sup>[17]</sup> Investigators have tried to determine the success of pyeloplasty on ultrasound by using various parameters such as calyx/parenchyma ratio,<sup>[18]</sup> parenchyma/pelvicalyceal area ratio,<sup>[19]</sup> pelvis/cortex ratio,<sup>[4]</sup> and percent improvement in APD.<sup>[9]</sup> Very few studies have evaluated the usefulness of Resistive Index and Resistive Index Ratio, as determined by Doppler evaluation of the kidneys, in



**Figure 4 (A-C):** (A) Post-pyeloplasty ultrasound showing APD of left kidney in supine 44 mm and in prone position 46 mm (B) Pre-pyeloplasty renogram showing 46% differential function of left kidney (C) Post-pyeloplasty renogram showing 24.9% differential function of left kidney, indicating obstruction

patients who have undergone pyeloplasty. Though these parameters correlate well with the results of diuretic renography,<sup>[20]</sup> they cannot differentiate a non obstructed collecting system from PUJO,<sup>[21]</sup> especially if there has been severe damage initially.<sup>[20]</sup>

There is usually a dilemma of differentiating a dilated but non-obstructive system from a dilated and obstructed system in post-pyeloplasty patients. The above scenario is particularly complicated in situations where patients usually come to seek medical advice with no previous records. Some patients do have regular follow-up, but radionuclide renograms might not be available. Ultrasound is commonly used as an investigatory tool for any abdominal problem. If hydronephrosis is found, it is not easy to distinguish whether it is due to residual hydronephrosis or secondary PUJO.<sup>[5-7,12,22]</sup> We sought to look for a solution to this dilemma by comparing the renal pelvis APD in supine and prone positions. The rationale of the design of the study is based on the fact that the renal pelvis and collecting system drains better in prone position. In the prone position, the proximal end of ureter is placed more anteriorly than the upper pole of the kidney. The pelvis also falls anterior to the psoas muscle. So, the pelvis and upper ureter fill more rapidly in prone position.<sup>[23-26]</sup> The non-obstructed dilated pelvis would drain better in prone position and would have an APD less than that in the supine position. On the other hand, the obstructed systems would not drain better in prone position, and hence, the APD of these systems, in prone position, would be more or equal to the APD in supine position.

The same rationale has been employed and proved to be valid by the authors in evaluation of prenatally detected PUJ obstruction. In the previous study, children who had a decrease in APD in prone position by >10% as compared with supine position showed resolution or no deterioration of hydronephrosis and did not require pyeloplasty, while those who showed no decrease in APD in prone position had

**Table 1: Demographic data, ultrasound findings, and differential renal function in children who has reduced APD from supine to prone position (negative value at % change in APD)**

No.	Age	Sex	Side	Time since surgery	Pre surgery renal function (%)	Post surgery renal function (%)	APD supine in mm	APD prone in mm	Change in APD (%)	Calyceal dilatation
1	18 years	F	L	12 years	30	32	28	16	-42.9	No
2	9 years	F	L	1½ years	29	36	20	4	-80	No
3	4 years	M	L	1 year	30	33	28	22	-21.43	No
4	11 years	M	L	10 years	21	21	29	21	-27.59	No
5	11 years	F	R	9 years	18	20	28	18	-35.72	No
6	5 months	M	R	3 months	31	34	10	8	-20	No
7	8 years	M	L	4 months	35	40	12	8	-33.33	No
8	3 years	M	R	2 years	30	37	26	14	-46.15	No
9	3 years	M	R	5 years	35	35	16	13	-18.75	No
10	3 years	M	L	5 years	34	35	23	20	-13.04	No
11	18 years	M	L	2 years	29	34	36	22	-38.89	No
12	2 years	M	L	1½ years	27	31	24	19	-20.83	No
13	6 years	M	L	2 years	35	42	19	16	-15.79	No
14	10 months	M	L	6 months	28	31	17	14	-17.65	No
15	6 months	M	L	3 months	32	39	25	21	-16	No
16	4 years	M	L	1 year	38	47	19	16	-15.79	No
17	10 years	M	L	2 years	31	37	22	12	-45.45	No
18	7 years	F	L	4 months	27	30	Nil	Nil		No
19	1½ years	F	L	3 months	29	35	10	7	-30	No
20	18 years	F	R	10 years	20	22	31	25	-19.35	No
21	9 years	M	L	5 years	19	23	25	22	-12	No
22	9 years	M	L	6 years	30	36	23	14	-39.13	No
23	17 years	M	L	6 months	23	28	22	15	-31.82	No
24	6 years	F	L	4 years	15	20	24	21	-12.5	No
25	11 years	F	L	4 years	25	28	41	35	14.63	No
26	2 years	M	L	1 year	30	37	19	13	-31.58	No
27	6 years	M	L	4 months	18	21	49	37	-24.49	No
28	5 years	M	R	4 year	31	37	14	10	-28.57	No
29	4 years	M	R	4 months	30	39	15	10	-33.33	No
30	8 years	M	L	6 months	25	30	26	21	-19.23	No
31	4 years	M	R	7 months	15	25	15	12	-20	No
32	13 years	M	L	5 years	22	26	25	15	-40	No
33	13 years	F	R	5 years	20	23	35	20	-42.86	No
34*	14.75 years	M	L	14 years 4 months	33	46	18.7	16.07	-14.08	No
35*	6.67 years	M	L	5 years 7 months	51	52	20.67	16.67	-19.35	No
36*	14.25 years	M	L	13 years 10 months	36	47	12.07	10.77	-10.8	No
37*	14.08 years	M	L	1 year 4 months	32	31	9.93	8.28	-14.02	No

\*Indicates data from the second institute

worsening of hydronephrosis and needed pyeloplasty.<sup>[21]</sup> Based on this, we took the 10% cut-off value as indicative of successful pyeloplasty in the current study.

Findings of this study support the primary hypothesis. We found that all patients who had a decrease in the APD in prone position by >10% as compared to supine position had better renal function after pyeloplasty. Therefore, we propose that a decrease of APD >10% in prone position is indicative of a successful pyeloplasty and no further radionuclide renogram is required. Interestingly, all these patients had no calyceal dilatation. This finding of absence of

calyceal dilatation in cases that have undergone a successful pyeloplasty is in accordance with the findings of other investigators who reported that calyceal dilatation resolves early and pelvic dilatation persists longer.<sup>[19]</sup> Recently, Lantz *et al.* have shown that prone position for renograms facilitates drainage and is a more accurate representation of postoperative outcome after pyeloplasty.<sup>[27]</sup>

Of the six patients who did not meet the above criteria, three (50%) were confirmed to have secondary PUJO with deteriorating renal function which required a second surgery. In the other three subjects (50%), only sluggish

**Table 2: Demographic data, ultrasound findings, and differential renal function in children who have either no change or increased APD from supine to prone position (zero or positive value at % change in APD)**

No.	Age in years	Sex	Side	Time since surgery	Pre surgery renal function (%)	Post surgery renal function (%)	APD supine in mm	APD prone in mm	Change in APD (%)	Calyceal dilatation
1	17	F	L	15 years	27	18	15	19	26.66	+
2	10	F	L	4 years	36	24	40	44	10	+
3	9	M	L	8 years	35	29	28	28	0	+
4*	1.0	F	L	4 months	51	49	10.0	13.07	40.91	No
5*	11.3	M	L	5 months	19	18	14.07	15.3	8.77	No
6*	1.92	M	L	2 years 9 months	41	50	10.7	11.33	5.92	No

\*Indicates data from the second institute

drainage was demonstrated on diuretic renogram without further deterioration in renal function. Hence, we propose that those who fail to achieve a decrease of APD >10% in prone position should be under close follow-up with ultrasonography. A further diuretic renogram is recommended to differentiate secondary obstruction from sluggish drainage pattern. Interestingly, all cases with deteriorating renal function [cases 1-3 in Table 2] were found to have co-existing calyceal dilatation, while those without deteriorating renal function [cases 4-6 in Table 2] did not show calyceal dilatation. Thus, in addition to increased APD in prone position, calyceal dilatation might be a useful sign with higher predictive value to identify dilated system with obstruction. The above statement/suggestion, however, needs to be validated with a larger sample size.

There are a number of limitations in this study. In the first institution, pre-pyeloplasty ultrasound findings were not available in the majority of patients. The timing of ultrasound postoperatively was variable, ranging from 3 months to 15 years after pyeloplasty. The operative details of many patients, with regard to whether they had undergone a reduction of pelvis or only a simple excision of the pelvi-ureteric junction, were not available. All cases were not operated by a single surgeon. The timing of postoperative renograms was highly variable. However, these limitations are a regular scenario in many developing countries where radionuclide studies are not easily available, patients are lost to follow-up, many get diagnosed late in life, and a single-center follow-up is uncommon due to variable health care practices. A patient who has undergone pyeloplasty in the past comes to seek medical advice for a non-renal pathology. An ultrasound examination is performed which detects hydronephrosis and the sonologist faces the dilemma of differentiating a dilated but non-obstructed system from a dilated and obstructed system. This dilemma is further compounded when the clinician gets a renogram done, but the differential renal function and the drainage curves cannot answer the question of differentiating a dilated non-obstructed system from an obstructed system, especially in the absence of pre pyeloplasty renograms. It is in these scenarios that a simple bedside ultrasound

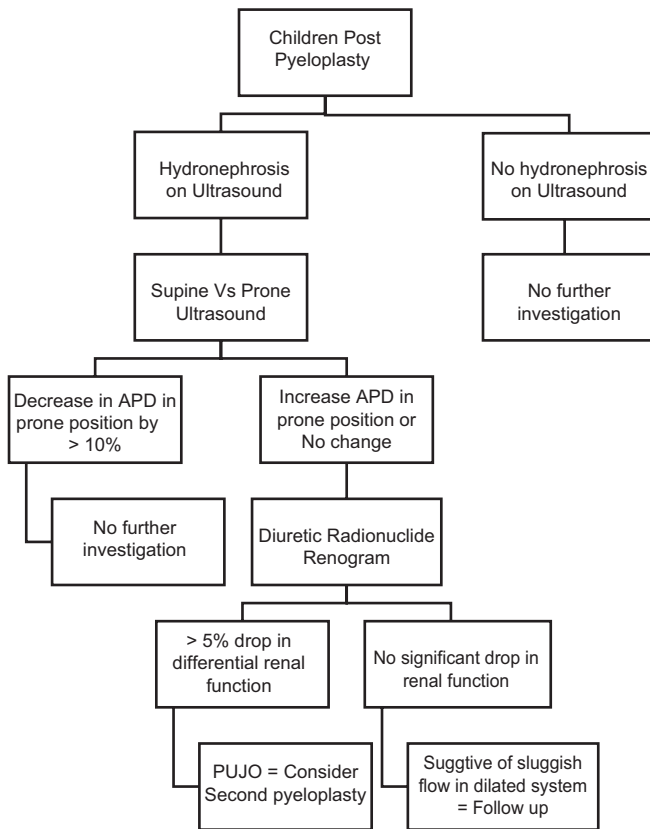
evaluation and measurement of APD of renal pelvis in supine and prone positions can be useful.

The aforementioned limitations were partially overcome by a collaborative study carried out in the second institution, which is a tertiary referral center for pediatric urology. In this latter institution, all subjects had pre-op ultrasound and diuretic renogram, as well as regular imaging follow-up post pyeloplasty, if there was persistent hydronephrosis. The surgical notes were also available and all subjects underwent standardized procedure of pyeloplasty by the same team of surgeons. There are also additional merits of this joint study. Firstly, the ultrasound examination was validated by clearly laid out protocol including patient preparation and scanning technique. Intra-observer and inter-observer variability was measured and proved that ultrasound technique was reliable and reproducible. Secondly, serial follow-up was available for patients with discrepancies in the first supine-prone ultrasound and diuretic renogram, which enhances a better understanding about the interpretation of the ultrasound findings.

A proposed algorithm for investigating children with previous PUJO and treated with pyeloplasty is given in Flow chart 1.

## Conclusion

We propose to use a simple ultrasound technique to measure the APD of renal pelvis in both supine and prone positions to differentiate a dilated non-obstructed system from a possibly obstructed system in children after pyeloplasty. A decrease in APD in prone position by >10% as compared to supine position indicates a successful pyeloplasty, thus obviating the need for any further investigation with diuretic renogram. In those patients who do not show a decrease in APD in prone position or even an increase in APD in prone position, diuretic radionuclide study is recommended. If our proposal is validated by larger-scale study, ultrasound may become a reliable diagnostic tool and lead to a new guideline for imaging children after pyeloplasty. This new protocol, hopefully, will help to alleviate parents' anxiety, saving time and money for further investigation, and reduce



**Flow chart 1:** Proposed algorithm for Evaluation of patients who have undergone pyeloplasty

the radiation exposure in this group of children by limiting redundant radionuclide studies.

## References

1. Capello SA, Kogan BA, Giorgi LJ Jr, Kaufman RP Jr. Prenatal ultrasound has led to earlier detection and repair of ureteropelvic junction obstruction. *J Urol* 2005;174:1425-8.
2. Seixas-Mikelus SA, Jenkins LC, Williot P, Greenfield SP. Pediatric pyeloplasty: Comparison of literature meta-analysis of laparoscopic and open techniques with open surgery at a single institution. *J Urol* 2009;182:2428-32.
3. Romao RL, Farhat WA, Pippi Salle JL, Braga LH, Figueroa V, Bägli DJ, *et al.* Early Post operative Ultrasound after open pyeloplasty in children with prenatal hydronephrosis helps identify low risk of recurrent obstruction. *J Urol* 2012;188:2347-53.
4. Babu R, Sai V. Pelvis/cortex ratio: An early marker of success following pyeloplasty in children. *J Pediatr Urol* 2010;6:473-6.
5. McAleer IM, Kaplan GW. Renal function before and after pyeloplasty: Does it improve? *J Urol* 1999;162:1041-4.
6. Conford PA, Rickwood AM. Functional results of pyeloplasty in patients with ante-natally diagnosed pelvi-ureteric junction obstruction. *Br J Urol* 1998;81:152-5.
7. Chertin B, Rolle U, Farkas A, Puri P. Does delaying pyeloplasty affect renal function in children with a prenatal diagnosis of pelvi-ureteric junction obstruction? *BJU Int* 2002;90:72-5.
8. Castagnetti M, Novara G, Benjamin F, Vezzú B, Rigamonti W, Artibani W. Scintigraphic renal function after unilateral pyeloplasty in children: A systematic review. *BJU Int* 2008;102:862-8.
9. Park K, Baek M, Cho SY, Choi H. Time course of hydronephrotic

changes following unilateral pyeloplasty. *J Pediatr Urol* 2013;9:779-83.

10. van den Hoek J, de Jong A, Scheepe J, van der Toorn F, Wolffebuttel K. Prolonged follow-up after paediatric pyeloplasty: Are repeat scans necessary? *BJU Int* 2007;100:1150-2.
11. Chertin B, Pollack A, Koulikov D, Rabinowitz R, Shen O, Hain D, *et al.* Does renal function remain stable after puberty in children with prenatal hydronephrosis and improved renal function after pyeloplasty? *J Urol* 2009;182(Suppl):1845-8.
12. Amling CL, O'Hara SM, Wiener JS, Schaeffer CS, King LR. Renal ultrasound changes after pyeloplasty in children with ureteropelvic junction obstruction: Long term outcome in 47 renal units. *J Urol* 1996;156:2020-4.
13. Cost NG, Prieto JC, Wilcox DT. Screening ultrasound in follow-up after pediatric pyeloplasty. *Urology* 2010;76:175-9.
14. Neste MG, du Cret RP, Finlay DE, Sane S, Gonzalez R, Boudreau RJ, *et al.* Postoperative diuresis renography and ultrasound in patients undergoing pyeloplasty. *Clin Nucl Med* 1993;18:872-6.
15. Kis E, Verebely T, Kövi R, Mátyus I. The role of ultrasound in the follow-up of postoperative changes after pyeloplasty. *Pediatr Radiol* 1998;28:247-9.
16. Almodhen F, Jednak R, Capolicchio JP, Eassa W, Brzezinski A, El-Sherbiny M. Is routine renography requires after pyeloplasty. *J Urol* 2010;184:1128-33.
17. Onen A. An alternative grading system to refine the criteria for severity of hydronephrosis and optimal treatment guidelines in neonates with primary UPJ-type hydronephrosis. *J Pediatr Urol* 2007;3:200-5.
18. Imaji R, Dewan PA. Calyx to parenchyma ratio in pelvi-ureteric junction obstruction. *BJU Int* 2002;89:73-7.
19. Cost GA, Merguerian PA, Cheerasarn SP, Shortliffe LM. Sonographic renal parenchymal and pelvicaliceal area: New quantitative parameters for renal sonographic follow-up. *J Urol* 1996;156:725-9.
20. Patti G, Menghini ML, Todini AR, Marrocco G, Calisti A. The role of the renal resistive index ratio in diagnosing obstruction and in the follow-up of children with unilateral obstruction. *BJU Int* 2000;85:308-12.
21. Brkljacić B, Kuzmić AC, Dmitrović R, Rados M, Vidjak V. Doppler sonographic renal resistance index and resistance index ratio in children and adolescents with unilateral hydronephrosis. *Eur Radiol* 2002;12:2747-51.
22. Egan SC, Stock JA, Hanna MK. Renal ultrasound changes after internal double-J stented pyeloplasty for ureteropelvic junction obstruction. *Tech Urol* 2001;7:276-80.
23. Sharma G, Sharma A, Maheshwari P. Predictive value of decreased renal pelvis anteroposterior diameter in prone position for prenatally detected hydronephrosis. *J Urol* 2012;187:1839-43.
24. Friedenberg RM, Harris RD. Excretory urography in the adult. In: Pollack HM, McClennan BL, Kenney PJ, Dyer R, editors. *Clinical Urography*. 2<sup>nd</sup> ed. Philadelphia: WB Saunders; 2000. p. 147-257.
25. Carrico CW, Zerlin JM. Sonographic measurement of renal length in children: Does the position of the patient matter? *Pediatr Radiol* 1996;26:553-5.
26. Berdon WE, Baker DH, Leonidas J. Advantages of prone positioning in gastrointestinal and genitourinary roentgenologic studies in infants and children. *Am J Roentgenol Radium Ther Nucl Med* 1968;103:444-55.
27. Lantz AG, Ordon M, Pace KT, Honey RJ. Prone versus supine lasix renal scan to assess surgical success after laparoscopic and robot-assisted pyeloplasty. *J Endourol* 2013;27:1431-4.

**Cite this article as:** Sharma G, Sharma A, Leung VY, Chu WC. Is decreased diameter of renal pelvis in prone position an indicator of successful pyeloplasty?. *Indian J Radiol Imaging* 2016;26:15-21.

**Source of Support:** Nil, **Conflict of Interest:** No.