

Role of dynamic CT perfusion study in evaluating various intracranial space-occupying lesions

Ravindra B Kamble, Peruvumba N Jayakumar¹, Ravishankar Shivashankar²

Departments of Radiology, Vikram Hospital, Bangalore, Karnataka, India, ¹Khoula Hospital, Muscat, Oman, ²University of Maryland Medical Center, Baltimore, Maryland, United States

Address for correspondence: Dr. Ravindra B Kamble, Vikram Hospital, Bangalore, Karnataka, India. E-mail: drravindra31@rediffmail.com

Abstract

Aims: Differentiating intracranial mass lesions on CT scan is challenging. The purpose of our study was to determine the perfusion parameters in various intracranial space-occupying lesions (ICSOL), differentiate benign and malignant lesions, and differentiate between grades of gliomas. **Materials and Methods:** We performed CT perfusion (CTP) in 64 patients, with age ranging from 17 to 68 years, having space-occupying lesions in brain and calculated relative cerebral blood flow (rCBF) and relative cerebral blood volume (rCBV). **Results:** We found significantly lower perfusion in low-grade gliomas as compared to high-grade tumors, lymphoma, and metastases. Similarly in infective lesions, TWT and abscesses showed significantly lower perfusion compared to TOT. In ring enhancing lesions, capsule of TWT showed significantly lower perfusion as compared to abscesses, TOT, and metastases. **Conclusion:** Thus, in conclusion, infective lesions can be differentiated from tumors like lymphomas, high-grade gliomas, or metastases based on perfusion parameters. The cut off value of rCBV 1.64 can be used to differentiate between low grade and high grade gliomas. However, depending only on perfusion parameters, differentiation between the tumors like lymphomas, high-grade gliomas, and metastases may not be possible.

Key words: Abscesses; CT perfusion; gliomas; metastasis; tuberculomas

Introduction

During the last few years, the role of magnetic resonance imaging (MRI) as a diagnostic tool in neuroradiology is well established. With advanced MR imaging techniques like perfusion, diffusion, and spectroscopy, it is now possible to differentiate between various intracranial lesions. MR perfusion studies are done to differentiate neoplastic focal lesions in brain from infective pathologies, to grade gliomas, and also to differentiate recurrent tumor from radiation necrosis.^[1-3] Use of proton MR spectroscopy in

grading tumors and characterizing the tumors is also well known.^[4,5]

But MR imaging is relatively costly, not readily available (predominantly in developing countries), and contraindicated in patients with implants and pacemakers. Thus, a good alternative to assess similar hemodynamic parameters of intracranial lesions is CT perfusion (CTP) study. There are very few CTP studies done to assess tumor vascularity and permeabilities.^[6,7] However, attempts are also made to validate and assess the accuracy of CTP.^[8]

In this study, we performed CTP in various intracranial focal lesions and studied their perfusion characters and tried to differentiate between them.

Materials and Methods

CTP was performed with dual-slice dynamic multi-detector CT scanner in 64 patients prior to surgery or stereotactic biopsy, of which 41 were males and 23 were females, with

Access this article online

Quick Response Code:



Website:
www.ijri.org

DOI:
10.4103/0971-3026.155866

age ranging from 17 to 68 years. Patients below 15 years, pregnant women, and very old patients with compromised renal functions were not included in this study. Informed consent was taken from all patients.

CTP imaging technique

In all patients, non-enhanced CT of brain was performed initially to identify the abnormality and then dynamic CTP studies were done on dual-slice multi-detector CT scanner (Siemens Somatom, Forchheim, Germany). The first slice was taken at the level of the lesion seen on initial plain CT study and the second slice was 10 mm craniad to the first. The slice thickness was 10 mm with a matrix size of 512 × 512. Fifty milliliters of 65% iodinated contrast agent was injected through a 16 G cannula into the antecubital vein using a pressure injector at a rate of 6 ml/s, simultaneously acquiring 40 images (1 image/s) at the area of interest after a delay time of 4 s.

The image data was transferred to a workstation with Siemens MV 300 post-processing software. Perfusion images were created with the reference of superior sagittal sinus away from the bone. Irregular region of interest ROIs were drawn on the lesions and 1-2 cm away from the lesion in perilesional area. In ring-enhancing lesions, the ROIs were drawn in the capsule and the center of lesion, and compared with normal-looking contralateral white matter. Cerebral hemodynamic parameters like relative cerebral blood flow (rCBF) and relative cerebral blood volume (rCBV) were quantitatively calculated.

Statistical analysis

Statistical analysis of variance (ANOVA) and the *post-hoc* procedure of Student–Newman–Keuls were performed between the groups. ANOVA was done to compare the means between the groups and a *P* value of less than 0.05 was considered significant.

Results

Totally 64 patients were included in the study. All patients had histological diagnosis either by biopsy or surgical resection. Of the 64 patients, lymphoma cases numbered 10, low-grade glioma 8 (5 astrocytoma and 3 oligodendroglioma), grade 3 anaplastic astrocytoma 14, glioblastoma multiforme 8, metastasis 6 (4 from lung, 1 from colon, and 1 unknown primary of epithelial origin), pyogenic abscess 6, and tuberculoma cases were 12 in number [7 tuberculomas without treatment (TWT) and 5 tuberculomas on antitubercular treatment (TOT) less than 2 months].

Perfusion parameters like rCBF and rCBV were calculated with ROI including the whole of the lesion and 1-2 cm in the periphery of the lesion. In ring-enhancing lesions, ROI was kept in the capsule and the center of lesion, and

compared with contralateral white matter. Color maps were assessed as shown in Figure 1 (rCBV). Perfusion parameters of various intracranial lesions are shown in Table 1. Table 2 shows the rCBF and rCBV of neoplastic lesions with statistically significant difference in rCBF (*P* < 0.002) and rCBV (*P* < 0.001) of low-grade gliomas from high-grade gliomas, lymphomas, and metastases. Table 3 shows the rCBF and rCBV of non-neoplastic tumors. There was statistically significant difference in rCBF (*P* < 0.002) and rCBV (*P* < 0.001) of TWT, TOT, and abscesses.

In ring-enhancing lesions (abscess *n* = 6, metastasis *n* = 3, TWT *n* = 7, and TOT *n* = 4), rCBF and rCBV of the capsule of metastases, abscess, and TOT showed significantly high perfusion compared to those of TWT (rCBF *P* < 0.013 and rCBV *P* < 0.002). rCBV of the center of abscess showed significantly low perfusion compared to those of metastasis, TOT, and TWT (rCBV *P* < 0.02), as shown in Table 4.

Table 1: rCBF and rCBV values (mean and standard deviation) of the lesion and at perilesional area

	Lesion		Perilesional area	
	rCBF	rCBV	rCBF	rCBV
Lymphoma	2.71±0.78	3.01±0.92	0.86±0.35	0.95±0.34
Low grade glioma	1.05±0.45	1.03±0.39	0.94±0.30	1.02±0.17
Grade3 glioma	3.12±1.64	3.01±1.57	1.03±0.51	1.04±0.34
GBM	2.60±0.79	2.61±0.61	0.75±0.20	0.91±0.18
Metastasis	4.77±4.66	4±3.33	1.19±0.98	1.11±0.61
TWT*	1.05±0.38	1.20±0.41	1.03±0.94	0.96±0.72
TOT**	3.24±1.15	3.07±0.70	1.29±1.20	0.98±0.56
Abscess	1.33±0.57	1.55±0.80	0.81±0.54	0.88±0.53

*Tuberculomas without treatment **Tuberculomas on treatment less than 2 months, GBM=Glioblastoma multiforme, rCBF=Relative cerebral blood flow, rCBV=Relative cerebral blood volume

Table 2: rCBF and rCBV of neoplastic lesions

Neoplastic lesions	Mean±SD	
	rCBF	rCBV
Low grade glioma	1.05±0.45*	1.03±0.39#
Grade 3 glioma	3.01±1.57	3.12±1.64
Glioblastoma multiforme (GBM)	2.61±0.61	2.60±0.79
High grade glioma (combined grade 3 and GBM)	2.93±1.39§	2.87±1.31§
Lymphoma	2.71±0.78	3.01±0.92
Metastasis	4.77±4.66	4.00±3.33

**P*<0.002, #*P*<0.001, §*P*<0.001, GBM=Glioblastoma multiforme, rCBF=Relative cerebral blood flow, rCBV=Relative cerebral blood volume, SD=Standard deviation

Table 3: rCBF and rCBV of non-neoplastic lesions

Non-neoplastic lesions	Mean±SD	
	rCBF	rCBV
Tuberculomas without treatment	1.05±0.38*	1.20±0.41#
Tuberculomas on treatment	3.24±1.15	3.07±0.70
Abscess	1.33±0.57*	1.55±0.80#

**P*<0.002, #*P*<0.001, rCBF=Relative cerebral blood flow, rCBV=Relative cerebral blood volume, SD=Standard deviation

Infected lesions like tuberculomas and abscesses showed significant difference in perfusion parameters from high-grade tumors, lymphomas, and metastases. There were differences in perfusion parameters of lymphomas, high-grade gliomas, and metastases, but these were not statistically significant. The rCBF and rCBV values from the periphery of the lesions showed no statistical significance in any of the groups. Approach to intracranial mass lesions by using CT perfusion is shown in the Figure 2.

Discussion

The most common primary neoplasm of brain is glioma.^[9] Other mass lesions that involve brain are non-glioma tumors, infective mass lesions, and metastases. Various imaging features of these focal mass lesions significantly overlap, making diagnosis on conventional MR imaging difficult. Advanced imaging techniques like perfusion and spectroscopy are useful in differentiating them.^[1,2,4,5] There are no large CTP studies done to differentiate these various

ICSOL, except a few studies that had been performed to assess the vascular permeability and perfusion in brain tumors and gliomas.^[6,7] CTP techniques are validated and can be compared with xenon CT and MR perfusion techniques, and have shown agreement with quantitative results.^[10,11]

We have done CTP in various neoplastic and non-neoplastic lesions, and have tried to differentiate between them, grade gliomas, and also differentiate various ring-enhancing lesions.

In our study, we found low perfusion in low-grade gliomas, TWT, and pyogenic abscesses. Aronen *et al.* observed that low-grade glioma had rCBV less than 1.5.^[2] Abscesses have low perfusion than high-grade tumors,^[12] and TWT also have lower perfusion as shown by Batra *et al.*^[13] Other infectious lesions like toxoplasmosis show lower perfusion compared to tumors like lymphoma.^[14] Similarly, cryptococcomas and paracoccidioidomycosis show lower perfusion.^[1]

Differentiation between low-grade and high-grade gliomas was done successfully with perfusion studies, as low-grade tumors show lower perfusion compared to high-grade tumors. We found statistically significant difference between rCBF and rCBV of low-grade glioma and high-grade glioma with an rCBV cut-off value of 1.64 to differentiate between them, which had a sensitivity of 86.36% and a specificity of 100%. Similarly, Aronen *et al.* found that none of the low-grade gliomas had rCBV more than 1.5.^[2]

Wide variation in rCBF and rCBV values between grade 3 astrocytomas and glioblastoma multiforme was reported by Cha *et al.*^[15] Similar results were obtained in the present

Table 4: rCBF and rCBV of ring enhancing lesions

	Capsule		Center	
	rCBF	rCBV	rCBF	rCBV
Abscess (n=6)	2.94±0.92	3.07±0.80	0.08±0.06	0.18±0.14 [ⓐ]
Metastases (n=3)	3.46±0.65	3.67±0.57	0.40±0.29	0.91±0.85
TWT (n=7)	1.79±0.87*	1.81±0.77 [#]	0.49±0.98	0.55±0.60
TOT (n=4)	4.43±1.89	4.20±1.21	1.39±1.18	1.73±1.23

TWT=Tuberculomas without treatment, TOT=Tuberculomas on treatment less than 2 months. *P<0.013, [#]P<0.002, [ⓐ]P<0.02, rCBF=Relative cerebral blood flow, rCBV=Relative cerebral blood volume

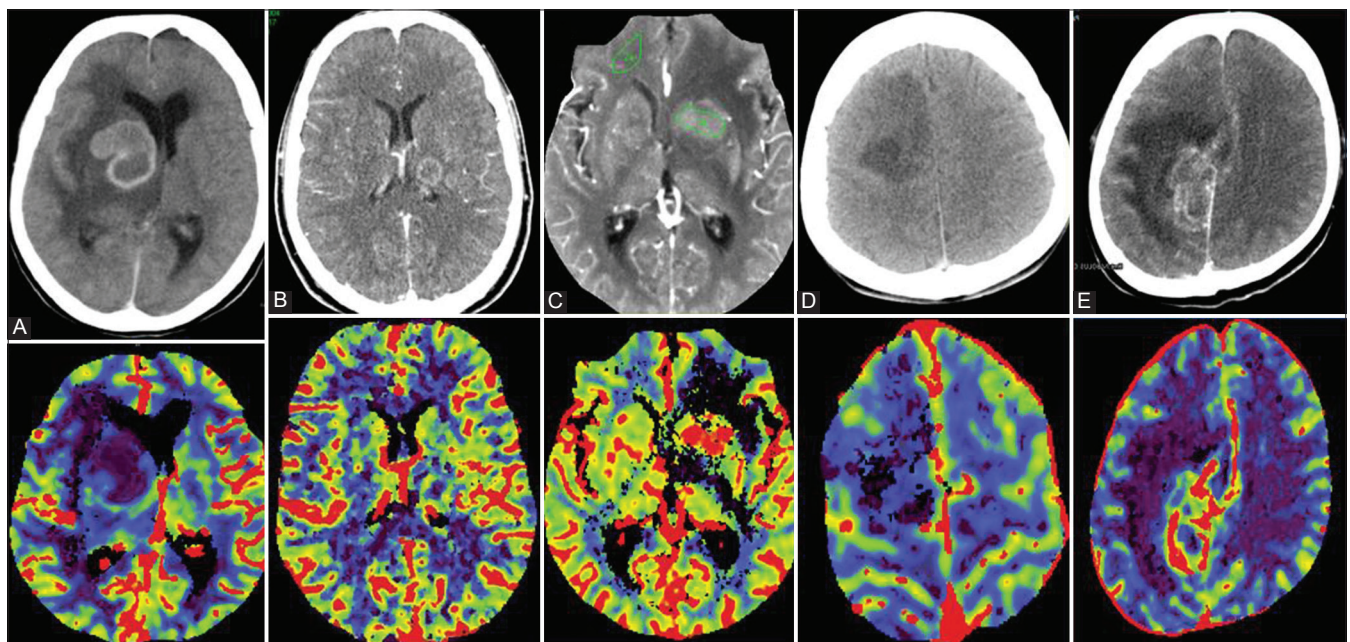


Figure 1(A-E): Upper column shows post contrast CT and lower column shows colored Perfusion maps. (A) Tuberculoma without treatment in right basal ganglia (low perfusion) (B) Tuberculoma on treatment in left thalamus (high perfusion) (C) Lymphoma in basal ganglia with ROI (high perfusion) (D) Low grade glioma in right frontal lobe (low perfusion) (E) High grade glioma (grade 3) in right parietal lobe (high perfusion)

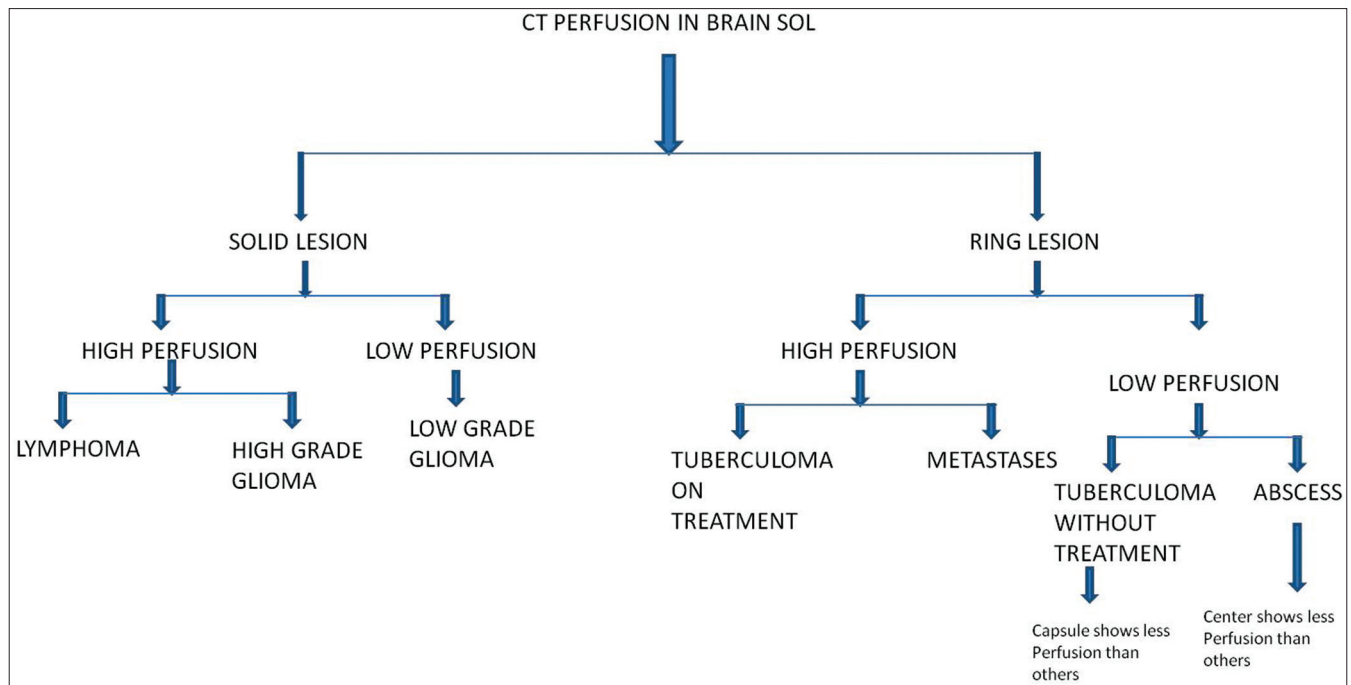


Figure 2: Flow chart showing approach to brain SOL by CT perfusion

study. In addition, we found low perfusion in glioblastoma multiforme compared to grade 3 astrocytoma. This may be because of tumor heterogeneity, necrosis, and vascular invasion.^[16]

We had three cases of oligodendrogliomas with low rCBF and rCBV. Cho *et al.* found low rCBV in two oligodendrogliomas and high value in one case.^[17] Other studies have found high perfusion.^[15] This discrepancy is possibly due to calcification and vascularity of tumor. Thus, CTP study can help in differentiating high-grade tumors from low-grade tumors.

Lymphomas also pose diagnostic dilemma, especially in immunocompromised patients where toxoplasmosis and lymphoma have similar imaging features on conventional imaging. Ernst *et al.* were able to differentiate between lymphoma and toxoplasmosis in AIDS patients where lymphoma showed higher perfusion compared to toxoplasmosis.^[14] In the present study, lymphoma had rCBF and rCBV ranging from 1.93 to 3.49 and from 2.09 to 3.93, respectively. These values are closer to high-grade gliomas. So, perfusion study alone is perhaps unable to differentiate between lymphoma and high-grade gliomas, though it can be differentiated from infective masses like tuberculomas and abscesses. Previous studies have also shown both increased^[14] and reduced perfusion in lymphomas.^[17]

Metastases showed a wide range in rCBF and rCBV values of 0.11-9.43 and 0.67-7.33, respectively. Two cases of metastases which showed very low rCBF and rCBV values were from

mucinous cystadenoma of lungs and epithelial malignancy of unknown primary. There was statistically significant difference in perfusion of metastases from low-grade gliomas, abscesses, and tuberculomas, but no statistical difference between high-grade gliomas and lymphomas. Similar results were observed by Cho *et al.*^[17]

Thus, based on perfusion parameters, it is possible to differentiate between tuberculomas, abscesses, and metastases. Few recent studies have shown high perfusion in ring-enhancing metastases compared to ring-enhancing tuberculomas.^[18]

Primary high-grade tumors had higher rCBV in peritumoral region compared to metastases, suggesting neovascularity and microscopic invasion of tumor cells in peritumoral region.^[19] However, in the present study, there was no statistical difference in rCBV of high-grade primary gliomas and metastases in the peritumoral region.

The rCBV of enhancing portion of abscesses was found to be low compared to gliomas, which was attributed to decreased neovascularity and high amount of mature collagen in abscess.^[12] Pyogenic abscesses showed very low rCBF and rCBV values in our study, similar to TWT.

We had studied the perfusion characters of TWT at the time of study and TOT for less than 2 months. TWT showed lower perfusion compared to TOT. TOT showed higher perfusion values, similar to high-grade intracranial tumors. Thus, it is difficult to differentiate TOT (less than 2 months) from

high-grade intracranial tumors like gliomas, depending on perfusion parameters alone. Similar findings were observed by Batra *et al.*^[13]

This low perfusion in drug-naïve tuberculoma could be due to arteritis in and around tuberculoma and high perfusion following treatment may be due to neovascularity.^[20,21]

In the present study, capsule of drug-naïve tuberculoma showed significantly low perfusion compared to TOT, abscesses, and metastases, and the center of abscesses showed significantly low perfusion compared to rest of them. Thus, CT perfusion can be a good aid in differentiating various ring-enhancing lesions.

The disadvantages of CT perfusion include use of iodinated contrast agents and radiation exposure.

In summary, CT perfusion can differentiate between low-grade gliomas and high-grade gliomas, lymphomas, and metastases, but CT perfusion alone cannot differentiate between low-grade gliomas, tuberculomas, and abscesses. It can also differentiate between various ring-enhancing lesions like metastases, abscesses, and tuberculomas. In the present study, we found higher perfusion in grade 3 gliomas compared to grade 4 gliomas. Contrary to previous reports, we found no statistical difference in the perfusion of peritumoral region between metastases and high-grade gliomas. An rCBV cut-off value of 1.64 can be used to differentiate between low-grade glioma and high-grade glioma, with a sensitivity of 86.36% and specificity of 100%.

Acknowledgement

Department of Neuroradiology, Neurology and Neurosurgery, NIMHANS, Bangalore.

References

- Floriano VH, Ferraz-Filho JR, Spotti AR, Tognola WA. Perfusion-weighted magnetic resonance imaging in the evaluation of focal neoplastic and infectious brain lesions. *Rev Bras Neurol* 2010;46:29-36.
- Aronen HJ, Gazit IE, Louis DN, Buchbinder BR, Pardo FS, Weisskoff RM, *et al.* Cerebral blood volume maps of gliomas: Comparison with tumor grade and histologic findings. *Radiology* 1994;191:41-51.
- Sugahara T, Korogi Y, Tomiguchi S, Shigematsu Y, Ikushima I, Kira T, *et al.* Posttherapeutic intraaxial brain tumor: The value of perfusion-sensitive contrast-enhanced MR imaging for differentiating tumor recurrence from nonneoplastic contrast-enhancing tissue. *AJNR Am J Neuroradiol* 2000;21:901-9.
- Poptani H, Gupta RK, Roy R, Pandey R, Jain VK, Chhabra DK. Characterization of intracranial mass lesions with *in vivo* proton MR spectroscopy. *AJNR Am J Neuroradiol* 1995;16:1593-603.
- Möller-Hartmann W, Herminghaus S, Krings T, Marquardt G, Lanfermann H, Pilatus U, *et al.* Clinical application of proton magnetic resonance spectroscopy in the diagnosis of intracranial mass lesions. *Neuroradiology* 2002;44:371-81.
- Roberts HC, Roberts TP, Lee TY, Dillon WP. Dynamic, contrast-enhanced ct of human brain tumors: Quantitative assessment of blood volume, blood flow, and microvascular permeability: Report of two cases. *AJNR Am J Neuroradiol* 2002;23:828-32.
- Eastwood JD, Provenzale JM. Cerebral blood flow, blood volume, and vascular permeability of cerebral glioma assessed with dynamic CT perfusion imaging. *Neuroradiology* 2003;45:373-6.
- Cenic A, Nabavi DG, Craen RA, Gelb AW, Lee TY. Dynamic CT measurement of cerebral blood flow: A validation study. *AJNR Am J Neuroradiol* 1999;20:63-73.
- Russel D, Rubinstein L. Tumors of central neuroepithelial origin. In: Rubenstein LJ, editor. *Pathology of Tumors of Nervous System*. Baltimore, Maryland: Williams and Wilkins; 1989. p. 83-350.
- Wintermark M, Thiran JP, Maeder P, Schnyder P, Meuli R. Simultaneous measurement of regional cerebral blood flow by perfusion CT and stable xenon CT: A validation study. *AJNR Am J Neuroradiol* 2001;22:905-14.
- Wintermark M, Reichhart M, Cuisenaire O, Maeder P, Thiran JP, Schnyder P, *et al.* Comparison of admission perfusion computed tomography and qualitative diffusion- and perfusion-weighted magnetic resonance imaging in acute stroke patients. *Stroke* 2002;33:2025-31.
- Holmes TM, Petrella JR, Provenzale JM. Distinction between cerebral abscesses and high-grade neoplasms by dynamic susceptibility contrast perfusion MRI. *AJR Am J Roentgenol* 2004;183:1247-52.
- Batra A, Tripathi RP. Perfusion magnetic resonance imaging in intracerebral parenchymal tuberculosis: Preliminary findings. *J Comput Assist Tomogr* 2003;27:882-8.
- Ernst TM, Chang L, Witt MD, Aronow HA, Cornford ME, Walot I, *et al.* Cerebral toxoplasmosis and lymphoma in AIDS: Perfusion MR imaging experience in 13 patients. *Radiology* 1998;208:663-9.
- Cha S, Knopp EA, Johnson G, Wetzel SG, Litt AW, Zagzag D. Intracranial mass lesions: Dynamic contrast-enhanced susceptibility-weighted echo-planar perfusion MR imaging. *Radiology* 2002;223:11-29.
- Sugahara M, Korogi K, Kochi M, Ikushima I, Hirai T, Okuda T, *et al.* Correlation of MR imaging-determined cerebral blood volume maps with histologic and angiographic determination of vascularity of gliomas. *AJR Am J Roentgenol* 1998;171:1479-86.
- Cho SK, Na DG, Ryoo JW, Roh HG, Moon CH, Byun HS, *et al.* Perfusion MR imaging: Clinical utility for the differential diagnosis of various brain tumors. *Korean J Radiol* 2002;3:171-9.
- Sankhe S, Baheti A, Ihare A, Mathur S, Dabhade P, Sarode A. Perfusion magnetic resonance imaging characteristics of intracerebral tuberculomas and its role in differentiating tuberculomas from metastases. *Acta Radiol* 2013;54:307-12.
- Law Y, Cha S, Knopp EA, Johnson G, Arnett J, Litt AW. High grade gliomas and solitary metastases: Differentiation by using perfusion and proton spectroscopic MR imaging. *Radiology* 2002;222:715-21.
- Jenkins JR, Al-Kawi MZ, Bashir R. Dynamic computed tomography of cerebral parenchymal tuberculomata. *Neuroradiology* 1987;29:523-9.
- Dastur DK, Dave UP. Ultrastructural Basis of the Vasculopathy In and Around Brain Tuberculomas. Possible significance of altered basement membrane. *Am J Pathol* 1977;89:35-50.

Cite this article as: Kamble RB, Jayakumar PN, Shivashankar R. Role of dynamic CT perfusion study in evaluating various intracranial space-occupying lesions. *Indian J Radiol Imaging* 2015;25:162-6.

Source of Support: Nil, **Conflict of Interest:** None declared.