Article published online: 2021-07-30

Imaging in neuroblastoma: An update

Seema A Kembhavi, Sneha Shah[1], Venkatesh Rangarajan[1], Sajid Qureshi[2], Palak Popat, Purna Kurkure[3]

Departments of Radiodiagnosis, [1]Bio-imaging, [2]Surgery, and [3]Medical Oncology, Tata Memorial Centre, Mumbai, Maharashtra, India

Correspondence: Dr. Seema A Kembhavi, Department of Radiodiagnosis, Tata Memorial Centre, Parel, Mumbai - 400 012, Maharashtra, India. E-mail: seema.kembhavi@gmail.com

Abstract

Neuroblastoma is the third common tumor in children. Imaging plays an important role in the diagnosis, staging, treatment planning, response evaluation and in follow-up of a case of Neuroblastoma. The International Neuroblastoma Risk Group task force has recently introduced an imaging-based staging system and laid down guidelines for uniform reporting of imaging studies. This review is an update on imaging in neuroblastoma, with emphasis on these guidelines.

Key words: Image-defined risk factor; international neuroblastoma risk group staging system; metaiodobenzylguanidine; neuroblastoma

Introduction

Neuroblastoma (NB) is the most common extracranial solid tumor in children.[1] It has a perplexing behavior with varied range of presentation and outcome. Some NBs can show spontaneous regression (without any therapy), while some cannot be salvaged even with aggressive therapies including bone marrow transplant (BMT). In order to administer the right treatment to such variedly behaving tumor, NBs need to be assigned a risk status. The risk status is dependent on age of the patient, stage of the disease, histopathology, and multiple biological factors. There has been a recent update in the staging and risk stratification of NB, published in the year 2009, by the International Neuroblastoma Risk Group (INRG) task force.[2] This new staging system is based on imaging and is called the INRG Staging System (INRGSS). The task force has also proposed guidelines to standardize the use of various imaging techniques and reporting.[1,3,4] In this article, we will review the role of imaging in NB, with emphasis on INRGSS and these new guidelines.

Access this article online	
Quick Response Code:	Website: www.ijri.org
	DOI: 10.4103/0971-3026.155844

Background Information

NB arises from the primordial neural crest cells that form the sympathetic nervous system. The exact etiology of this disease is not yet known. It usually occurs sporadically, only 1-2% of the cases being familial.[5,6] The most common site of NB is the adrenal gland (40% of the tumors), followed by the paraspinal ganglia in the retroperitoneum (25%), mediastinum (15%), neck (5%), and pelvis (3%).[7] Approximately 60-70% of the cases are metastatic at presentation.[7] The median age at diagnosis is 22 months.[8] About 81.5% cases are diagnosed by the age of 4 years and another 15% by the age of 9 years.[9]

A child with NB can present with symptoms, which may be in the form of a lump, or its related mass effects like lower limb weakness due to compression of spinal cord or difficulty in breathing due to an enlarged liver. Symptoms can also be caused by metastatic disease, e.g., skeletal metastases leading to bony pain, orbital wall metastases presenting as Panda sign or Raccoon eyes (due to orbital ecchymoses causing darkening of periorbital tissues).[8] Less than 2% of the patients present with paraneoplastic syndrome like profuse diarrhea (due to secretion of vasoactive intestinal peptide) or opsoclonus-myoclonus-ataxia.[8]

The treatment and outcome of NB is dependent on risk assessment and stage of the disease. For a long time, the International Neuroblastoma Staging System (INSS) [Table 1] has been routinely used for staging.[10] This is a post-surgical staging system; hence, it

Table 1: International neuroblastoma staging system

Stage	Description
1	Localized tumor with gross total resection with or without microscopic residual disease, and identifiable bilateral lymph nodes negative microscopically
2A	Unilateral tumor with incomplete resection, and Identifiable bilateral lymph nodes negative microscopically
2B	Unilateral tumor with complete or incomplete resection, and Microscopically positive ipsilateral nodes but contralateral regional lymph nodes negative
3	Crosses midline with or without positive regional lymph nodes, or Unilateral tumor with positive contralateral regional lymph nodes. Midline tumor with positive bilateral regional lymph nodes
4	Metastatic disease to distant lymph nodes, bone, bone marrow, liver and/or other organs (except as in 4S)
4S	Stage 1 or 2 primary tumor with metastases limited to liver, skin, and/or bone marrow (with <10% tumor) in a child less than one year of age

Source: Modified from reference 10

is dependent on the surgical skill set and the infrastructure available at a given hospital. Using this system, the same tumor can be labeled as stage I in a center with good surgical expertise or stage III in another center where such facilities are not available. Hence, INSS can neither be uniformly applied across the globe nor be used in pre-treatment risk stratification.[3] In 2004, NB investigators from the major cooperative groups from North America [Childrens' Oncology Group (COG)], Europe [Society of Pediatric Oncology European Neuroblastoma Network (SIOPEN)], Australia–New-Zealand, Germany, Japan, and China formed the INRG task force and proposed a pre-treatment staging system called the INRGSS.[3] This staging is primarily dependent on cross-sectional imaging, metaiodobenzylguanidine (MIBG) scan, and bone marrow biopsy results, and is discussed further in detail. The risk assessment is further dependent on the INRG stage, age of the patient and biological factors; it segregates the patients into very low, low, intermediate, and high-risk categories. Assessment of risk is not only essential for planning of appropriate treatment but also helps in predicting the outcome of patients - the 5-year event-free survival is more than 85% in very low-risk disease and less than 50% in high-risk disease.[2] INRGSS is not meant to replace INSS but to be used in addition for pre-surgical risk stratification.

Detection and Diagnosis

Screening

Like most cancers, detection of the disease at an early stage has a bearing on the outcome of NB. In addition, the outcome is likely to be even better if the child is younger at the time of diagnosis (less than 18 months). Hence, trials for screening of NB using urinary catecholamine levels were initiated many years ago, Japan being the pioneering country for the same.[11-13] However, it was found that the NBs detected by this method had good biologic features and probably would have undergone spontaneous regression without manifesting clinically.[5] Two subsequent prospective screening studies showed that screening for NB did not reduce mortality.[14,15] Hence, currently, screening for NB is not routinely advocated.[5]

Detection

Neuroblastic tumors are usually detected in a symptomatic child, but may sometimes be seen incidentally. For example, one may detect such a tumor on a chest radiograph ordered in a child with suspected pneumonitis, when there is posterior mediastinal widening caused by a mass. In a child presenting with a palpable abdominal mass (most common site), the investigation of choice is ultrasound (USG). On USG, NBs are seen as heterogeneous solid masses that often show calcification. When in the adrenal, the mass displaces the kidney inferiorly. The neighboring vessels are also generally encased, stretched, and displaced, rather than infiltrated. There can be associated adenopathy and/or liver lesions. Once a provisional diagnosis of NB is made, a cross-sectional imaging study, computed tomography (CT) or magnetic resonance imaging (MRI), needs to be performed. There is no clear evidence as to which modality is superior, as each comes with its own inherent pros and cons.[4] MRI may be preferred as it is free of ionizing radiation and superior in evaluation of intraspinal and marrow involvement, while CT scan is more widely available and a rapid technique (can avoid sedation) which is superior for detection of calcification within the tumor.

On CT or MRI scan, NB is often seen as a large, lobulated, heterogeneous solid mass displacing the adjacent organs [Figure 1]. When NB occurs in the adrenal, the most important differential diagnosis is Wilms' tumor (WT). The presence of stippled calcification favors NB and is seen in 85% of abdominal NBs.[8] While NB is likely to displace the kidney inferiorly, WT arises from the kidney. NB tends to be a mass crossing the midline, encasing and displacing vessels, rather than infiltrating them, while a tumor thrombus in the renal vein or inferior vena cava is highly predictive for WT.[16] Conglomerate nodal masses with calcification or a paravertebral mass with intra-spinal extension are suggestive of NB. The other differential diagnosis is that of an adrenocortical carcinoma (ACC), which is rather rare tumor having bimodal distribution with one peak in the first decade of life. It may be difficult to distinguish ACC from NB on imaging; however, ACC often secretes steroids leading to clinical presentation with virilization, Cushing's syndrome, etc.[17]

At sites other than the abdomen, the typical location of the mass along the sympathetic chain, presence of calcification, and/or intra-spinal extension can help in diagnosis. Cervical NB arises in the cervical ganglia of the sympathetic chain that lie postero-medial to the carotid sheath. Cervico-thoracic NB arises from the stellate ganglion that lies at the junction of

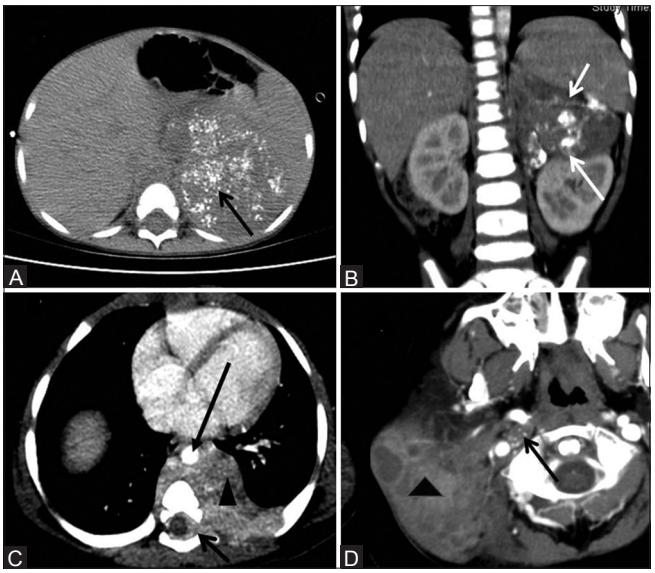

Figure 1 (A-D): Common locations of NBs. Image (A and B) show adrenal NBs- a left supra-renal mass with typical stippled calcifications (arrow in A) and a mass with calcifications (arrow in B) displacing the left kidney inferiorly. A posterior mediastinal mass that crosses the midline and encases the descending aorta (long arrow) is seen in image (C). The short arrow points towards the intraspinal extension through a neural foramen, which is often seen in NB arising from paravertebral sympathetic chain. Image D reveals a tiny mass with calcific foci postero-medial to the carotid sheath (arrow), corresponding to the location of superior cervical ganglion. Associated large nodal mass is seen lateral to the carotid sheath (arrow head)

the vertebral and subclavian arteries. Mediastinal NB arises in the paravertebral sympathetic chains that lie within the posterior mediastinum. In the retroperitoneum (non-adrenal abdominal), the tumor lies in the paravertebral gutters. A few case reports of metastatic NB without an identifiable primary also exist in the literature.[18]

Diagnosis

Imaging cannot reliably differentiate NB from other neuroblastic tumors like ganglioneuroma or ganglioneuroblastoma that occur in the same locations, though ganglioneuroma tends to be more homogeneous.[19] Histopathological confirmation is mandatory in a case of suspected NB and can be obtained from a biopsy of the primary tumor. A biopsy can, however, be avoided if bone marrow aspiration shows tumor cells in a patient with elevated urine or serum catecholamine levels.[3]

Staging

Bone is the most common site of metastasis in NB, producing marrow or cortical lesions. Though CT scan and MRI can detect skeletal metastases, imaging investigation of choice is an MIBG scan and has been discussed further. Non-regional nodal involvement also constitutes metastatic disease and a recent study has shown that patients with "nodes only" metastases have a better outcome.[20] The other common sites of metastases are liver and skin, especially in infants. Liver involvement in NB can be in the form of focal lesions or diffuse infiltration causing hepatomegaly and respiratory distress. Lung and central nervous system metastases are extremely rare and show non-specific and varied appearances.[3]

International Neuroblastoma Risk Group Staging System

The INRGSS broadly classifies NB into localized and metastatic cases.[3] The localized disease is further divided into L1 and L2 stages, depending upon the absence or presence of one or more image-defined risk factors (IDRFs, described later), respectively. The type of metastases and the age of the child define the metastatic stages. The presence of special sites of metastases - only liver, skin, or less than 10% of the sampled bone marrow in a child less than 547 days of age (18 months) - classifies the disease as stage MS (the bone marrow involvement should not be appreciable on MIBG scan), while all other types of metastases like the bone/bone marrow or non-regional nodes make the disease stage M. This has been summarized in Table 2.

In INRGSS, multifocal tumor (distinct primaries) needs to be staged according to the site of larger disease. Disease extending into ipsilateral contiguous body compartments is called locoregional disease and constitutes L2 disease. Ascites and pleural effusion do not categorize as metastatic disease, but need to be mentioned in the report.

There are a few major differences between INSS and INRGSS. The locoregional disease is divided into three stages in INSS and into two stages in INRGSS. In INSS, extension across the midline makes the disease stage III. In INRGSS, there is no specific importance for midline and even ipsilateral disease can be L2 depending upon the involvement of vital structures. Also, the nodes are categorized as regional or non-regional in INRGSS, rather than ipsilateral, contralateral, or distant. Non-regional nodes include non-contiguous nodal involvement in different body compartments, e.g. abdominal tumor with supraclavicular disease (M stage), while the presence of lower mediastinal nodes in upper abdominal tumor constitutes loco-regional disease (L2).

Local Staging and IDRFs

Twenty IDRFs have been identified based on the known locations of the primary tumor and the adjacent vital structures [Table 3 and Figures 2-5].[3] The use of standardized terminology to assess the status of the adjacent vital organ, as listed in Table 4, is recommended by the INRG Imaging Committee - this should help in reducing inter-observer variability for reporting of neuroblastic tumors.[4]

Table 2: International neuroblastoma risk group staging system[3]

Stage	Description
L1	Localized tumor not involving vital structures as defined by the list of IDRFs and confined to one body compartment
L2	Loco regional* tumor with presence of one or more IDRF
M	Distant metastatic disease (except stage MS)
MS	Metastatic disease in children younger than 547 days and metastases confined to skin, liver and/or bone marrow (<10% of total nucleated cells on smears or biopsy)

Source: Reference 3. IDRF: Image defined risk factor. *Loco-regional means two ipsilateral continuous body compartments

Table 3: Image defined risk factors[3]

Anatomic region	Description of IDRF
Multiple body compartments	Ipsilateral tumor extension within two body compartments (i.e, neck and chest, chest and abdomen, or abdomen and pelvis)
Neck [Figure 2A]	Tumor encasing carotid artery, vertebral artery, and/or internal jugular vein Tumor extending to skull base Tumor compressing trachea
Cervico-thoracic junction	Tumor encasing brachial plexus roots Tumor encasing subclavian vessels, vertebral artery, and/or carotid artery Tumor compressing trachea
Thorax [Figure 2B]	Tumor encasing aorta and/or major branches Tumor compressing trachea and/or principal bronchi Lower mediastinal tumor infiltrating costovertebral junction between T9 and T12 vertebral levels (because of risk of injury to anterior spinal artery)
Thoraco-abdominal	Tumor encasing aorta and/or vena cava
Abdomen and pelvis [Figures 3 and 4]	Tumor infiltrating porta hepatis and/or hepatoduodenal ligament Tumor encasing branches of superior mesenteric artery at mesenteric root Tumor encasing origin of celiac axis and/or origin of superior mesenteric artery Tumor invading one or both renal pedicles Tumor encasing aorta and/or vena cava Tumor encasing iliac vessels Pelvic tumor crossing sciatic notch
Intraspinal tumor extension [Figure 5]	Intraspinal tumor extension (whatever the location) provided that more than one-third of spinal canal in axial plane is invaded, the perimedullary leptomeningeal spaces are not visible, or the spinal cord signal intensity is abnormal
Infiltration of adjacent Organs and structures	Pericardium, diaphragm, kidney, liver, duodenopancreatic block, and Mesentery

Source: Reference 3. IDRF: Image defined risk factor

Metastatic Disease Evaluation

The routine metastatic workup of NB involves tests to identify the common sites of metastases mentioned above. Bilateral bone marrow aspiration and biopsies are mandatory for assessing the involvement of marrow. In addition, Iodine-123 MIBG scintigraphy is also essential for evaluating metastatic disease to marrow and other sites. This scan should ideally be obtained prior to tumor excision.[3]

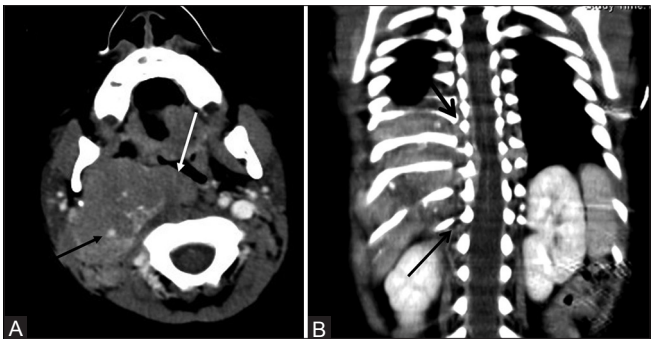

Figure 2 (A and B): Cervical and thoracic IDRFs. Image A is an axial CT section of upper neck that reveals a large right sided mass compressing the airway (white arrow) and encasing the carotid artery (black arrow). The IJV is compressed and not well visualized. Image B is a coronal reformatted section of thoracic CT scan that shows a right-sided mass involving the costovertebral junctions between T9 and T12 vertebral level

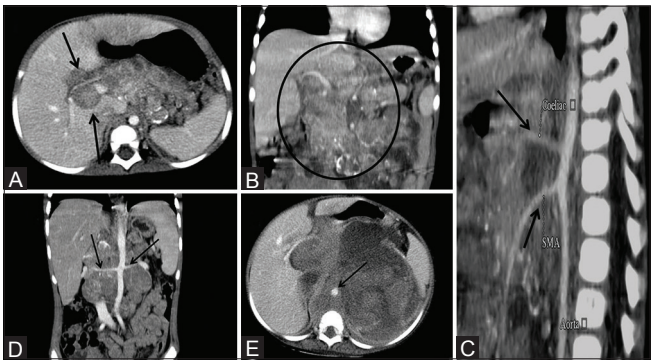

Figure 3 (A-E): This composite image shows the IDRFs for abdominal NB: Involvement of porta-hepatis (arrows in A), root of mesentery and duodeno-pancreatic block (circle in B), origin of coeliac and superior mesenteric artery (arrows in C), renal pedicles (arrows in D) and the descending aorta (arrow in E)

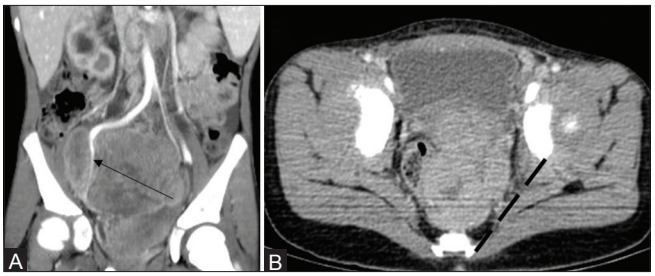

Figure 4 (A and B): IDRFs for pelvic NBs. Image A shows a pelvic NB encasing the right common iliac artery (arrow) in this coronal reformat (L2 disease) and the image B shows another pelvic NB that does not cross the sciatic notch (dotted line) (L1 disease)

MIBG scan

MIBG is an aralkylguanidine with a structure similar to norepinephrine (NE) and, therefore, is taken up and stored in tumors of neuroendocrine origin. MIBG uptake is seen in 90-95% of patients with NB (including the primary sites, bone, bone marrow, and lymph nodes).[21] MIBG is labeled with either Iodine-123 (I-123) or Iodine-131 (I-131). I-123 labeled MIBG is preferred over I-131 as it can be

Table 4: Suggested use of terminology for local disease evaluation by the INRG imaging committee[4]

Terminology	Definition	Comment
Multiple body compartment	Involvement of two or more contiguous body compartments	It is an IDRF by itself, even if no other IDRF is present in either compartment (L2 status)
Multifocal disease	Non-contiguous disease in two or more compartments	Not an IDRF, but should be recorded
Separation	Visible fat plane between the tumor and adjacent vital structure	L1 status
Contact	Loss of fat plane between the tumor and adjacent vital structure; for an artery the angle of contact <180′ and for a vein, flattening of shape but lumen visible	L1 status (except for renal arteries)
Compression (used only for airways)	Reduction in short axis of the lumen	L2 status
Encasement	Tumor encases vital structure; for an artery >180′ of contact and for a vein no visible lumen seen	L2 status
Infiltration	For vital structures other than vessels	L2 status
Invasion	Not a well defined term; can be used for spinal canal extension	L2 status
Spinal canal involvement	More than one-third of the spinal canal in the axial plane is invaded or the leptomeningeal fluid space is not visible, or the spinal cord shows abnormal signal intensity on MRI	L2 status

Source: Reference 4. INRG: International neuroblastoma risk group, IDRF: Image defined risk factor

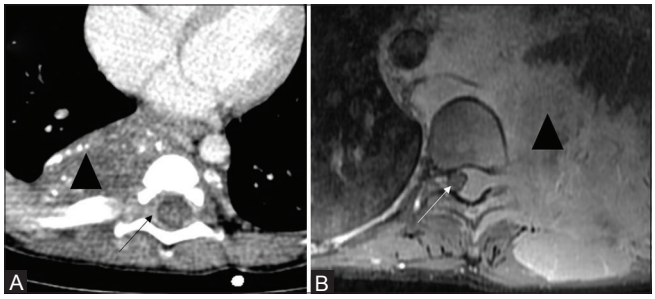

Figure 5 (A and B): Mere intraspinal extension is not an IDRF. Image A is an axial CT section showing a right paravertebral mass with intraspinal extension (arrow) that occupies less than 1/3rd of the spinal canal (L1) while Image B is an axial post-contrast MRI that reveals a left paravertebral mass that extends into the spinal canal and displaces the cord to the right side (arrow) with obliteration of lepto-meningeal space (L2)

administered in larger doses resulting in a better tumor-to-background ratio.[22] However, I-123 is not universally manufactured, and hence, I-131 MIBG is used in smaller doses for diagnostic purposes. The INRG task force has provided guidelines for MIBG scan technique, patient preparation, drug dosage, image acquisition, and analysis to facilitate high-quality studies and to achieve consistency in interpretation.[1]

Since MIBG is excreted in the urine, the urinary bladder and urinary tract show intense activity. MIBG is normally taken up mainly by the liver; smaller uptake is described in spleen, lungs, salivary glands, thyroid, skeletal muscles, and myocardium [Figure 6A]. Normal adrenal glands are usually not seen, but faint uptake may be visible 48-72 h after injection in up to 15% of cases.[22] Primary tumor with high MIBG avidity appears as a region of increased tracer concentration. Single Photon Emission Computed Tomography (SPECT) may be done to improve the diagnostic accuracy. Use of SPECT-CT allows further improvement in localization because of additional CT component and, thus, increases the specificity.[23,24]

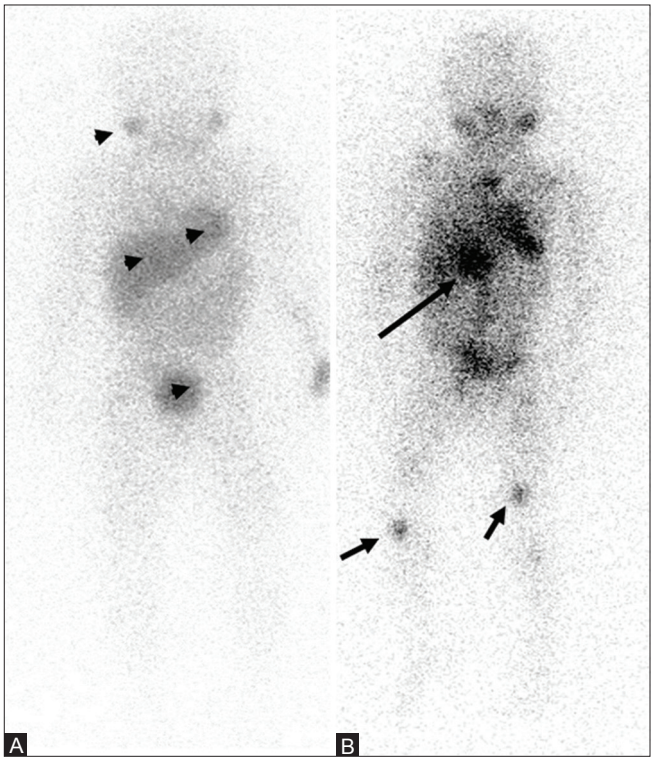

Figure 6 (A and B): 131I MIBG scan shows areas of physiological uptake in image A (arrowheads)- parotid glands, heart, liver and bladder. Image B reveals uptake in right suprarenal mass (long arrow) with metastases to distal ends of both femori (short arrows)

One unequivocal MIBG-positive lesion at a distant site is sufficient to define metastatic disease. However, an equivocal lesion requires confirmation by another imaging modality (plain radiographs, and if negative, MRI) and/or biopsy.[3] The INRG task force recommends the use of semi-quantitative methods for assessing the tumor burden and response on an MIBG scan. Various scoring methods have been described which basically divide the body into a different number of segments and assign a score depending upon the number of sites involved and

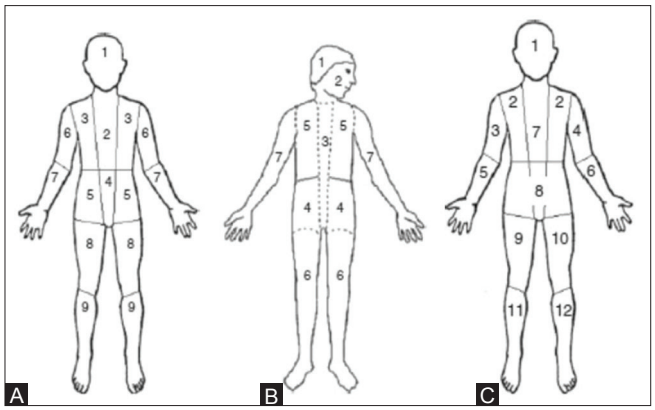

Figure 7 (A-C): Reproduced with permission from Matthay K (reference 1). This image compares the commonly used MIBG scoring systems. Image A shows the Curie method in which the skeleton is divided into nine segments and a tenth sector is added for soft tissue involvement. Image B shows the Frappaz method in which skeleton is divided into seven segments and soft tissue involvement is noted separately. Image C shows the SIOPEN method that divides the skeleton into 12 segments

the intensity of uptake [Figure 7]. For example, in the Curie method, the skeleton is divided into nine segments and a tenth sector is added for soft tissue involvement.[25] The extension score is graded as zero for no sites per segment, one for one site per segment, two for more than one site per segment, and three for > 50% of the segment or diffuse involvement. The intensity score is graded as zero for no uptake, one for doubtful uptake, two for definite uptake less than that of liver, and three for intense uptake greater than that of liver. The scoring systems show good inter- and intra-observer correlation, and are also reproducible while evaluating patients with relapse and on MIBG therapy.[26]

Bone scan

Technetium-^{99m} bone scintigraphy is required if the primary tumor does not show MIBG avidity or the tumor has been excised. The metastatic cortical lesions are generally seen as focal hot spots. Blurring at the growth plate with extension of tracer uptake into the metaphyseal region is suggestive of metastatic involvement.[27] An isolated bone uptake should be confirmed by another imaging modality and/or biopsy.[3]

PET/CT

The role of 18-fluorodeoxyglucose (FDG) PET/CT is not well defined. Early reports confirmed that NBs are FDG avid.[28] Sharp *et al*. have shown that PET is superior in depicting localized stage disease, in tumors that weakly accumulate MIBG, and at major decision points during therapy; however, MIBG is superior in the evaluation of metastatic disease.[29] PET scan may be useful in discrepant or inconclusive findings on MIBG scintigraphy/SPECT and morphological imaging.[30] The routine use of FDG PET/CT as a substitute to MIBG is not advocated by the INRG task force.[19] However, it should be noted that I-123 MIBG as recommended by the task force is not universally available and I-131 MIBG is not as sensitive as I-123 MIBG as it is limited by the dose that can be administered. The role of PET/CT needs to be evaluated further in such a clinical scenario, bearing in mind that PET/CT may not be suitable for response evaluation in the bone due to reactive changes.

Somatostatin receptor scintigraphy

Some somatostatin receptors are expressed in the NB tissue.[31,32] This can be explored to detect NB using radiolabeled somatostatin analogues like indium-111 labeled octreotide, pentreotide, and lanreotide. ^{99m}Tc or ^{68}Ga labeled somatostatin receptor imaging agents are now used in SPECT or PET studies respectively. There is some evidence that NBs expressing somatostatin receptors are low-risk disease and have better prognosis.[33,34] SRS may be considered in MIBG-negative tumor.[4]

Table 5 summarizes the investigations in NB.

Response Evaluation

Response assessment to neo-adjuvant therapy is done using cross-sectional imaging for local disease and also with MIBG in high-risk/metastatic disease. The International Neuroblastoma Response Evaluation criteria are shown in Table 6. According to these criteria, the evaluation of response at local site is done using volume calculations and that at metastatic sites should be done using the MIBG scoring systems. Recent evidence suggests that response to therapy in patients with high-risk NB has prognostic significance.[35] Though IDRFs may continue to be present in the post-chemotherapy scan, they do not represent contraindication for surgery.

Surveillance

All patients treated for NB require clinical follow-up along with urinary catecholamine levels and imaging.[8] There is no strict guideline for imaging-based surveillance after the end of therapy from the task force. The choice of imaging often depends on the location, stage, and risk. In general, patients with abdominal or pelvic disease or those with stage MS are monitored with USG while others may require CT or MRI. The suggested frequency of investigations in localized stage favorable biology disease is about 3 monthly in the first year, followed by 4 monthly in the second year and 6 monthly from the third year onwards. It is more intensive in the high-risk disease, where in addition to cross-sectional imaging, MIBG scan also needs to be performed every 3 monthly for 2 years and 4 monthly in the third year. Bone marrow aspiration and biopsy are usually performed if relapse is suspected.[21]

Table 5: Imaging work-up in a case of NB[3,4]

Mandatory	Problem-solving	Needs further evaluation
CT/MRI (evaluation of loco-regional disease extent)	Bone scan (MIBG non-avid tumor or primary has been excised)	Somatostatin receptor studies
123-I MIBG scan (to look for avidity in the primary and screen for metastatic disease- ideally done prior to excision of primary)	Radiographs/MRI (equivocal focus of metastatic disease on MIBG or bone scan)	Whole body MRI (radiation free tool for marrow metastases)
Chest radiograph	FDG-PET/CT (MIBG non-avid tumors, equivocal lesions especially in soft tissues)	Other radionuclides
	CT chest: For suspected pleural or pulmonary metastases	

Source: Reference 3,4. NB: Neuroblastoma, MIBG: Metaiodobenzylguanidine, MRI: Magnetic resonance imaging, FDG PET-CT: Fluorodeoxyglucose PET-CT

Table 6: International neuroblastoma response evaluation criteria[10]

Response	Primary tumor	Metastatic disease
Complete response	No tumour	No tumour, normal catecholamines
Very good partial response	Decreased by 90%-99%	No tumour, normal catecholamines, Improved bone scan
Partial response	Decreased by >50%	All sites decreased by>50%, no>1 positive bone marrow sites
Mixed response	No new lesions; >50% decrease of any measurable lesion (primary or metastatic) with 50% decrease in any other; 25% increase in any existing lesion	
No response	No new lesions, <50% decrease but <25% increase in any existing lesion	
Progressive disease	Any new lesion, increase of any measurable lesion by >25%	

Source: Modified from reference 10

Conclusion

Imaging plays a central role in the diagnosis, staging, response evaluation, and follow-up of NB. A thorough knowledge of imaging, use of appropriate scanning technique, and reporting using correct terminology and specific criteria are essential for a radiologist to guide clinical colleagues.

References

1. Matthay KK, Shulkin B, Ladenstein R, Michon J, Giammarile F, Lewington V, *et al*. Criteria for evaluation of disease extent by (123) I-metaiodobenzylguanidine scans in neuroblastoma: A report for the International Neuroblastoma Risk Group (INRG) Task Force. Br J Cancer 2010;102:1319-26.
2. Cohn SL, Pearson AD, London WB, Monclair T, Ambros PF, Brodeur GM, *et al*.; INRG Task Force. The International Neuroblastoma Risk Group (INRG) classification system: An INRG Task Force report. J Clin Oncol 2009;27:289-97.
3. Monclair T, Brodeur GM, Ambros PF, Brisse HJ, Cecchetto G, Holmes K, *et al*.; INRG Task Force. The International Neuroblastoma Risk Group (INRG) staging system: An INRG Task Force report. J Clin Oncol 2009;27:298-303.
4. Brisse HJ, McCarville MB, Granata C, Krug KB, Wootton-Gorges SL, Kanegawa K, *et al*.; International Neuroblastoma Risk Group Project. Guidelines for imaging and staging of neuroblastic tumours: Consensus report from the International Neuroblastoma Risk Group Project. Radiology 2011;261:243-57.
5. Weinstein JL, Katzenstein HM, Cohn SL. Advances in the diagnosis and treatment of neuroblastoma. Oncologist 2003;8:278-92.
6. Kushner BH, Gilbert F, Helson L. Familial neuroblastoma: Case reports, literature review, and etiologic considerations. Cancer 1986;57:1887-93.
7. Russel HV, Pappo AS, Nuchtern JG, Kornguth DG, Wang LL. Solid tumours of childhood. In: DeVita VT, Lawrence TS, Rosenberg SA, editors. DeVita, Hellman and Rosenberg's Cancer: Principles and Practice of Oncology. 8th ed.: Lippincott Williams and Wilkins; 2008. p. 2043-84.
8. Papaioannou G, McHugh K. Neuroblastoma in childhood: Review and radiological findings. Cancer Imaging 2005;5:116-27.
9. Grovas A, Fremgen A, Rauck A, Ruymann FB, Hutchinson CL, Winchester DP, *et al*. The National Cancer Data Base report on patterns of childhood cancers in the United States. Cancer 1997;80:2321-32.
10. Brodeur GM, Pritchard J, Berthold F, Carlsen NL, Castel V, Castelberry RP, *et al*. Revisions of the international criteria for neuroblastoma diagnosis, staging, and response to treatment. J Clin Oncol 1993;11:1466-77.
11. Sawada T, Hirayama M, Nakata T, Takeda T, Takasugi N, Mori T, *et al*. Mass screening for neuroblastoma in infants in Japan. Interim report of a mass screening study group. Lancet 1984;2:271-3.
12. Sawada T, Kidowaki T, Sakamoto I, Hashida T, Matsumura T, Nakagawa M, *et al*. Neuroblastoma. Mass screening for early detection and its prognosis. Cancer 1984;53:2731-5.
13. Nishi M, Miyake H, Takeda T, Kikuchi Y, Hanai J, Yonemori H, *et al*. Mass screening of neuroblastoma in Sapporo City, Japan. Am J Pediatr Hematol Oncol 1992;14:327-31.
14. Woods WG, Gao RN, Shuster JJ, Robison LL, Bernstein M, Weitzman S, *et al*. Screening of infants and mortality due to neuroblastoma. N Engl J Med 2002;346:1041-6.
15. Schilling FH, Spix C, Berthold F, Erttmann R, Fehse N, Hero B, *et al*. Neuroblastoma screening at one year of age. N Engl J Med 2002;346:1047-53.
16. Scott DJ, Wallace WH, Hendry GM. With advances in medical imaging can the radiologist reliably diagnose Wilms' tumours? Clin Radiol 1999;54:321-7.
17. Allolio B, Fassnacht M. Clinical review: Adrenocortical carcinoma: Clinical update. J Clin Endocrinol Metab 2006;91:2027-37.
18. Salmi D, Patel C, Imashuku S, Shimada H, Satake N. Neuroblastoma of unknown primary site with periorbital bone metastasis in a child. Pediatr Blood Cancer 2010;55:361-3.
19. Lonergan GJ, Schwab CM, Suarez ES, Carlson CL. Neuroblastoma, ganglioneuroblastoma, and ganglioneuroma: Radiologic-pathologic correlation. Radiographics 2002;22:911-34.
20. Morgenstern DA, London WB, Stephens D, Volchenboum SL, Hero B, Di Cataldo A, *et al*. Metastatic neuroblastoma confined to distant lymph nodes (stage 4N) predicts outcome in patients with stage 4 disease: A study from the International Neuroblastoma Risk Group Database. J Clin Oncol 2014;32:1228-35.
21. Kushner BH. Neuroblastoma: A disease requiring a multitude of imaging studies. J Nucl Med 2004;4:1172-88.
22. Bombardieri E, Giammarile F, Aktolun C, Baum RP, Bischof Delaloye A, Maffioli L, *et al*.; European Association for Nuclear

Medicine. 131I/123I-metaiodobenzylguanidine (mIBG) scintigraphy: Procedure guidelines for tumour imaging. Eur J Nucl Med Mol Imaging 2010;37:2436-46.

23. Gelfand MJ, Elgazzar AH, Kriss VM, Masters PR, Golsch GJ. Iodine-123-MIBG SPECT versus planar imaging in children with neural crest tumours. J Nucl Med 1994;35:1753-7.
24. Rozovsky K, Koplewitz BZ, Krausz Y, Revel-Vilk S, Weintraub M, Chisin R, *et al*. Added value of SPECT/CT for correlation of MIBG scintigraphy and diagnostic CT in neuroblastoma and pheochromocytoma. AJR Am J Roentgenol 2008;190:1085-90.
25. Ady N, Zucker JM, Asselain B, Edeline V, Bonnin F, Michon J, *et al*. A new 123I-MIBG whole body scan scoring method--application to the prediction of the response of metastases to induction chemotherapy in stage IV neuroblastoma. Eur J Cancer 1995;31A: 256-61.
26. Messina JA, Cheng SC, Franc BL, Charron M, Shulkin B, To B, *et al*. Evaluation of semi-quantitative scoring system for metaiodobenzylguanidine (mIBG) scans in patients with relapsed neuroblastoma. Pediatr Blood Cancer 2006;47:865-74.
27. Howman-Giles RB, Gilday DL, Ash JM. Radionuclide skeletal survey in neuroblastoma. Radiology 1979;131:497-502.
28. Shulkin BL, Hutchinson RJ, Castle VP, Yanik GA, Shapiro B, Sisson JC. Neuroblastoma: Positron emission tomography with 2-[fluorine-18]-fluoro-2-deoxy-D-glucose compared with metaiodobenzylguanidine scintigraphy. Radiology 1996;199:743-50.
29. Sharp SE, Shulkin BL, Gelfand MJ, Salisbury S, Furman WL. 123I-MIBG scintigraphy and 18F-FDG PET in neuroblastoma. J Nucl Med 2009;50:1237-43.
30. Melzer HI, Coppenrath E, Schmid I, Albert MH, von Schweinitz D, Tudball C, *et al*. ^{123}I-MIBG scintigraphy/SPECT versus ^{18}F-FDG PET in paediatric neuroblastoma. Eur J Nucl Med Mol Imaging 2011;38:1648-58.
31. O'Dorisio MS, Chen F, O'Dorisio TM, Wray D, Qualman SJ. Characterization of somatostatin receptors on human neuroblastoma tumours. Cell Growth Differ 1994;5:1-8.
32. Albers AR, O'Dorisio MS, Balster DA, Caprara M, Gosh P, Chen F, *et al*. Somatostatin receptor gene expression in neuroblastoma. Regul Pept 2000;88:61-73.
33. Schilling FH, Bihl H, Jacobsson H, Ambros PF, Martinsson T, Borgström P, *et al*. Combined (111) In-pentetreotide scintigraphy and (123) I-mIBG scintigraphy in neuroblastoma provides prognostic information. Med Pediatr Oncol 2000;35:688-91.
34. Yanik GA, Parisi MT, Shulkin BL, Naranjo A, Kreissman SG, London WB, *et al*. Semiquantitative mIBG scoring as a prognostic indicator in patients with stage 4 neuroblastoma: A report from the Children's oncology group. J Nucl Med 2013;54:541-8.
35. Raggi CC, Maggi M, Renzi D, Calabrò A, Bagnoni ML, Scaruffi P, *et al*. Quantitative determination of sst2 gene expression in neuroblastoma tumour predicts patient outcome. J Clin Endocrinol Metab 2000;85:3866-73.

Cite this article as: Kembhavi SA, Shah S, Rangarajan V, Qureshi S, Popat P, Kurkure P. Imaging in neuroblastoma: An update. Indian J Radiol Imaging 2015;25:129-36.

Source of Support: Nil, **Conflict of Interest:** None declared.