

Increased fetal endocardial echogenicity mimicking endocardial fibroelastosis following maternal organophosphorus poisoning and its complete regression in utero

Karippaliyil Balakumar, Kannan Misha, Karippaliyil Milind

Department of Ultrasonography, Balku's Scan, PVS Hospital, Calicut 2, Kerala, India

Correspondence: Dr. Karippaliyil Balakumar, Balkus Scan Centre, Calicut 2, Kerala - 673 002, India. E-mail: balakumar_k@dataone.in

Abstract

Fetal endocardial fibroelastosis (EFE) has been diagnosed by antenatal ultrasonography in the past few years. A typical case of isolated endocardial fibroelastosis is illustrated here, in a fetus of 22 weeks of gestational age exposed to maternal organophosphorus poisoning at 20 weeks. No other structural cardiac or other systemic anomalies were detected in this fetus. The abnormal fetal echocardiographic features mimicking endocardial fibroelastosis completely regressed after 14 weeks and a normal full-term baby was delivered. Postnatal echocardiogram showed normal cardiac parameters. The diagnostic features mimicking EFE following maternal organophosphorus poisoning at 20 weeks of gestational age and the subsequent complete reversal of these changes after 14 weeks of diagnosis are reported for the first time in the literature.

Key words: Fetal anomaly; fetal cardiac anomaly; fetal cardiomyopathy; fetal endocardial fibroelastosis; fetal echocardiography; fetal organophosphorus poisoning

Introduction

Though fetal endocardial fibroelastosis (EFE) has been reported in the past three decades, the classical echocardiographic features of EFE following maternal organophosphorus ingestion at 20 weeks of gestation is reported for the first time in the literature. These signs completely regressed within a period of 14 weeks and a normal healthy full-term baby was delivered. This report is unique due to the fact that fetal echocardiographic features consistent with the diagnosis of endocardial

fibrosis following maternal organophosphorus poisoning are not an indication for termination of pregnancy, which is contradictory to the common practice.

Case Report

A 23-year-old primigravida at 20 weeks of gestation was hospitalized, following suicidal attempt by ingestion of organophosphorus pesticide (carbofuran). She was treated with antidote, corticosteroid steroid, and supportive measures. Following recovery after 2 weeks, she was referred for a targeted scan for anomalies at 22 weeks of gestation.

All fetal routine biometric parameters were normal on routine scanning. Fetal echocardiography showed normal cardiac situs, size, and axis. Both ventricular and interventricular septal endocardial surfaces showed diffuse hyperechoic thickening [Figure 1]. The interventricular septum was pearly white [Figure 2]. This pearly white

Access this article online

Quick Response Code:



Website:
www.ijri.org

DOI:
10.4103/0971-3026.120266

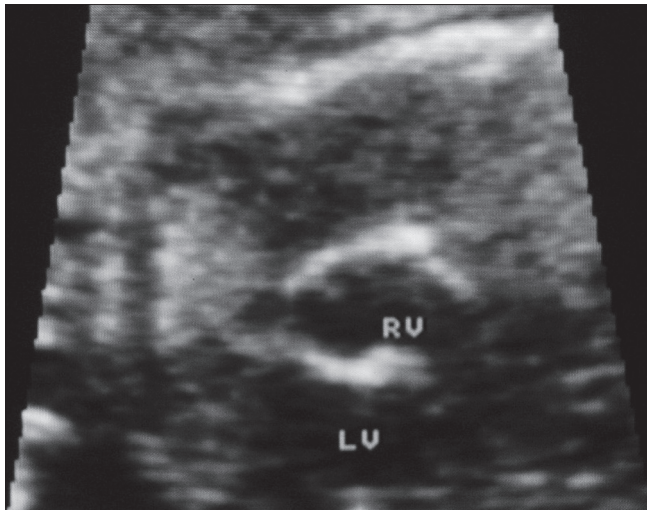


Figure 1: Slightly oblique short axis view of the fetal heart at 22 weeks of gestation shows the "pearly white" endocardium of ventricles (RV: Right ventricle, LV: Left ventricle) and interventricular septum (IVS)

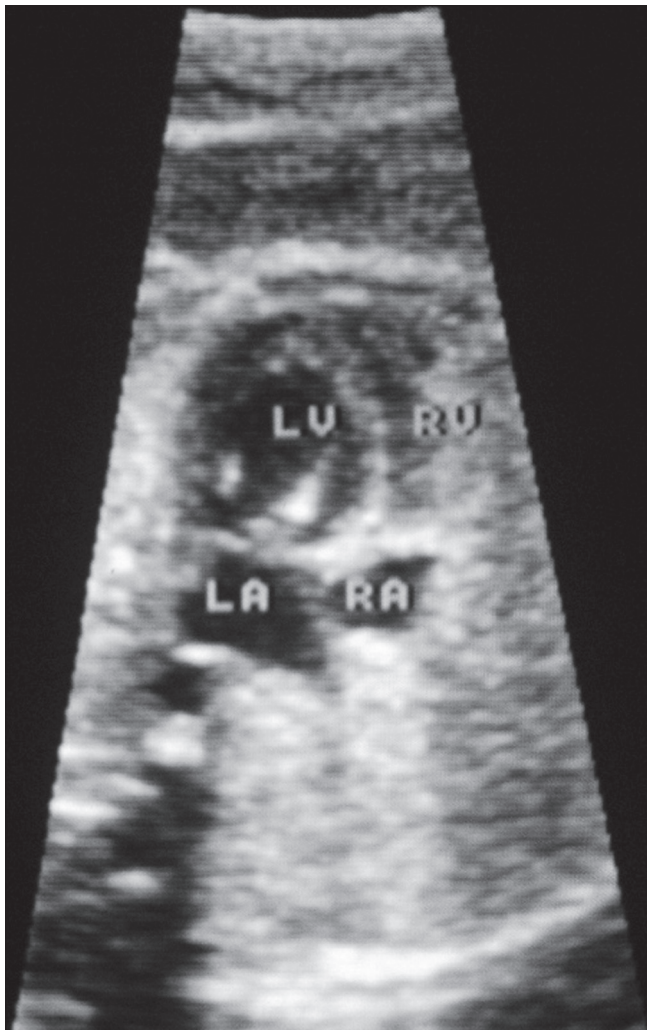


Figure 3: The 4-chamber view shows the hyperechoic endocardium extending along the crux and the mitral leaflets. The hyperechoic mitral leaflets are opening into the left ventricle (LV: Left ventricle, RV: Right ventricle, LA: Left atrium, RA: Right atrium)

lining was extending along the crux and atrioventricular valves [Figure 3]. These changes were more involving the left ventricle and the mitral valve. The abnormally curved mitral leaflets had rolled tips [Figure 4]. There was mild degree incompetence of the mitral valve. The proximal outflow tracts, mainly up to the semilunar valves, were also brighter with normal crossing, dimensions, and flow [Figure 5]. The aortic and pulmonary artery valves showed no evidence of stenosis or incompetence. Pulsed Doppler study (cursor directed through the left ventricle along the junction of the anterior leaflet of the mitral valve and left ventricular outflow tract) showed E/A ratios of mitral and tricuspid valves below the 2.5th percentile (0.41 and 0.45, respectively) for this period of gestation.^[1] The E/A ratio of the atrioventricular valves is calculated

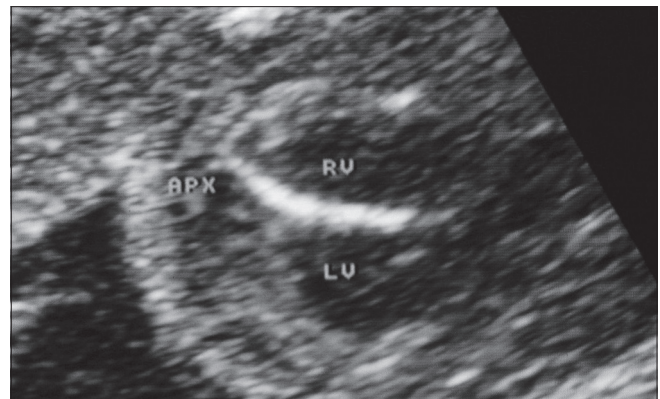


Figure 2: Magnified view of the interventricular septum shows the hyperechogenicity of the endocardial surfaces (APX: Cardiac apex, RV: Right ventricle, LV: Left ventricle)

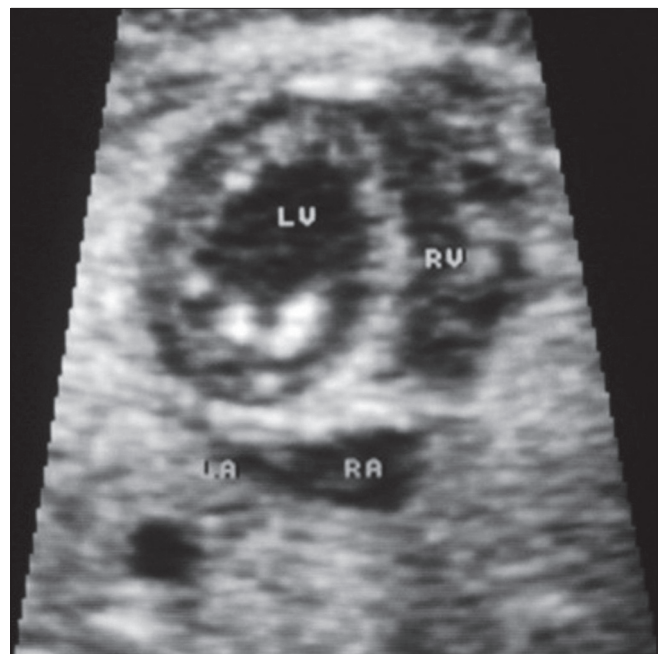

Figure 4: Magnified view of the mitral leaflets shows the rolled tips within the left ventricle (LV: Left ventricle, RV: Right ventricle, LA: Left atrium, RA: Right atrium)

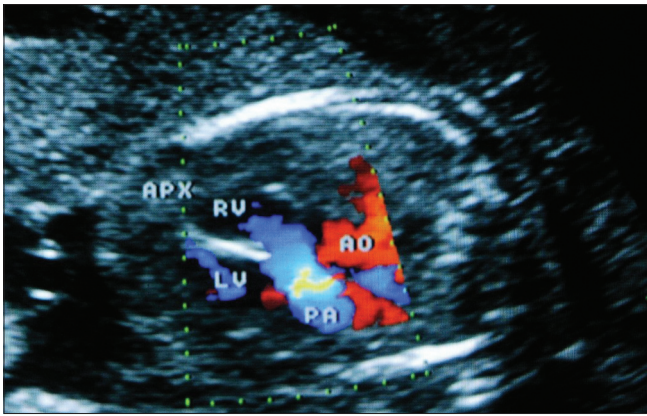


Figure 5: The outflow tracts show normal calibre and flow (APX: Cardiac apex, RV: Right ventricle, LV: Left ventricle, AO: Aorta, PA: Pulmonary artery)

by dividing the peak velocity of “E” wave (due to early diastolic filling of the ventricle) by the peak velocity of the “A” wave (due to late diastolic filling of the ventricle from atrial contraction).

The myocardial performance index (MPI), otherwise known as Tei index (TI), for the left ventricle was more (0.71)^[2] than the normal value expected at this gestational age (average value at this age is 6). There were no significant Doppler spectral changes of the inferior vena cava (such as reversal of A wave in the inferior vena cava or hepatic veins) or umbilical vein (biphasic rather than triphasic spectral pattern and umbilical venous pulsations) to suggest impending cardiac failure. The routine serum immunological studies for maternal viral infections were normal.

Reassessment at 26 weeks of gestation showed non-progressive echocardiographic abnormalities and mild mitral incompetence as before. The endocardial thickening and hyperechogenicity were persisting and the ventricular wall thickness was normal. Follow-up echocardiography at 36 weeks of gestation showed normal fetal cardiac chambers and outflow tracts. The endocardial thickening and hyperechogenicity had completely regressed by this time. The myocardial contractions and ventricular fractional shortening were normal. The atrioventricular valves showed no stenosis or incompetence now. The fetal growth parameters and biophysical score were normal. She delivered a normal male baby by term with normal echocardiographic features.

Discussion

Carbofuran (2, 3-dihydro-2,2-dimethyl-7-benzofuranyl methylcarbamate) is a very toxic anticholine esterase carbamate widely used as a pesticide all over the world. This pesticide crosses the placental barrier^[3] and inhibits choline esterase, causing severe neurotoxicity. The oral LD₅₀ (median lethal dose) of this chemical in animals ranges

from 8 to 19 mg/kg and for humans it is 11 mg/kg.^[4] The fatal concentration in the human blood is 0.32-11.6 µg/mL.^[5] This mother had consumed diluted carbofuran of which some quantity was removed later by gastric lavage. The exact maternal serum concentration of carbofuran at the time of admission was not known. However, she had all the symptoms and signs of moderate degree organophosphorus poisoning and took 2 weeks for complete recovery.

This fetus at 22 weeks of gestational age had all the classical echocardiographic features of endocardial fibroelastosis (the term was first coined by Weinberg and Himmelfarb^[6]). The EFE is diagnosed by the echocardiographic features such as hyperechoic endocardial thickening extending along the ventricular walls and atrioventricular valves. These progressive changes lead to decreased cardiac function which is best assessed by the MPI (or TI).^[7,8] The left ventricular Tei index was more in this fetus due to the increased isovolumetric relaxation time (IRT) (>2 SD above the mean for this age) and the shorter ejection time (ET). This fetus had the typical diagnostic features of endocardial fibroelastosis which gradually subsided within a period of 14 weeks. This is likely to be due to the capability of the myocardium to recover from the temporary myocardial toxicity induced by the pesticide.

EFE has been reported in the literature as early as 14 weeks of gestation.^[9] Most of the other reported cases are in the late second or third trimesters. The fetus in this case was exposed to acute maternal carbofuran poisoning at 20 weeks of gestation. Since fetal period is characterized by rapid cellular multiplication and organization, the endocardium is also affected by the toxin. It is suggested that any severe mechanical or toxin-induced stress to the cardiac tissue can stimulate the proliferation and transformation of fibroblasts of the endocardial lining^[10] to deposit more collagen and elastin. A study on the effect of organophosphorus compounds on fetal growth and preterm delivery did not highlight any cardiac sequelae. A recent follow-up of newborns exposed to maternal organophosphorus poisons during pregnancy has revealed growth disturbances, metabolic disorders, and CNS morbidity, and no cardiac sequelae.^[11] This is likely to support the explanation that the cardiac tissue can withstand the damage more efficiently in the fetal period and the changes may be transient.

Traditionally, the endocardial fibroelastosis has been classified as primary and secondary. In the primary type, there is no structural cardiac abnormality, whereas in the secondary type, a cardiac abnormality is demonstrable. The general agreement is that any severe myocardial stress is the basic pathology leading to endocardial fibroelastosis. The case illustrated here shows that EFE may result from myocardial toxicity induced by organophosphorus poisoning, which may completely regress without further complications and is not a definite indication for the

termination of pregnancy. The use of intensive maternal corticosteroid administration must have contributed to the complete regression of EFE.^[12]

References

1. DeVore GR. Pulsed Doppler examination of the fetal heart. In: Goldberg BB, McGahan JP, editors. Atlas of Ultrasound measurements. 2nd ed. Philadelphia: Mosby Inc./Elsevier; 2006.
2. Friedman D, Buyon J, Kim M, Glickstein JS. Fetal cardiac function assessed by Doppler myocardial performance index (Tei index). Ultrasound Obstet Gynecol 2003;21:33-6.
3. Gupta RC. Carbofuran toxicity. J Toxicol Environ Health 1994;43:383-418.
4. Sax NI. Dangerous properties of industrial materials. In: Sax NI, Feiner B, editors. Dangerous properties of industrial materials – Volume 1. 6th ed. Van Nostrand Reinhold Co, New York; 1984. p. 1152-3.
5. Ameno K, Lee SK, In SW, Yang JY, Yoo YC, Ameno S, *et al.* Blood carbofuran concentrations in suicidal ingestion cases. Forensic Sci Int 2001;116:59-61.
6. Letteer CR. Endocardial fibroelastosis. Ann Intern Med 1953;38:573-82.
7. Comas M, Crispi F, Gomez O, Puerto B, Figueras F, Gratacos E. Gestational age- and estimated fetal weight-adjusted reference ranges for myocardial tissue Doppler indices at 24-41 weeks' gestation. Ultrasound Obstet Gynecol 2011;37:57-64.
8. Cruz-Martínez R, Figueras F, Bennasar M, García-Posadas R, Crispi F, Hernández-Andrade E, *et al.* Normal reference ranges from 11 to 41 weeks' gestation of fetal left modified myocardial performance index by conventional Doppler with the use of stringent criteria for delimitation of the time periods. Fetal Diagn Ther 2012;32:79-86.
9. Rustico MA, Benettoni A, Bussani R, Maieron A, Mandruzzato G. Early fetal endocardial fibroelastosis and critical aortic stenosis: A case report. Ultrasound Obstet Gynecol 1995;5:202-5.
10. Kahyaoglu I, Kahyaoglu S, Sut H, Onen S, Mollamahmutoglu L. Isolated fetal endocardial fibroelastosis diagnosed and terminated at 22 weeks of gestation: A case report. Perinat J 2010;18:109-12.
11. Dordevic, Vujic A, Jovanovic B, Dordevic G, Sazdanovic M, Sazdanovic P. Neonatal outcome following exposure to organophosphorus pesticides. Arch Biol Sci Belgrade 2010;62:1-8.
12. Raboisson MJ, Fouron JC, Sonesson SE, Nyman M, Proulx F, Gamache S. Fetal Doppler echocardiographic diagnosis and successful steroid therapy of Luciani-Wenckebach phenomenon and endocardial fibroelastosis related to maternal anti-Ro and anti-La antibodies. J Am Soc Echocardiogr 2005;18:375-80.

Cite this article as: Balakumar K, Misha K, Milind K. Increased fetal endocardial echogenicity mimicking endocardial fibroelastosis following maternal organophosphorus poisoning and its complete regression in utero. Indian J Radiol Imaging 2013;23:262-5.

Source of Support: Nil, **Conflict of Interest:** None declared.