

Cavernous hemangioma located at the foramen of Monro: Radiopathological correlation

Sonia Bhatia, Abhay K Kapoor, Rajiv Gupta, Tushar Sahni

Department of Radiology, Medanta-The Medicity Hospital, Gurgaon, India

Correspondence: Dr. Sonia Bhatia, Department of Radiology, Medanta-The Medicity Hospital, Gurgaon - 122 001, India.
E-mail: soniabhatia0112@gmail.com

Abstract

Intraventricular cavernous hemangiomas are rare. Amongst them, cavernomas located at the foramen of Monro are of greater interest because of their rare location, varied symptoms, and often association with hydrocephalus. We present a rare case of cavernous hemangioma located at foramen of Monro, with its radiopathological confirmation.

Key words: Cavernous hemangioma; foramen of monro; intraventricular

Introduction

Cavernous hemangiomas are common benign vascular malformations and can be seen anywhere in the central nervous system. These constitute 5-10% of vascular malformations occurring in the central nervous system. However, their existence in the intraventricular region is very rare, constituting 2-10% of all cerebral cavernous malformations. Those occurring at the foramen of Monro are still infrequent. As per our knowledge, only 14 cases of cavernous hemangiomas at the foramen of Monro have been reported previously. We report a case of cavernous hemangioma located at the foramen of Monro, with its pathological correlation.

Case Report

A 29 year-old female patient presented with non-throbbing intermittent headache for a month before admission. The pain aggravated in the last 2 days. The patient also

complained of projectile vomiting in the last 2 days. There was no history of fever, seizures, associated memory disturbance, or altered consciousness. On physical examination, no neurological deficit was found. Magnetic resonance image (MRI) brain revealed a relatively well-delineated lobulated lesion in the anterosuperior aspect of the third ventricular roof, centered in the region of foramen of Monro. On T1-weighted images (T1WI), the lesion was isointense with few small hyperintense hemorrhagic foci within [Figure 1A], and on T2-weighted images (T2WI), the lesion appeared heterogeneous with a peripheral rim of marked hypointensity [Figure 1B]. Cystic areas and fluid-fluid levels were seen within the lesion. The lesion showed mild heterogeneous enhancement on post-contrast imaging [Figure 1C]. Susceptibility-weighted images revealed marked blooming confirming the hemorrhagic nature of the lesion [Figure 2A]. The lesion was causing mass effect in the form of moderate dilatation of bilateral lateral ventricles with periventricular T2W hyperintensities suggesting obstructive hydrocephalus with transependymal ooze. An incidental note was also made of a tubular vascular enhancing structure with branching pattern in the left cerebellum representing developmental venous anomaly [Figure 2B].

Endoscopic transventricular excision of the vascular malformation and septostomy of septum pellucidum was done. Intraoperatively, the mass was seen to be located in the third ventricle, causing obstruction at the foramen

Access this article online

Quick Response Code:



Website:
www.ijri.org

DOI:
10.4103/0971-3026.120259

of Monro, and showed xanthochromic appearance. Complete excision of the lesion was done and histological examination revealed mulberry-like cluster of dilated thin-walled capillaries without any intervening neural tissue and surrounding hemosiderin, suggesting cavernous hemangioma [Figure 3].

Discussion

Cavernous hemangiomas of the brain are benign, angiographically occult vascular malformations. These are

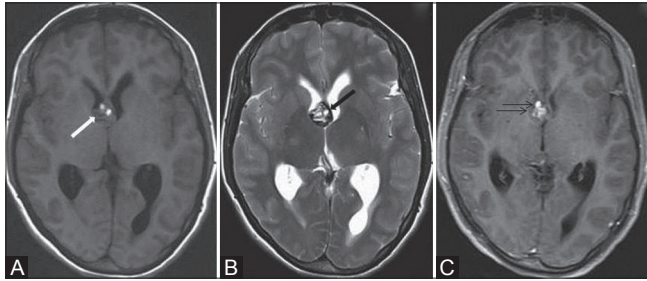


Figure 1 (A-C): Magnetic resonance image (MRI) reveals a relatively well-delineated anterior third ventricular mass located at the foramen of Monro, showing heterogeneous signal intensity with hyperintense hemorrhagic areas (white arrow) within on axial T1WI (A). Typical peripheral hemosiderin rim of low signal intensity (black arrow) is seen on T2WI (B). Post-contrast T1WI image shows mild heterogeneous enhancement (double arrow) of the lesion (C)

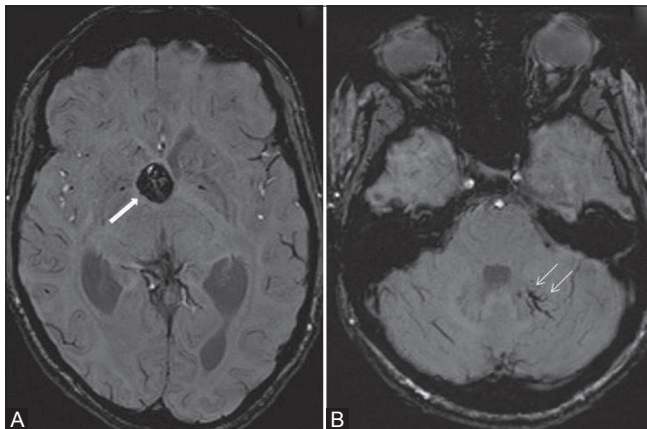


Figure 2 (A, B): Susceptibility-weighted images show marked blooming of the lesion (white arrow) confirming its hemorrhagic nature (A). Associated developmental venous anomaly (double arrow) is seen in left cerebellar hemisphere (B)

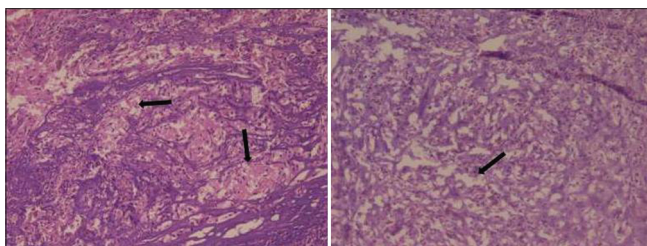


Figure 3: Frozen and H and E sections reveal cavernous hemangioma with large vascular spaces (black arrows) lined by endothelial cells

composed of compact masses of sinusoidal-type vessels immediately in apposition to each other without any recognizable intervening neural tissue. Although lesions have been described in all age groups, peak incidence of presentation is usually in the third or fourth decade with no known sex predilection.^[1-3] Cavernous malformations can occur anywhere in the intracranial parenchyma in the spinal cord or in the cranial or spinal nerve roots.^[1] Most of them occur in an intra-axial location. The most common site for these lesions is intra-axial and supratentorial with most of the lesions being located in deep white matter, basal ganglia, brainstem, and cerebellum.^[4] They have rarely been reported in intraventricular locations. About 90 cases of intraventricular cavernous hemangiomas have been reported of which about half were located in the third ventricle and 14 at foramen of Monro.^[4] In a review of literature by Reyns *et al.*, of the 45 cases reported in literature, 44% of intraventricular cavernomas were found to be located in the third ventricle, 27% in the lateral ventricle, 20% in the trigone, and 9% in the fourth ventricle.^[5] Those located at the foramen of Monro have been reported only in 15 cases including our case.^[4,6] The clinical presentation is highly variable, ranging from incidental finding to fatal hemorrhage.^[2] Supratentorial lesions present with seizure, hemorrhage, focal mass effect, or intracranial hypertension.^[4] The commonest cause for symptoms is hydrocephalus either due to mass effect, especially in the foramen of Monro lesions, or due to obstruction to CSF due to hemorrhage in the intraventricular lesions. In our case, headache and vomiting resulted from increased intracranial pressure due to obstructive hydrocephalus induced by cavernoma located at the foramen of Monro.

Histopathologically, cavernous malformations are well circumscribed, lobulated, red-to-purple, raspberry-like lesions.^[1] Microscopically, these are composed of honeycomb of endothelial-lined capillaries separated by fibrous tissue.

Characteristically, cavernomas are hyperdense on computed tomography (CT) scan and extensive calcifications may be seen in 20% of cases.^[3] One may only see evidence of hemorrhage in the lesion, which may enhance on post-contrast imaging. MRI offers the most sensitive means of diagnosing cavernous hemangiomas.^[1] Blood products of varying ages may be present throughout the lesion. These appear hyper-to-isointense on T1WI and show mixed signal on T2WI with peripheral low-signal intensity rings. Additional gradient echo sequences can detect hemorrhage in different stages.^[3] On angiography, these are occult lesions because of low flow and absence of feeding vessels.^[4]

Certain individuals may have multiple lesions. In addition, familial predisposition has also been observed. Careful inspection of imaging studies should be done to look for small occult lesions or those that have not yet hemorrhaged. Cavernous malformations can be seen associated with other

vascular malformations, most frequently developmental venous anomalies.

The important differentials of the lesions occurring at the foramen of Monro include colloid cyst, central neurocytoma, giant cell astrocytoma, and oligodendroglioma. Cystic and hemorrhagic metastases, however uncommon, may also occur at the foramen of Monro.^[4] Colloid cysts are oval-to-round lesions. Approximately two thirds are homogeneously hyperdense compared to brain on plain scans and one-third of them are isodense. On MRI, the signal characteristics of colloid cysts vary. Most commonly, these appear hyperintense on T1WI and hypointense on T2WI. Central neurocytomas are inhomogeneous, partially calcified, and mildly enhancing lateral ventricular masses. On MRI, these are seen to be inhomogeneously isointense on T1WI with variable appearance on T2WI. Giant cell astrocytomas are seen in association with tuberous sclerosis and appear iso-to-hypodense on CT scans with focal areas of calcification and cyst formation. These demonstrate hypo- to isointense signal on T1WI and are iso- to hyperintense on T2WI. Oligodendrogliomas most commonly show dense areas of calcification. These appear hypo- to isointense on T1WI and hyperintense on T2WI, showing moderate patchy enhancement.

With regard to treatment, when patients present with recurrent hemorrhage, seizures, or neurological deterioration, surgical treatment should be considered.^[2,3] Stereotactic radiosurgery is used for patients with inoperable hemangiomas. Lesion removal helps in symptom correction

in younger patients, whereas conservative treatment is considered appropriate in older patients.

Conclusion

Intraventricular vascular malformations are rare. We report a rare case of cavernous hemangioma at the foramen of Monro, diagnosed on the basis of imaging studies and confirmed on histopathology.

References

1. Li ST, Hu WZ, Kochanski R, Zhang WC, Tao BB, Lu HT, *et al.* Cavernous angiomas of the third ventricle: A series of eight patients and review of the literature. *J Neurol Sci* 2012;29:863-76.
2. Raychaudhuri R, H. Huntington Batjer, Issam A. Awad. Intracranial cavernous angioma: A practical review of clinical and biological aspects. *Surg Neurol* 2005;63:319-28.
3. Nguyen JD, Kanekar S, Annilyn S. Purayidom. Intraventricular cavernoma. *Appl Radiol* 2010;39:11.
4. Lee BJ, Choi CY, Lee CH. Intraventricular cavernous hemangiomas located at the foramen of monro. *J Korean Neurosurg Soc* 2012;52:144-7.
5. Reyns N, Assaker R, Louis E, Lejeune JP. Intraventricular cavernomas: Three cases and review of the literature. *Neurosurgery* 1999;44:648-54.
6. Chen CL, Leu CH, Jan YJ, Shen CC. Intraventricular cavernous hemangioma at the foramen of Monro: Case report and literature review. *Clin Neurol Neurosurg* 2006;108:604-9.

Cite this article as: Bhatia S, Kapoor AK, Gupta R, Sahni T. Cavernous hemangioma located at the foramen of Monro: Radiopathological correlation. *Indian J Radiol Imaging* 2013;23:202-4.

Source of Support: Nil, **Conflict of Interest:** None declared.