

Giant sacrococcygeal teratoma embolization

Umberto G Rossi, Maurizio Cariati, Paolo Tomà¹

Department of Radiology and Interventional Radiology, San Carlo Borromeo Hospital, Via Pio II 3, 20153 Milano, Italy,

¹Department of Radiology, Pediatric Hospital Bambino Gesù, Piazza S. Onofrio 4, 00165 Roma, Italy

Correspondence: Dr. Umberto G. Rossi, Department of Radiology and Interventional Radiology, San Carlo Borromeo Hospital, Via Pio II 3, 20153 Milano, Italy. E-mail: urossi76@hotmail.com

Abstract

Resection of giant sacrococcygeal teratoma with high-vasculature in newborns can be a fatal procedure due to massive bleeding of the tumor. Endovascular embolization of the arteries that supply the tumor may lead to minimal blood loss. We present a case of giant high-vascular sacrococcygeal teratoma type-1 that was embolized in an infant born at 35 weeks gestation. This procedure led to a safe, surgical resection with minimal bleeding: 12 ml.

Key words: Angiography; embolization; MRI; newborn; sacrococcygeal teratoma

Introduction

Sacrococcygeal teratoma may be detected antenatally by physical examination and imaging.^[1] When sacrococcygeal teratoma has a high vascular component and a diameter exceeding 10 cm, it has a high risk of rupture and consequently profuse bleeding before and especially during surgical resection.^[2,3] We present a case of a giant high-vascular sacrococcygeal teratoma type-1 that was treated with preoperative endovascular embolization prior to its complete surgical resection.

Case Report

A giant high-vascular sacrococcygeal teratoma type-1 was detected in a female fetus by prenatal ultrasound and magnetic resonance [Figure 1].^[1] The patient with the giant sacrococcygeal teratoma (maximum diameter 15.5 cm) was delivered by cesarean birth at 35 weeks

gestation, with a weight of 3240 g [Figure 2]. Two hours later, through the left subclavian artery, the patient underwent abdominal aorta angiography. This confirmed the high-vascular tumor supplied by the middle sacral artery and distal vessels from the right internal iliac artery [Figure 3]. All these arteries were embolized distally with gelatin sponges. With the angiographic overlay technique, the embolization of the middle sacral artery was completed with a metallic pushable coil deployed proximally.^[2,3] The final control demonstrated a successful embolization of the tumor [Figure 4]. Total procedure time was 55 min. The patient received a total of 20 ml of fluids and 6ml of non-ionic contrast medium of concentration of 300 mg/dl (maximum contrast medium dose 2 ml/kg). Consequently, the neonate was transferred from the angiographic suite to the surgical one. The resection of the giant sacrococcygeal teratoma was quite easy because the bleeding was really minimal: only 12 ml. Pathologic evaluation confirmed the teratomatous nature of the tumor.

Conclusion

The feeding arteries of giant high-vascular sacrococcygeal teratoma of a newborn are perfectly identified by an angiography. Preoperative endovascular embolization of the feeding arteries is a safe and effective procedure that leads to a minimal blood loss during the tumor surgical resection.

Access this article online

Quick Response Code:



Website:
www.ijri.org

DOI:
10.4103/0971-3026.116571

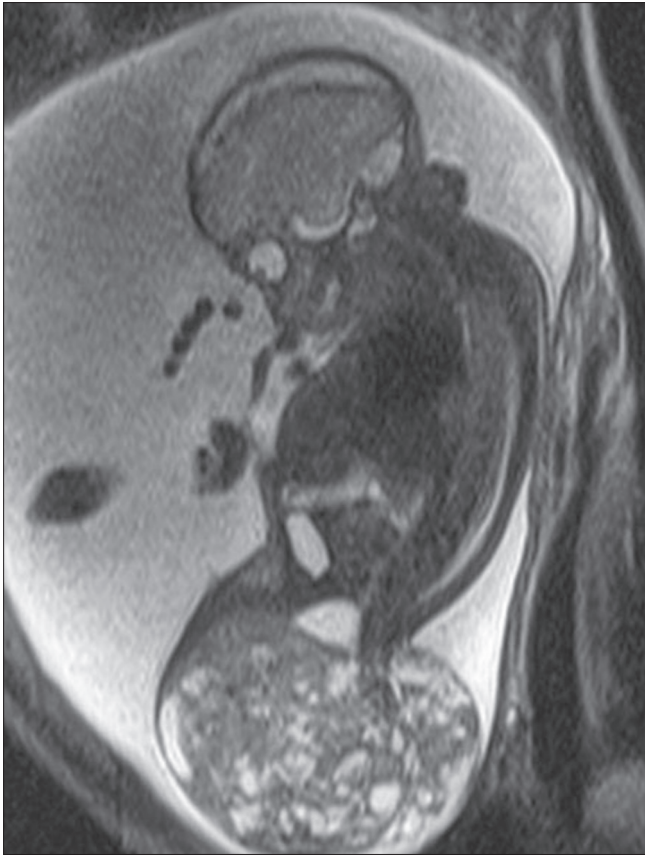


Figure 1: Sagittal T2-weighted MR image that demonstrates a large mass containing well-defined areas of varying signal intensity

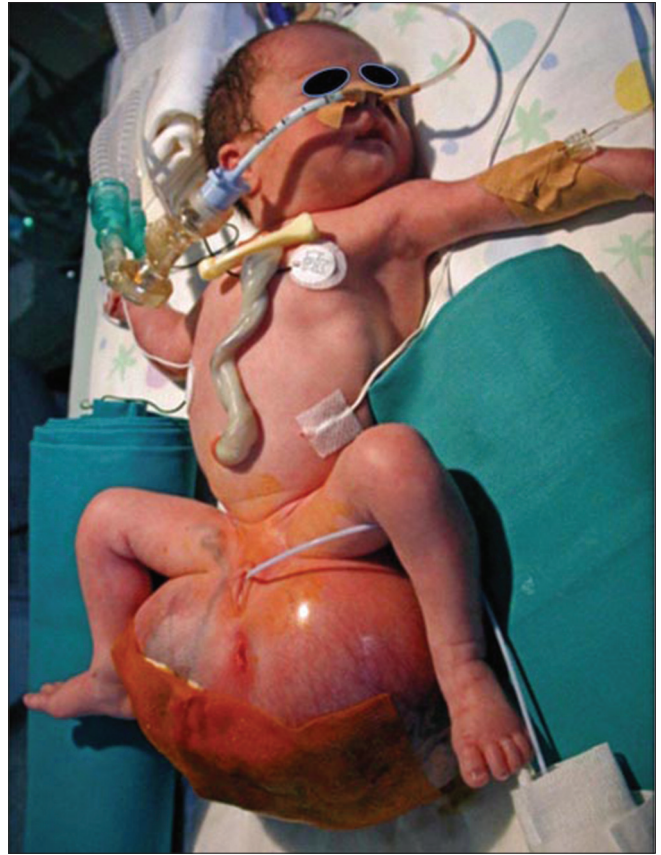

Figure 2: Photo of the patient with the giant sacrococcygeal teratoma after birth

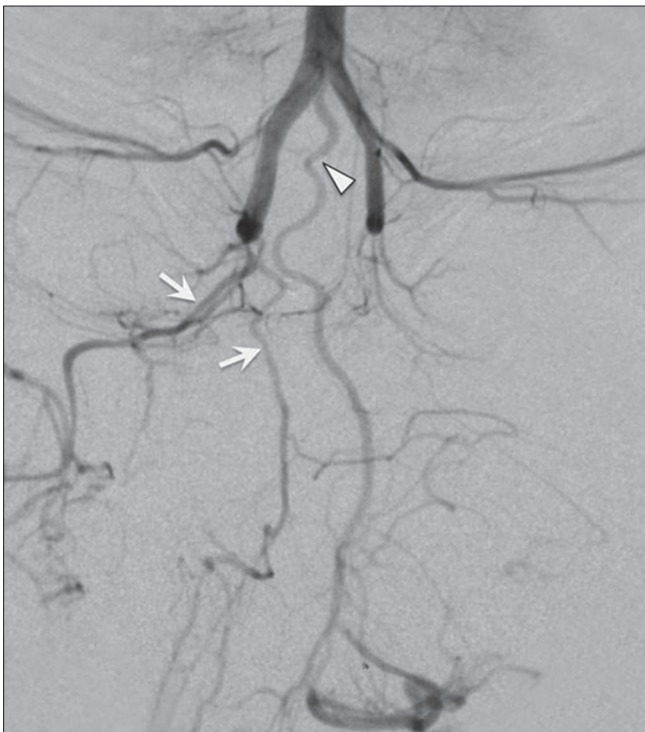

Figure 3: Abdominal aorta angiography that confirms the highly vascular nature of the mass with hypertrophy of the middle sacral artery (arrowhead) and distal vessels from the right internal iliac artery (arrows)

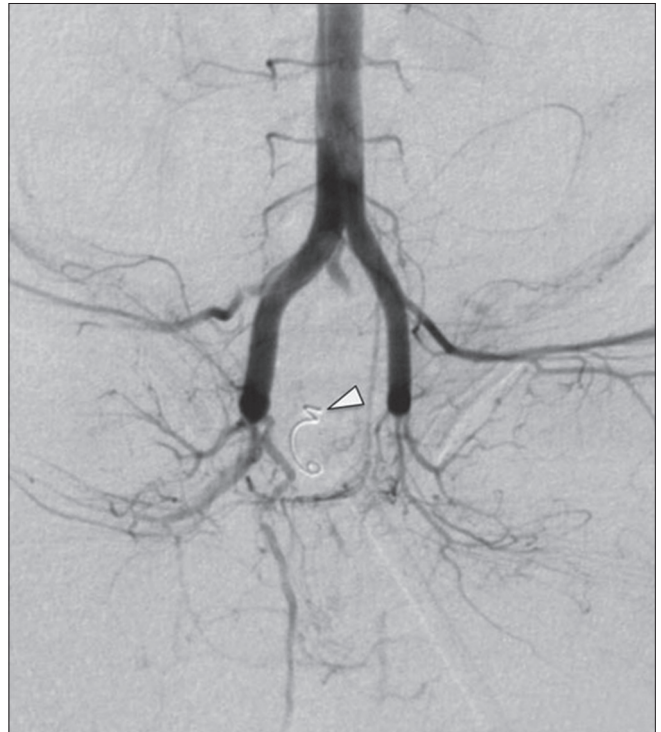


Figure 4: Post-embolization abdominal aorta angiography demonstrates the successful embolization of the feeding vessel of the mass. Note the shadow of the metallic coil deployed into the middle sacral artery (arrowhead)

References

1. Avni FE, Guibaud L, Robert Y, Segers V, Ziereisen F, Delaet MH, *et al.* MR imaging of fetal sacrococcygeal teratoma: Diagnosis and assessment. *AJR Am J Roentgenol* 2002;178:179-83.
2. Lahdes-Vasama TT, Korhonen PH, Seppänen JM, Tammela OK, Iber T. Preoperative embolization of giant sacrococcygeal teratoma in a premature newborn. *J Pediatr Surg* 2011; 46:e5-8.
3. Cowles RA, Stolar CJ, Kandel JJ, Weintraub JL, Susman J, Spigland NA. Preoperative angiography with embolization and radiofrequency ablation as novel adjuncts to safe surgical resection of a large, vascular sacrococcygeal teratoma. *Pediatr Surg Int* 2006;22:554-6.

Cite this article as: Rossi UG, Cariatì M, Tomà P. Giant sacrococcygeal teratoma embolization. *Indian J Radiol Imaging* 2013;23:145-7.

Source of Support: Nil, **Conflict of Interest:** None declared.