

# Initial experience with Angioseal™: Safety and efficacy of the endovascular closure device

Sachin Modi, Rakesh Gadvi, Suresh Babu

Department of Interventional Radiology, Sandwell and West Birmingham NHS Trust, Birmingham, West Midlands, UK

**Correspondence:** Dr. Sachin Modi, Department of Radiology, City Hospital, Dudley Road, Birmingham, B18 7QH.  
E-mail: sachin.modi@doctors.net.uk

## Abstract

**Background:** Vascular access site management is crucial to safe, efficient, and comfortable diagnostic or interventional percutaneous procedures. The Angioseal™ vascular closure device has been shown to be safe and effective in reducing the time to hemostasis following angiographic or interventional procedures. Relatively few studies have been conducted in the UK to assess the safety and efficacy of the device in a local setting. **Materials and Methods:** Data were retrospectively reviewed on 147 patients who underwent either diagnostic angiography or percutaneous interventional procedures from January 2008 to October 2009, and who had the femoral access site closed by 6F VIP Angioseal. A total of 147 patients (F: 49, M: 98), including 80 right femoral punctures, 57 left femoral punctures, and 10 bilateral punctures were reviewed using radiological reports and patients' clinical data. Data on antiplatelet and anticoagulant therapy were recorded. All procedures were carried out by two interventional radiologists at a single institution, under similar operating conditions. **Results:** There were a total of six complications (4.47%), of which one was a major complication (0.75%), i.e., retroperitoneal bleed. There were five minor complications (3.73%), which included device deployment failure (2), device malfunction (2), and a superficial hematoma (>6 cm). Total complications were 6 out of 157 (3.8%) [95% CI = 0.8-6.8%]. Successful hemostasis was achieved in less than 5 min in over 97% of patients. Successful device deployment was seen in over 98% of cases. **Conclusion:** We conclude that in our experience, the Angioseal vascular closure device is a safe and efficient means of achieving hemostasis post antegrade or retrograde puncture for diagnostic and percutaneous intervention procedures.

**Key words:** Angiography; Angioseal™; endovascular intervention; vascular access site closure

## Introduction

### Hemostasis

Hemostasis of arterial puncture sites is still a critical point of vascular interventional.<sup>[1,2]</sup> Vascular access site complications occur in 5% of cases.<sup>[3]</sup> Access site complications lengthen hospital stay. Patients sometimes require blood transfusions and surgical repairs.<sup>[4]</sup> Monitoring of coagulation parameters,

delayed arterial sheath removal, manual compression, and supine bed rest (for at least 6-8 h after sheath pull out) are considered effective preventative measures, but increase patient discomfort and nursing time.<sup>[1,5]</sup>

To overcome these issues, hemostatic devices have been developed to allow immediate arterial sheath removal after the procedure, as well as early patient mobilization and hospital discharge.<sup>[4]</sup> Newly available femoral arteriotomy closure/sealing devices have received rapid acceptance from invasive cardiology and vascular radiology communities.<sup>[6]</sup>

At our institution, a femoral arteriotomy closure device is used to achieve immediate post-procedure hemostasis: Angioseal™ (St. Jude Medical, Minnetonka, MN, USA). The efficacy and safety of the Angioseal vascular closure device

### Access this article online

#### Quick Response Code:



**Website:**  
www.ijri.org

**DOI:**  
10.4103/0971-3026.116566

post retrograde and antegrade puncture are well established in the literature.<sup>[1,4,7-9]</sup>

**CFA puncture**

Vascular radiological interventional procedures are almost always performed following puncture of the common femoral artery (CFA).<sup>[10,11]</sup> The standard retrograde CFA puncture is used for diagnostic lower limb angiography and aorto-iliac interventions. Antegrade puncture refers to placement of an angiographic needle in the CFA in the direction of arterial flow.

The inguinal ligament is the anatomical landmark that separates the external iliac artery from the CFA.<sup>[6]</sup> The inguinal ligament extends from the anteroiliac spine to the pubic tubercle. Fluoroscopy is helpful in guiding the arterial puncture. As the ligaments are not radiopaque, the proximal end of the CFA can be correlated with the proximal edge of the femoral head keeping in mind the imaginary line transversing from the anteroiliac spine to the pubic tubercle.<sup>[10]</sup>

A high puncture (above the inguinal ligament) is associated with increased incidence of groin hematoma and retroperitoneal haemorrhage.<sup>[10,11]</sup> A low puncture is associated with increased incidence of arterio-venous (AV) fistula, vessel thrombosis, and pseudoaneurysm formation.<sup>[6,10,11]</sup>

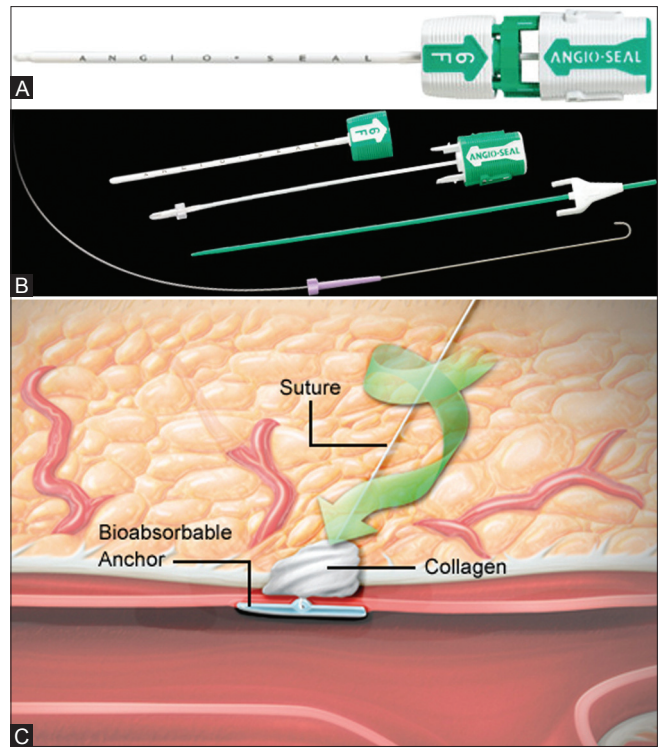
Prior to the introduction of arterial closure devices, all patients who had common femoral arterial puncture required manual compression of the puncture site for up to 20 min and bed rest for up to 12 h to achieve hemostasis.<sup>[7]</sup> This was often associated with re-bleeding at the puncture site.

**Angioseal**

The Angioseal vascular closure device [Figure 1A and B] closes the defect in the common femoral arterial wall by percutaneous access through a sheath. It comprises an absorbable polymer anchor (D, L-lactide co-glycolide polymer) deployed intra-arterially, a small collagen sponge plug positioned in the arteriotomy, and a self-tightening suture trimmed below the skin. Hemostasis is achieved by compressing the collagen plug between the anchor and the suture, which is supplemented by the coagulation inducing properties of the collagen [Figure 1C].<sup>[12]</sup> All the Angioseal components are absorbed within 60-90 days.<sup>[4,13]</sup>

The Angioseal device complications have been extensively evaluated and the adverse effects have been divided [Table 1].<sup>[15]</sup>

This study is a retrospective review of a patient cohort who underwent diagnostic angiography or percutaneous intervention with puncture of the CFA, in whom the 6F VIP



**Figure 1 (A-C):** (A) Angioseal device.<sup>[14]</sup> (B) Angioseal device components.<sup>[14]</sup> (C) Collagen plug<sup>[14]</sup>

**Table 1: Adverse effects of Angioseal<sup>[15]</sup>**

Major complications	Minor complications
Vascular repair	Hematoma > 6 cm
Late GI bleeding requiring transfusion	Infection
Infection with hospitalization	AV fistula
False aneurysm requiring intervention	DVT
DVT requiring intervention	Vasovagal response
AV fistula requiring intervention	Device non-deployment
Retroperitoneal bleed requiring intervention	Device malfunction

AV: Arterio-venous, DVT: Deep vein thrombosis, GI: Gastrointestinal

STS Angioseal vascular closure device was used. Specifically we look at the complication rates, types of complications, and the overall efficacy.

**Materials and Methods**

The study data were collected at a busy district general hospital over two tertiary care centers, with a moderate volume of interventional vascular procedures.

The radiological reports and medical notes of 147 patients, who were referred to two interventional radiologists for diagnostic angiography or percutaneous intervention, between January 2008 and October 2009, were reviewed.

Information recorded included patient age, gender, and procedure type. With regard to the procedure itself, puncture direction, complications of Angioseal deployment, time from removal of sheath to hemostasis

and whether hemostasis was successful or not were assessed.

Data were collected on whether patients were receiving antiplatelet or anticoagulant therapy. Information was gathered as to what therapy or combination of therapy the patients were taking at the time of the procedure.

All procedures were carried out under standard conditions by two experienced interventional radiologists, using the same 6F VIP STS Angioseal device.

In all patients, closure of the puncture site took place in the interventional radiology room immediately after the procedure. The guidewire provided with the Angioseal set was passed through the arterial sheath. Manual pressure was applied at the puncture site and the sheath was carefully removed over the wire. The 6F Angioseal sheath was then passed over the wire and placed into the artery. The anchor was set in position by deploying the device through the sheath. The anchor was then pulled back gently and the puncture sealed by pulling the self-tightening string. The string was then cut short to the skin.

## Results

There were 98 male patients and 49 female patients. The mean age of the patient group was 67 years, with a range of 36-98 years. A total of 157 CFA punctures were performed. Fifty-seven patients (38.7%) had a left-sided puncture, 80 patients (54.4%) had a right-sided puncture, and 10 patients (6.8%) had bilateral punctures [Table 2].

Out of the total 157 punctures, 122 (77.7%) were antegrade punctures and 35 (22.2%) were retrograde. There were a total of 157 procedures, 23 (14.6%) of which were

**Table 2: Patient information**

Gender	
Male	98
Female	49
Age (years)	
Mean	67
Range	36-98
Access side	
Left CFA	57
Right CFA	80
Both	10
Angiographic direction	
Antegrade	122
Retrograde	35
Procedure	
Diagnostic angiogram	23
Percutaneous intervention	134

CFA: Common femoral artery

diagnostic angiograms and 134 (85.3%) were interventional procedures [Table 2].

One major complication (0.75%) was a retroperitoneal hematoma in a female patient [Table 3]. The patient was an inpatient, who developed shortness of breath 4 days post angioplasty. On checking her hemoglobin level, it was found to be low, and a subsequent ultrasound scan revealed a large retroperitoneal hematoma. She was managed conservatively and was transfused 3 units of blood. She was discharged home 13 days post procedure after an uneventful recovery.

Of the minor complications, one (0.75%) included a superficial hematoma in a male [Table 3]. This was evacuated in theater 12 days after the interventional procedure. The patient made an uneventful recovery.

There were 2 (1.49%) minor complications relating to device malfunction, where the puncture site continued to ooze despite satisfactory deployment of the Angioseal device. These patients had manual compression for 20 min to achieve hemostasis.

In further 2 (1.49%) patients, the Angioseal device failed to deploy [Table 3]. One of these patients was noted to have multiple previous femoral punctures leading to a large amount of scar tissue. Again in these two patients, manual compression for 20 min was used to achieve satisfactory hemostasis.

Figures for time to haemostasis and successful deployment

**Table 3: Complications**

Adverse event	6F diagnostic (n=23) (%)	6F interventional (n=134) (%)
Minor complication		
Hematoma >6 cm	0	1 (0.75)
Infection	0	0
False aneurysm	0	0
AV fistula	0	0
DVT	0	0
Vasovagal response	0	0
Device non-deployment	0	2 (1.49)
Device malfunction	0	2 (1.49)
Total minor complication	0	5 (3.73)
Major complication		
Vascular repair	0	0
Late GI bleeding requiring transfusion	0	0
Infection with hospitalization	0	0
False aneurysm requiring intervention	0	0
AV fistula requiring intervention	0	0
Retroperitoneal bleed requiring intervention	0	1 (0.75)
Total major complication	0	1 (0.75)
Any complication	6 (3.82)	

AV: Arterio-venous, DVT: Deep vein thrombosis, GI: Gastrointestinal

can be seen in Tables 4 and 5. In 153 (97%) patients, hemostasis was achieved in less than 5 min, and in 155 (98.7%) patients the device was successfully deployed.

Out of all the complications (6-4.48%), four patients were males (66.6%) and two (33.3%) were females. Four (66.6%) were antegrade punctures and two (33.3%) were retrograde punctures. All the procedures resulting in any complications were interventional procedures.

Overall, out of 157 punctures, there were six total complications (3.8%) [95% CI = 0.8-6.8%]. Five out of these six patients were on Aspirin 75 mg and Clopidogrel 75 mg and the other patient was on Aspirin 75 mg and Dipyridamole 200 mg.

A total of 90 (61%) patients were on antiplatelet or anticoagulant therapy, and 57 (39%) were not taking antiplatelet or anticoagulant therapy. The distribution of antiplatelet or anticoagulant therapy is seen in Table 6.

## Discussion

Before the advent of vascular closure devices, manual or mechanical compression of the puncture site followed by up to 12 h bed rest was commonplace in order to obtain satisfactory hemostasis.<sup>[5]</sup>

The disadvantages of this include patient discomfort from groin pressure for prolonged periods and bed rest. In addition, many of the patients undergoing such procedures, as in our series, have multiple comorbidities (e.g., respiratory or cardiac failure), where lying flat for such a period of time is not possible. There are also the disadvantages of increased workloads for medical and nursing staff and increased hospital stay, increasing bed demands.<sup>[16]</sup>

Angioseal offers many advantages, especially immediate hemostasis in less than 5 min in most cases, allowing early ambulation and hospital discharge leading to reduced requirements for hospital resources.<sup>[7]</sup> There have been studies showing Angioseal to reduce hospital stay and improve patient satisfaction.<sup>[17-20]</sup>

The disadvantages are the cost of the product, which is currently £80 for the type used at our institution. However, it is felt that this is largely offset by the reduced staff and bed requirement. There are various studies outside the UK which have reported cost benefit since the introduction of Angioseal into their practice.<sup>[2,21]</sup>

Other disadvantages include operator training and recognition of potential device-related complications.

We showed an overall efficacy rate of over 97% in both diagnostic and interventional subgroups. We also showed

**Table 4: Efficacy**

Time to hemostasis	6F diagnostic (n=23) (%)	6F interventional (n=134) (%)
Less than 5 min	23 (100)	130 (97)
Less than 10 min	0	0
Less than 20 min	0	4 (2.99)

**Table 5: Deployment**

Angioseal deployment	6F diagnostic (n=23) (%)	6F interventional (n=134) (%)
Successful deployment	23 (100)	132 (98.5)
Failure to deploy	0	2 (1.49)

**Table 6: Antiplatelet and anticoagulant therapy**

Drug	Number of patients
Aspirin	45
Clopidogrel	12
Warfarin	6
Low molecular weight heparin	1
Aspirin and Clopidogrel	19
Aspirin and Dipyridamole	4
Clopidogrel and Dipyridamole	1
Aspirin and Warfarin	1
Low molecular weight heparin and Clopidogrel	1

a major complication rate of just 0.75%, with no incidences of major vascular injury/occlusion necessitating surgery or intervention, fistula, infection, aneurysm, or incidences of late bleeding. Our minor complication rate was also low at 3.73%. The overall complication rate for diagnostic and interventional procedures was 3.8%.

The results obtained in our study have an incidence of vascular complications similar to or lower than those with manual compression. Popma *et al.* reported a 5.9% rate of vascular complications with hemostasis achieved through manual compression.<sup>[22]</sup>

The complication and device success rates obtained are comparable to previous studies which have been undertaken. In a meta-analysis of randomized and non-randomized controlled trial investigating collagen plug devices, Silber reported a success rate of 97% with a complication rate of 6.7% in Angioseal patients.<sup>[23]</sup> Compared to this data, we achieved a similar rate of device success and lower incidences of vascular complications, with especially less major complications.

Ninety (61%) patients undergoing procedures were on some form of anticoagulation, but the 6 (100%) patients who suffered complications were all on two antiplatelet medications. Although the numbers in this study are too small to draw significant conclusions, the role of antiplatelet therapy in Angioseal complications has been previously described.

Our high efficacy and low complication rate is similar if not better than those in previous studies.<sup>[1,5,7,22-24]</sup>

This study has important limitations in its retrospective and non-randomized nature. Criteria to select patients for Angioseal were biased by the operator, whose decision was based on clinical factors. We also do not have equivalent numbers within the diagnostic and interventional subgroups.

Despite these drawbacks, we conclude that in our experience, vascular access site closure with Angioseal is safe, efficient, and uncomplicated, resulting in more favorable patient outcomes with acceptable levels of patient morbidity.

## References

- Duffin DC, Muhlestein JB, Allisson SB, Horne BD, Fowles RE, Sorensen SG, *et al.* Femoral arterial puncture management after percutaneous coronary procedures: A comparison of clinical outcomes and patient satisfaction between manual compression and two different vascular closure devices. *J Invasive Cardiol* 2001;13:354-62.
- Resin FS, Aurora N, Mathieu M, Reynolds MR. A cost minimisation analysis of the Angioseal vascular closure device following percutaneous coronary intervention. *Am J Cardiol* 2007;99:766-70.
- Heintzen MP, Stauer BE. Peripheral arterial complications after heart catheterisation. *Herz* 1998;23:4-20.
- Kussmaul WG 3<sup>rd</sup>, Buchbinder M, Whitlow PL, Aker UT, Heuser RR, King SB, *et al.* Rapid arterial haemostasis and decreased access site complications after cardiac catheterisation and angioplasty. *J Am Coll Cardiol* 1995;25:1685-92.
- Sesana M, Vaghetti M, Albiero R, Corvaja N, Martini G, Sivieri G, *et al.* Effectiveness and Complications of Vascular Access Closure Devices After Interventional Procedures. *J Invasive Cardiol* 2000;12:395-9.
- Patel RP, Jneid H, Derdeyn CP, Klein LW, Levine GN, Lookstein RA, *et al.* Arteriotomy closure devices for cardiovascular procedures. *Circulation* 2010;122:1882-93.
- Looby S, Keeling AN, McErlean A, Given MF, Geoghegan T, Lee MJ. Efficacy and safety of the Angioseal vascular closure device post antegrade puncture. *Cardiovasc Intervent Radiol* 2008;31:558-62.
- Yakubov SJ, Kahn JK, Bergman GW, Mewissen MW. Device reliability and safety using the Angioseal STS vascular closure device in interventional patients. *Am J Cardiol* 2001;88:32G
- Eggebrecht H, Haude M, Woertgen U, Schmermund A, von Birgelen C, Naber C, *et al.* Systematic use of a collagen-based vascular closure device immediately after cardiac catheterisation procedures in 1317 consecutive patients. *Catheter Cardiovasc Intervent* 2002;57:486-95.
- Schnyder G, Sawhney N, Whisenant B, Tsimikas S, Turi ZG. Common femoral artery anatomy is influenced by demographics and comorbidity: Implications for cardiac and peripheral invasive studies. *Catheter Cardiovasc. Intervent* 2001;55:289-95.
- Grier D, Hartnell G. Percutaneous femoral artery puncture: Practice and anatomy. *Br J Radiol* 1990;63:602-4.
- O'Sullivan GJ, Buckenham TM, Belli AM. The use of the Angioseal haemostatic puncture closure device in high risk patients. *Clin Radiol* 1998;54:51-5.
- Kensley KR. Puncture site haemostasis. *J Invasive Cardiol* 1994;6:273-6.
- St. Jude Medical, Angio-seal, Evolution are trademarks of St. Jude Medical, Inc. Or its related companies. Reprinted with permission of St. Jude Medical™, ©2013. All rights reserved.
- Chevalier B, Lancelin B, Koning R, Henry M, Gommeaux A, Pilliere R, *et al.* Effect of a closure device on complication rates in high-local-risk-patients: Results of a randomised multicenter trial. *Catheter Cardiovasc Interv* 2003;58:285-91.
- Park Y, Roh HG, Choo SW, Lee SH, Shin SW, Do YS, *et al.* Prospective comparison of collagen plug (Angioseal) and suture mediated (Closure S) closure devices at the femoral access sites. *Korean J Radiol* 2005;6:248-55.
- Moran T. Increased throughput, staff efficiencies and patient comfort with the use of the Angioseal device. *Cath Lab Digest* 2001. *Current Innovations in Vascular Sealing Supp*: 16-18.
- Lowrie M. Closing femoral artery punctures: A new approach. *Cath Lab Digest* 1995;3:6.
- Yee KM, Lazzam C, Richards J, Ross J, Seidelin PH. Same day discharge after coronary stenting: A feasibility study using a haemostatic femoral puncture closure device. *J Interv Cardiol* 2004;17:315-20.
- Upponi SS, Ganeshan AG, Warakaulle DR, Phillips-Hughes J, Boardman P, Uberoi R. Angioseal versus manual compression for haemostasis following peripheral vascular diagnostic and interventional procedures: A randomised controlled trial. *Eur J Radiol* 2007;61:332-4.
- Sumter D, Sivadon A, Lorenz L. The path of least resistance: How Angioseal helped one lab find the road to better economic performance. *Cath Lab Digest* 2004;12:3.
- Popma JJ, Satler LF, Pichard AD, Kent KM, Campbell A, Chuang YC, *et al.* Vascular complications after balloon and new device angioplasty. *Circulation* 1993;88:1569-78.
- Sibler S. Haemostasis success rates and local complications using collagen after femoral access for cardiac catheterisation. *Am J Heart* 1998;135:152-6.
- Ratnam LA, Raja J, Munneke GJ, Morgan RA, Belli AM. Prospective non randomised trial of manual compression and Angioseal Starclose arterial closure devices in common femoral punctures. *Cardiovasc Interv Radiol* 2007;30:182-8.

**Cite this article as:** Modi S, Gadvi R, Babu S. Initial experience with Angioseal™ : Safety and efficacy of the endovascular closure device. *Indian J Radiol Imaging* 2013;23:134-8.

**Source of Support:** Nil, **Conflict of Interest:** No.