

A simplified staging system based on the radiological findings in different stages of ochronotic spondyloarthropathy

Isaac Jebaraj, Binita Riya Chacko¹, George Koshy Chiramel¹, Thomas Matthai, Apurve Parameswaran

Departments of Orthopedics, and ¹Radiology, Christian Medical College, Vellore, Tamil Nadu, India

Correspondence: Dr. Isaac Jebaraj, Department of Orthopedics, Christian Medical College, Vellore, Tamil Nadu - 632 004, India.

E-mail: ijebaraj51@gmail.com

Abstract

This study describes a group of 26 patients with ochronotic spondyloarthropathy who were on regular treatment and follow-up at a tertiary level hospital and proposes a simplified staging system for ochronotic spondyloarthropathy based on radiographic findings seen in the thoracolumbar spine. This proposed classification makes it easy to identify the stage of the disease and start the appropriate management at an early stage. Four progressive stages are described: an inflammatory stage (stage 1), the stage of early discal calcification (stage 2), the stage of fibrous ankylosis (stage 3), and the stage of bony ankylosis (stage 4). To our knowledge, this is the largest reported series of radiological description of spinal ochronosis, and emphasizes the contribution of the spine radiograph in the diagnosis and staging of the disease.

Key words: Alkaptonuria; ochronosis; spine

Introduction

Alkaptonuria was first described as a metabolic disorder by Garrod in 1902^[1,2] and has a very low prevalence of 1:250,000 in most ethnic groups.^[3,4] It is an autosomal recessive disorder of tyrosine and phenylalanine metabolism, caused by the absence of homogentisic acid oxidase, which results in the accumulation of homogentisic acid in the blood. An oxidized polymer of homogentisic acid gets deposited in the soft tissues, tendons, and cartilages, leading to arthropathy of the large joints and spine. The three stages of alkaptonuria are homogentisic aciduria, ochronosis, and ochronotic arthropathy.^[5] The spine is affected early with deposition of the polymer within the intervertebral discs. Changes are more severe in the thoracolumbar spine.^[5] There is fibrillation and loss of resilience of the cartilage, resulting in chronic

progressive inflammation, and secondary degenerative changes. Fibrous and bony ankylosis can develop resulting in significant disability. Spinal deformities include scoliosis, kyphosis, reduction in the range of movements, and loss of height. A limitation of chest expansion in the advanced stages could be misdiagnosed as ankylosing spondylitis.^[6]

Alkaptonuria is usually asymptomatic until the third decade. Dark stains due to discoloration of the urine may be seen in early childhood, but the diagnosis could be delayed until ochronosis has developed. Ochronotic deposits in the tendons and ligaments begin in the second decade. The polymer has a predilection for the cartilage and nucleus pulposus of the intervertebral discs. Deposition becomes extensive in the fourth decade and manifests as palmoplantar pigmentation, a cutaneous marker for alkaptonuria.^[7] The pinna is pigmented and shows nodular thickening. The pigmentation in the eye is seen as black spots in the sclera.^[8]

The spine is always involved in ochronosis, and the clinical presentation depends on the extent of spinal involvement. While mobility is preserved in the early stages of ochronotic spondyloarthropathy, it may mimic ankylosing spondylitis in the advanced stages. We propose a simplified staging

Access this article online

Quick Response Code:



Website:
www.ijri.org

DOI:
10.4103/0971-3026.113628

system for ochronotic spondyloarthropathy based on the radiographic findings of the thoracolumbar spine. A scoring system already exists for ochronotic spondyloarthropathy based on the radiographic findings in the large joints and spine.^[5] This simplified staging system [Table 1] is proposed based on the severity of findings on plain radiography of the dorsolumbar spine, since these segments are involved more commonly and at an earlier stage.^[5]

This is significant because early identification of the disease helps in timely and appropriate treatment. Antioxidants like Vitamin C may have a favorable effect on joint function.^[9] Antiresorptive drugs such as alendronate and ibandronic acid are unproven in ochronotic spine with osteopenia. The aim of treatment is to halt the gradual destruction of cartilage, arthritis, lumbosacral ankylosis, limitation of motion, and deterioration of bone. Recently, a new drug has been identified which inhibits 4-hydroxyphenylpyruvate dioxygenase which is the enzyme that produces homogentisic acid. This drug is Nitisinone (NTBC) whose chemical name is 2-(2-nitro-4-trifluoromethylbenzoyl)-1,3-cyclohexanedione and is sold under the brand name Orfadin.^[5] Nitisinone, at a dose of 1 mg/kg/day is safe and effective in tyrosinemia type 1 but has not yet been approved for use in alkaptonuria. A randomized controlled clinical trial is underway at the NIH Clinical Research Center at Bethesda to determine if 2 mg of nitisinone daily is beneficial for the joint symptoms of alkaptonuria. Treatment with nitisinone may be beneficial if started early with close monitoring of malylacetoacetic acid levels.^[10] This study describes a group of patients with ochronotic spondyloarthropathy who were on regular treatment and follow-up at a tertiary level hospital.

Materials and Methods

This was a retrospective study of patients with clinical and biochemical evidence of ochronosis who presented to the orthopedics clinic of our institution over a 12-year period (1998-2011) with complaints of low back ache. The patients included were found to be positive for homogentisic acid in the urine. All patients consented for clinical examination and underwent radiographs of the thoracolumbar spine.

Table 1: Modified staging system for ochronosis of the spine

Stage	Pathophysiology	Radiological findings
1	Early changes of inflammation	Normal spine/early changes of disc space reduction or endplate sclerosis
2	Early disc calcification	Calcification of three or fewer intervertebral discs
3	Fibrous ankylosis	Calcification of more than three intervertebral discs, sandwich spine appearance
4	Bony ankylosis	Bony fusion of most of the segments of the dorsolumbar spine

These patients could be classified into four progressive stages based on the radiographic findings of the thoracolumbar spine: An inflammatory stage (stage 1), the stage of early discal calcification (stage 2), the stage of fibrous ankylosis (stage 3), and the stage of bony ankylosis (stage 4).

Results

This study included 26 patients (20 males and 6 females) with ages ranging from 30 to 70 years. The majority of these patients were from the local Roma population where the prevalence of ochronosis is known to be high.

Two patients with minimal disc space reduction and endplate sclerosis were classified as stage 1 [Figure 1]. Two patients with disc space reduction, vacuum phenomenon, and disc calcification up to three discs were classified as stage 2 disease [Figure 2]. All the four patients in stages 1 and 2 were found to have normal bone density and spinal alignment.

Thirteen patients with calcification of more than three intervertebral discs, reduction of disc space, vacuum phenomenon, and the “sandwich spine” appearance^[7] were classified as stage 3 disease [Figure 3]. Nine patients with obliteration of the disc spaces and fusion of the vertebrae were classified as stage 4 disease [Figure 4]. Most of the patients in stages 3 and 4 had osteopenia. All except three

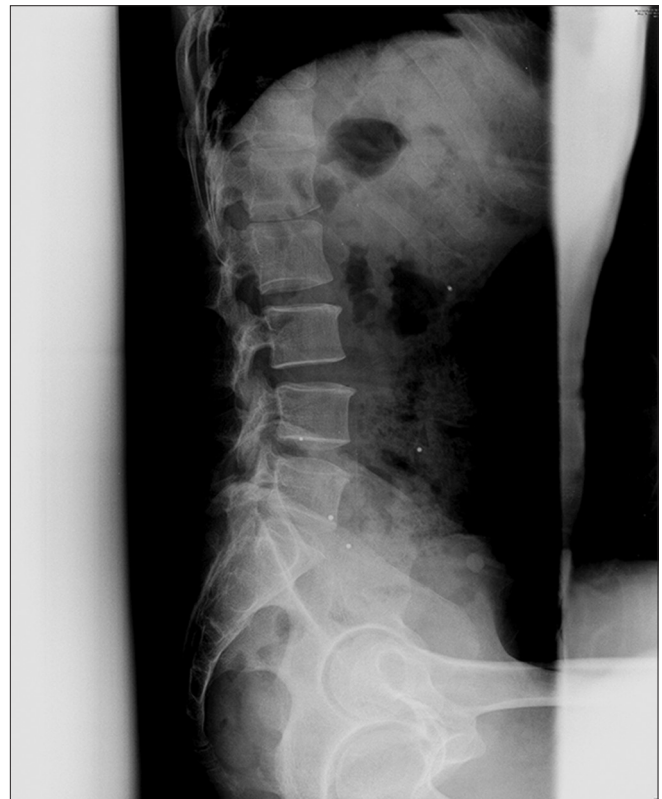

Figure 1: Lateral radiograph of the lumbar spine showing disc space reduction and endplate sclerosis (stage 1)

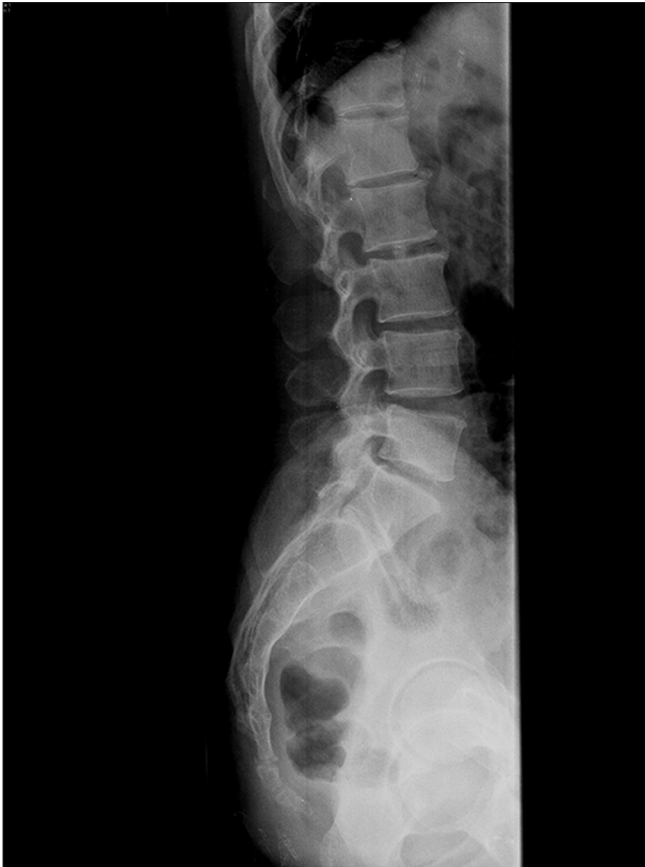

Figure 2: Lateral radiograph of the lumbar spine showing vacuum phenomenon and early changes of disc calcification involving less than three intervertebral discs (stage 2)

had kyphoscoliosis, while two had lumbar retrolisthesis. One patient with very osteopenic vertebrae had a compression fracture of the T12 vertebral body [Figure 5], which is a rare finding in ochronotic spondyloarthropathy.

None of the patients had anterior longitudinal ligament calcification or syndesmophytes on plain radiographs. Sacroiliac joints were normal in most patients. One had bony ankylosis of both sacroiliac joints, while another had mild sclerosis along the right sacroiliac joint. Two had vacuum phenomenon in the sacroiliac joints, suggestive of degenerative changes.

Discussion

In a developing country where no neonatal screening program exists for alkaptonuria, a patient may remain undiagnosed until he/she presents with low backache. A radiograph is a simple and reliable diagnostic test which helps the physician to consider this diagnosis. When diagnosed early, it may be possible to delay or prevent further complications.

In stage 1, the radiological changes were similar to those seen in age-related degenerative changes except that they were seen at an earlier age.

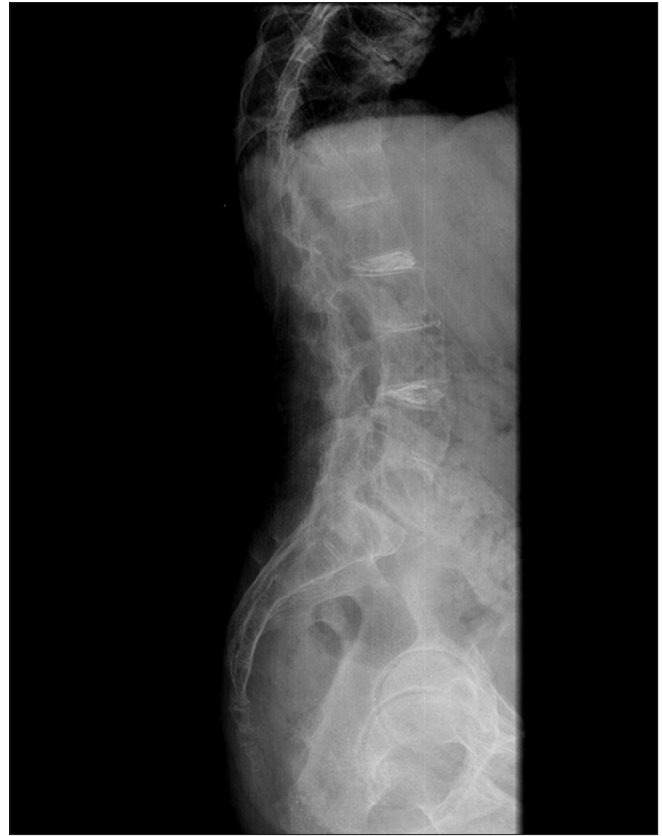

Figure 3: Lateral radiograph of the lumbar spine showing reduction of disc space, vacuum phenomenon, and calcification of more than three intervertebral discs - the "sandwich spine" appearance (stage 3)

In stage 2, the radiological findings included speckled disc calcification involving less than three vertebrae. There was a remarkable absence of osteophytes, which are seen in age-related spondylosis. Disc calcifications involving a few intervertebral discs can also occur in a variety of conditions with altered biochemical parameters or altered mechanics of the spine, such as advanced degenerative changes, post-trauma, post-spinal fusion, ankylosing spondylitis, hyperparathyroidism, hemochromatosis, calcium pyrophosphate deposition, hypervitaminosis D, juvenile chronic arthritis, amyloidosis, poliomyelitis, acromegaly, and prolonged immobilization.^[11]

The prevalence of disc calcification in conventional radiographs is 6-7%^[12] and is known to increase with age. Degenerative disc calcification usually occurs in the annulus fibrosus (60%), more commonly in the lower thoracic spine.^[12] In contrast to this, the disc calcification in spinal ochronosis is seen as lamellar calcification of the nucleus pulposus, which begins in the lumbar discs with ascending involvement. The cervical spine is typically spared in ochronosis.^[13] Disc calcification in pseudogout, hemochromatosis, and hypervitaminosis D is commoner in the annulus fibrosus than in the nucleus pulposus.^[12] In hemochromatosis, the spinal degenerative changes are comparable to the expected changes for that age group and calcific deposits may occur

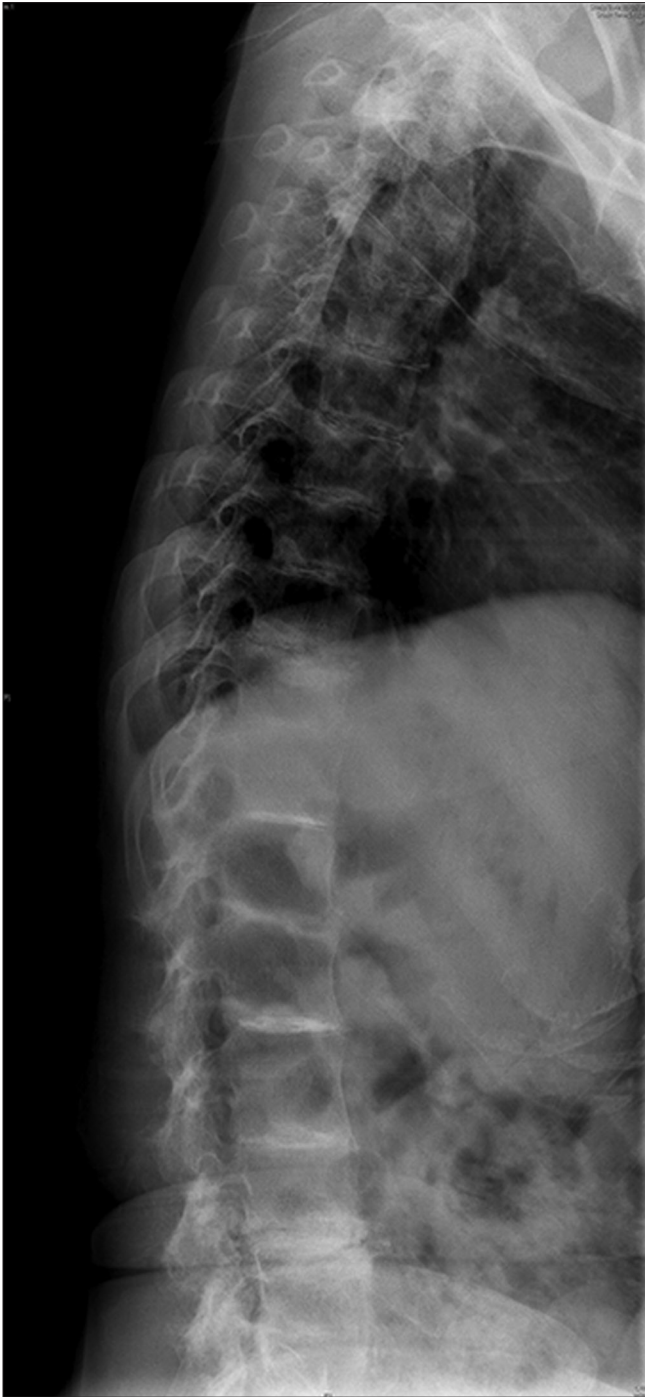


Figure 4: Lateral radiograph of the thoracolumbar spine showing obliteration of the disc spaces and bony fusion of most of the segments (stage 4)

in the ligamentum flavum in addition to the intervertebral discs.^[12,14] It was observed that the patients with early stages of spinal involvement in ochronosis were not the youngest, which suggests that the spinal changes could be related to the severity of ochronosis in terms of the high levels of homogentisic acid and poor renal clearance.

In stage 3, the disease shows a 'sandwich spine' appearance

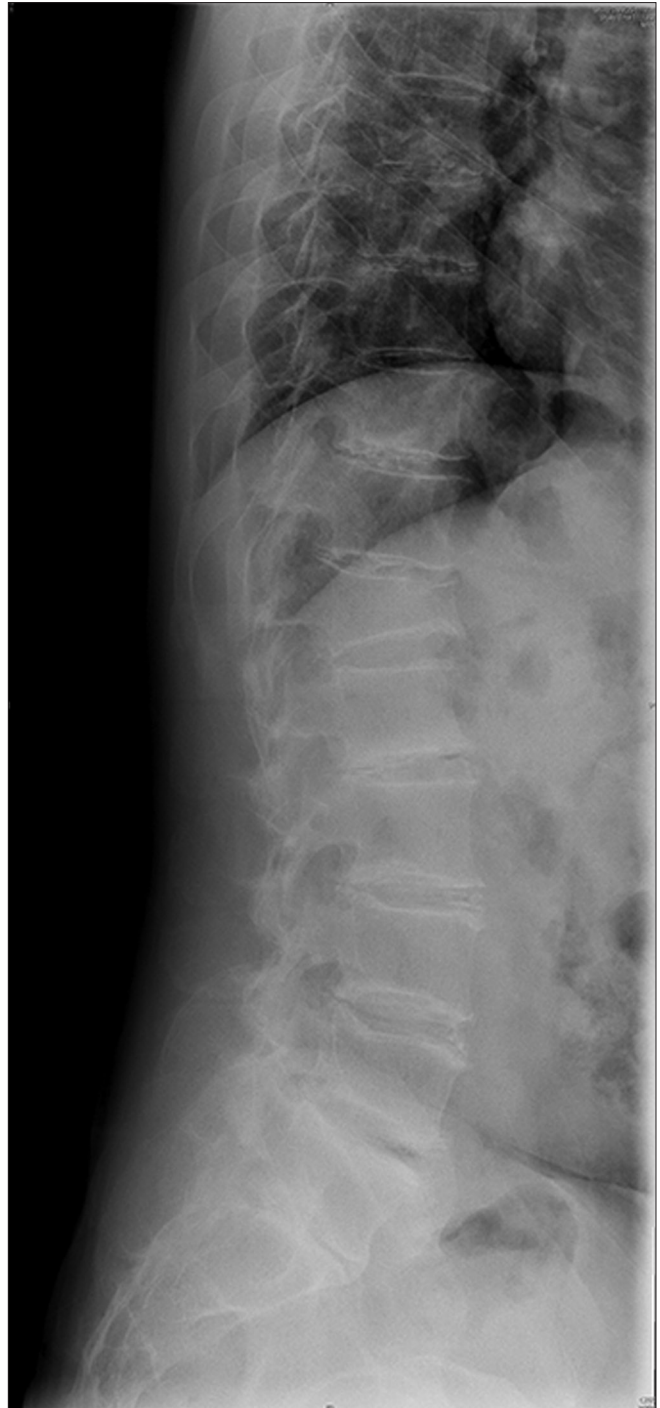


Figure 5: Lateral radiograph of the thoracolumbar spine showing severe osteopenia and anterior wedge compression fracture of T12 vertebral body in a patient with ochronotic spondyloarthropathy

in the lateral view radiograph^[7] which is pathognomonic for ochronosis of the spine. This appearance is due to the deposition of radioopaque pigment polymer and the calcium hydroxyapatite crystals.^[15]

In stage 4, late changes of ochronosis are seen and could resemble ankylosing spondylitis. The typical radiological changes of ankylosing spondylitis are squaring of vertebral

bodies, syndesmophytes that are described as gracile vertical bridging osteophytes, facet joint involvement, and bilateral sacroiliitis. Osteophytes may be seen in ochronosis, but are meagre, more horizontally oriented, and are different from the syndesmophytes typical of ankylosing spondylitis. As the spinal changes progress in ankylosing spondylitis, the classical bamboo spine appearance occurs with fusion of both facet joints and sacroiliac joints. These joints are usually spared in ochronosis, although degenerative changes are seen occasionally. One patient in this study had bony ankylosis of both sacroiliac joints, which is a rare finding in ochronosis.^[13]

Conclusion

Ochronotic spondyloarthropathy is a progressive disease, and a simplified staging system based on the extent of involvement of the thoracolumbar spine as visualized on the lateral radiographs has been described. This study emphasizes the contribution of the radiograph of the spine in the diagnosis and staging of the disease. This is a reliable indicator of the disease and is important especially in developing countries due to the high cost of CT and MRI scans.

References

1. Garrod AE. Croonian lectures on inborn errors of metabolism, lecture II: Alkaptonuria. *Lancet* 1908;2:73-9.
2. La Du BN, Zannoni VG, Laster L, Seegmiller JE. The nature of the defect in Tyrosine metabolism in Alkaptonuria. *J Biol Chem* 1958;230:250-60.
3. Zatková A, de Bernabé DB, Poláková H, Zvarík M, Feráková E, Bosák V, *et al.* High frequency of alkaptonuria in Slovakia: Evidence for the appearance of multiple mutations in HGO involving different mutational hot spots. *Am J Hum Genet* 2000;67:1333-9.
4. Ranganath L, Taylor AM, Shenkin A, Fraser WD, Jarvis J, Gallagher JA, *et al.* Identification of alkaptonuria in the general population: A United Kingdom experience describing the challenges, possible solutions and persistent barriers. *J Inherit Metab Dis* 2011;34:723-30.
5. Phornphutkul C, Introne WJ, Perry MB, Bernardini I, Murphey MD, Fitzpatrick DL, *et al.* Natural history of alkaptonuria. *N Engl J Med* 2002;347:2111-21.
6. Kabasakal Y, Kiyici I, Ozmen D, Yagci A, Gumusdis G. Spinal abnormalities similar to ankylosing spondylitis in a 58-year-old woman with ochronosis. *Clin Rheumatol* 1995;14:355-7.
7. Isaac J, Rao A. Cutaneous markers in ochronosis. *Indian J Med Sci* 2005;59:211-3
8. Osler W. Ochronosis: The pigmentation of cartilages, sclerotics and skin in alkaptonuria. *Lancet* 1904;1:10.
9. Morava E, Kosztolányi G, Engelke UF, Wevers RA. Reversal of clinical symptoms and radiographic abnormalities with protein restriction and ascorbic acid in alkaptonuria. *Ann Clin Biochem* 2003;40:108-11.
10. Introne WJ, Perry MB, Troendle J, Tsilou E, Kayser MA, Suwannarat P, *et al.* A 3-year randomized therapeutic trial of nitisinone in alkaptonuria. *Mol Genet Metab* 2011;103:307-14
11. Balaban B, Taskaynatan M, Yasar E, Tan K, Kalyon T. Ochronotic spondyloarthropathy: Spinal involvement resembling ankylosing spondylitis. *Clin Rheumatol* 2006;25:598-601.
12. Chanchairujira K, Chung CB, Kim JY, Papakonstantinou O, Lee MH, Clopton P, *et al.* Intervertebral disk calcification of the spine in an elderly population: Radiographic prevalence, location, and distribution and correlation with spinal degeneration. *Radiology* 2004;230:499-503.
13. Baeva M, Bueno A, Dhimes P. AIRP best cases in radiologic-pathologic correlation: Ochronosis. *Radiographics* 2011;31:1163-7.
14. Bywaters EG, Hamilton EB, Williams R. The spine in idiopathic haemochromatosis. *Ann Rheum Dis* 1971;30:453-65.
15. Alkaptonuria, Resnick D, In: Resnick D, editor. *Diagnosis of bone and joint disorders*. 4th ed. Philadelphia: Saunders; 2002. p. 1678-9.

Cite this article as: Jebaraj I, Chacko BR, Chiramel GK, Matthai T, Parameswaran A. A simplified staging system based on the radiological findings in different stages of ochronotic spondyloarthropathy. *Indian J Radiol Imaging* 2013;23:101-5.

Source of Support: Nil, **Conflict of Interest:** None declared.