

MRI enterography with divided dose oral preparation: Effect on bowel distension and diagnostic quality

Rakesh Sinha, Sudarshan Rawat¹

Department of Radiology, GI Unit, South Warwickshire NHS Trust and Warwick Medical School, Lakin Road, Warwick CV34 5BW, England, ¹Department of Radiology, Ruby Hall Clinic, Pune, India

Correspondence: Dr. Rakesh Sinha, Department of Clinical Radiology, Warwick Hospital, Warwick CV34 5BW, England.
E-mail: rakslide@gmail.com

Abstract

Aim: To assess the impact of an extended oral preparation magnetic resonance (MR) enterography protocol on bowel distension, timing of imaging, and the quality of diagnostic images. **Materials and Methods:** An analysis of 52 patients who underwent divided oral preparation and 39 patients who underwent standard preparation for MR enterography examination was done. Distension was assessed by measuring the transverse diameters of the jejunum, ileum, and the ileocecal region. Diagnostic quality of the examination was assessed subjectively by two radiologists and graded as poor, diagnostic, and excellent (Grades 1-3). Correlation between bowel diameter and diagnostic quality was assessed using regression analysis. **Results:** The mean diameters of the jejunum, ileum, and colon in patients who underwent divided preparation were 1.90 ± 0.47 , 2.14 ± 0.41 , and 4.27 ± 0.96 cm, respectively, and the mean diameters in patients who underwent standard preparation were 1.46 ± 0.47 , 2.02 ± 0.47 , and 4.45 ± 0.90 cm, respectively. A total of 96.6% of patients on divided dose had diagnostic distension of the bowel (Grades 2 and 3). A total of 87.9% of the patients on standard dose had diagnostic distension of the bowel (Grades 2 and 3). A greater number of patients who underwent divided preparation had diagnostic quality examinations compared to those given standard preparation (96.6% vs. 87.9%). A greater number of patients who underwent divided preparation had Grade 3 quality examinations compared to those on standard preparation (75.5% vs. 68.5%). There was significant difference between diagnostic (Grades 2 and 3) and optimal grades (Grade 3) of the jejunal diameters in patients having divided or standard preparation (89.7% vs. 66.6%, $P < 0.05$; 40.8% vs. 25%, $P < 0.05$, respectively). Linear regression showed a positive correlation between increasing bowel diameter and diagnostic grade of the examination ($\rho = 0.76$). **Conclusion:** Using an extended oral preparation with divided dose resulted in the majority of patients being scanned in a single visit to the MRI suite. Dividing the oral contrast into aliquots can promote uniform distension of the entire small bowel and provide better bowel distension and improve the diagnostic quality.

Key words: Enterography, MRI, small intestine

Introduction

Magnetic resonance (MR) imaging is being increasingly used in the diagnostic workup of small bowel abnormalities.

The advantages of MR imaging include its inherent tissue contrast resolution, multiplanar (MPR) capabilities, and lack of radiation. Real-time imaging for peristaltic activity, dynamic contrast studies, and visualization of intraluminal, mural, and extramural components are also possible with MR examinations.

Traditionally MR examination of the small bowel has been performed after distension of the intestine by infusion of contrast agents through a naso-jejunal tube (enteroclysis technique). However, this technique is associated with significant patient discomfort and ionizing radiation is still used during positioning and manipulation of the catheter.

Access this article online

Quick Response Code:



Website:
www.ijri.org

DOI:
10.4103/0971-3026.113623

Another method of producing uniform bowel opacification is by application of an enterographic examination. In an enterographic examination, the small bowel is opacified by ingestion of the larger volumes of enteral contrast medium. Recent studies have indicated similar diagnostic accuracies for MRI enterography (MRE) and MR enteroclysis examinations.

The aim of this study was to determine the efficacy of an extended oral preparation in distension and opacification of the bowel and to assess the number of visits to the MR scanner made by patients during the examinations. Diagnostic quality of the MR images was also assessed in the patients undergoing this protocol.

Materials and Methods

Evaluation was done of 52 consecutive MRE examinations from a single institute, performed over a 4-month period (April-July 2007).

Preparation prior to examination

Our specific protocol for MRE requires the patient to undertake a low-residue diet for the preceding 5 days and fast for 6 h before the procedure. This decreases the possibility of foreign bodies or food particles being mistaken for mass lesions or polyps, and the low-residue diet promotes reduction of fecal matter in the colon that can facilitate transit of the small bowel contrast. Patients who were acutely unwell and admitted to the hospital did not undergo the 5-day low-residue diet, but fasted for 6 h prior to the MRE examination.

Oral ingestion protocol

Divided dose preparation

On arrival at the radiology department, patients were asked to drink 1200-1300 ml of 3% mannitol solution (Blackburn Ltd, Nelson, UK) over 50 min. The oral contrast material was divided into two aliquots, and patients were asked to drink each portion over 25 min. An oral suspension of 10 mg of metoclopramide was given with the first aliquot to promote gastric emptying. Just before imaging, patients are asked to drink another 200 ml of the contrast material to opacify the stomach and duodenum.

Standard preparation

On arrival at the radiology department, patients were asked to drink 1200-1300 ml of 3% mannitol solution over 50-55 min. An oral suspension of 10 mg of metoclopramide was given with the first aliquot to promote gastric emptying.

Imaging protocol

After completion of the oral phase at 60 min, a thick slab (70 mm) half-Fourier acquisition single-shot turbo spin-echo (HASTE) sequence was performed to determine whether the oral contrast had reached the ileocecal junction.

If the ileocecal junction was opacified, an intravenous injection of 20 mg of hyoscine-*N*-butylbromide (Buscopan) was administered to minimize bowel peristalsis. If the contrast had not reached the ileocecal region, a further visit to the MRI scanner was planned at subsequent 20 min until the ileocecal region was opacified.

All examinations were then performed using a Symphony 1.5 T machine (Siemens Medical Solutions, Erlangen, Germany). For the imaging of the bowel, high-resolution ultra-fast sequences such as true fast imaging with steady-state precession (trueFISP) and HASTE sequences with and without fat suppression were used.

Imaging evaluation

The diagnostic quality of bowel opacification was assessed by gastrointestinal radiologists (RS >7 years) and (SR >2 years) experienced in interpreting MR imaging of the small bowel (RS, SR). The jejunal and ileal loops were reviewed independently for distension which was graded on the basis of bowel diameter. Three separate measurements of the jejunum, ileum, and the cecum were recorded and analyzed for this study. In patients with previous resection of the cecum, measurements were taken from the ascending colon distal to the ileocolic anastomosis. A mean value of the three measurements was taken to minimize operator error.

The measurements of bowel diameter were made on transverse sections and included the lumen and the bowel wall. In every instance, attempt was made to measure normal segments of the bowel, as diseased segments can have increased mural thickness, while obstructed segments have increased luminal dimensions. All measurements were made on axial trueFISP images with fat suppression. TrueFISP sequences were used for measurements because of the good resolution of the lumen and bowel wall obtained on these sequences. Measurements were made on fat-suppressed images to avoid the black boundary artifact that is seen on trueFISP images, which can result in overestimation of bowel thickness.

The MRE studies were graded into three categories by consensus as follows [Figures 1-3]:

- Grade 1: Most bowel segments non-opacified resulting in a non-diagnostic study
- Grade 2: Well-opacified bowel segments interspersed with few less-distended segments resulting in a diagnostic study, and
- Grade 3: Optimal bowel opacification of all segments enabling a confident diagnostic study.

Statistical evaluation

Statistical analysis was done using Prism and StatPlus: Mac (Graphpad Software Inc., La Jolla, CA, USA; Analystsoft Inc, Vancouver, Canada). Associations between

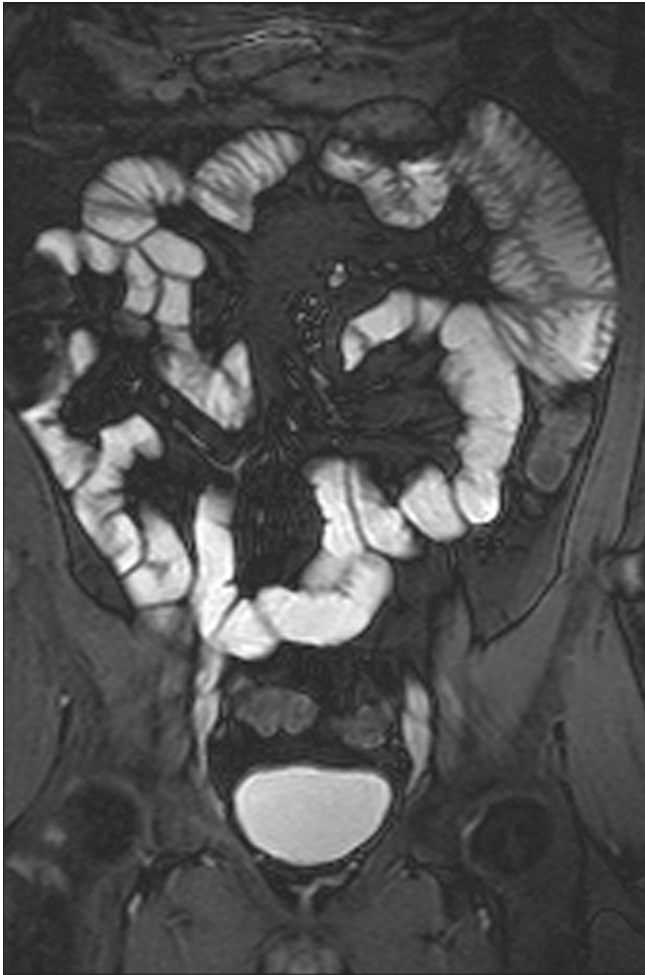


Figure 1: Optimal distension of the jejunum and ileum and right colon. This study was categorized as Grade 3

bowel diameter and diagnostic grade were assessed by the χ^2 , Spearman correlation coefficient, and regression analysis, as appropriate. Receiver Operating Characteristic (ROC) curves were generated to assess the accuracy of bowel diameter with diagnostic quality of examination. A $P < 0.05$ was considered statistically significant.

Results

A total of 50 patients were included in the extended preparation, whereas 39 were included in the standard preparation series. One out of the 50 and 3 out of the 36 patients could not complete the oral ingestion protocol and were therefore not included in this study. There were 46 males and 39 females (85) that were included in the study, with an average age of 42.3 years. Eight of the total of 85 patients were admitted in the hospital, and therefore did not undertake a low-residue diet, whereas 77 patients underwent the complete protocols.

Out of the four patients who did not complete the study, two patients found the oral contrast unpalatable while two

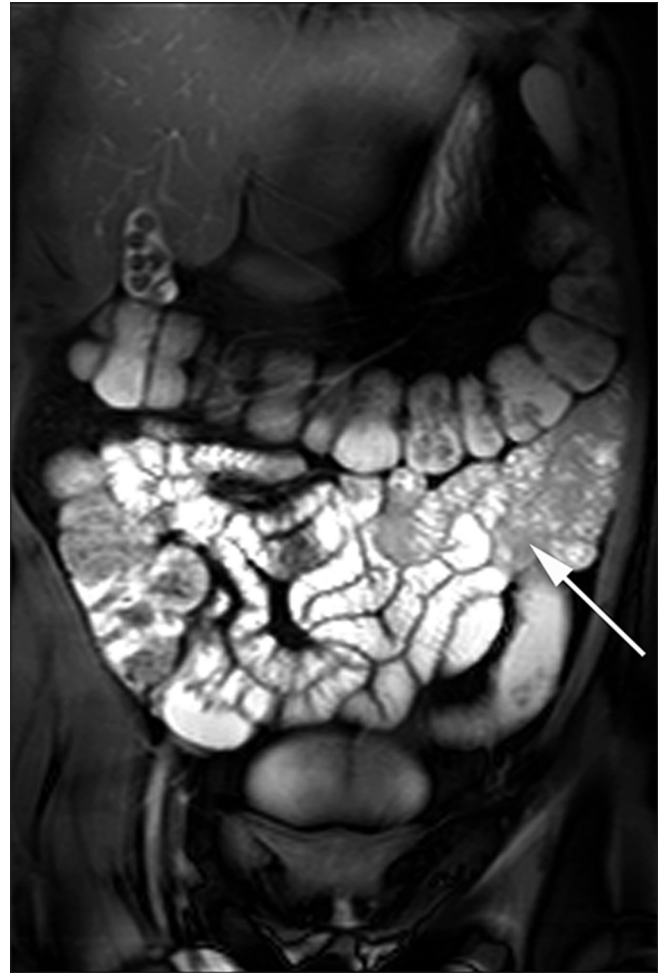

Figure 2: Optimal distension of the entire ileum and right colon. A few segments of the jejunum are not distended (arrow). This study was categorized as Grade 2 for the jejunum

patients were claustrophobic and thus could not comply with the imaging sequences.

Forty-nine of the imaging studies were normal, whereas 36 studies had abnormal findings [inflammatory bowel disease (32), infective enteritis and colitis (2), radiation enteritis (1), tumor (1)].

Divided dose

On imaging at 60 min, 48 (97.9%) studies showed the presence of contrast medium in the ileocecal region or beyond. In the one remaining patient (2.98%), contrast was present in the distal ileum on the first visit to the scanner. This patient needed a second visit to the scanner for completion of the imaging sequences. The mean number of visits to the MR table was 1.02 (range 1-2).

Minor diarrhea was reported after the examination by two patients and one episode of vomiting was reported by one patient. One patient reported abdominal pain, nausea, or prolonged vomiting. This patient had inflammatory strictures and the obstructive symptoms provoked by the

oral contrast subsided after 24 h and she did not require hospital admission.

Bowel distension and diagnostic quality

The mean distension of the jejunum, ileum, and colon was 1.90 ± 0.47 , 2.14 ± 0.41 , and 4.27 ± 0.96 cm, respectively. Five studies were recorded as non-diagnostic (Grade 1) and all these involved the jejunal segments [Figure 4]. All ileal and colonic segments were graded as having a diagnostic examination (Grades 2 and 3). A total of 96.6% of the patients were classified as having diagnostic distension of the bowel (Grades 2 and 3).

Standard dose

At 60 min, 34 (94.4%) studies showed the presence of contrast medium in the ileocecal region or beyond. In the two remaining patients contrast was present in the distal ileum on the first visit to the scanner. These patients needed a second visit to the scanner for completion of the imaging sequences. The mean number of visits to the MR table was 1.06 (range 1-2). Minor diarrhea was reported after the examination by three patients. One patient reported abdominal pain.

Bowel distension and diagnostic quality

The mean distension of the jejunum, ileum, and colon was 1.46 ± 0.47 , 2.02 ± 0.47 , and 4.45 ± 0.90 cm, respectively. Thirteen studies were recorded as non-diagnostic (Grade 1), and these involved the jejunal (12) and ileal (1) segments. All colonic segments and 35 ileal segments were graded as having a diagnostic examination (Grades 2 and 3). A total of 87.9% of the patients were classified as having diagnostic distension of the bowel (Grades 2 and 3).

There was no significant difference between the ileal and colonic diameters on divided and standard preparations. However, the jejunal distension showed a significantly greater diameter in patients who underwent the divided dose preparation ($P < 0.05$). A greater number of patients who underwent divided preparation had diagnostic quality examinations compared to those given standard preparation (96.6% vs. 87.9%). A greater number of patients who underwent divided preparation had Grade 3 quality examinations compared to those given standard preparation (75.5% vs. 68.5%). There was significant difference between diagnostic (Grades 2 and 3) and optimal grades (Grade 3) of the jejunal diameters in patients having divided or standard preparation (89.7% vs. 66.6%, $P < 0.05$) and (40.8% vs. 25%, $P < 0.05$), respectively.

Linear regression showed that there was positive correlation between increasing bowel diameter and diagnostic grade of the examination ($\rho = 0.76$) [Figure 5]. ROC curve analysis showed high accuracy for diagnostic grade examination with a bowel diameter >1.55 cm, with a sensitivity and specificity of 88% and 100%, respectively [area under

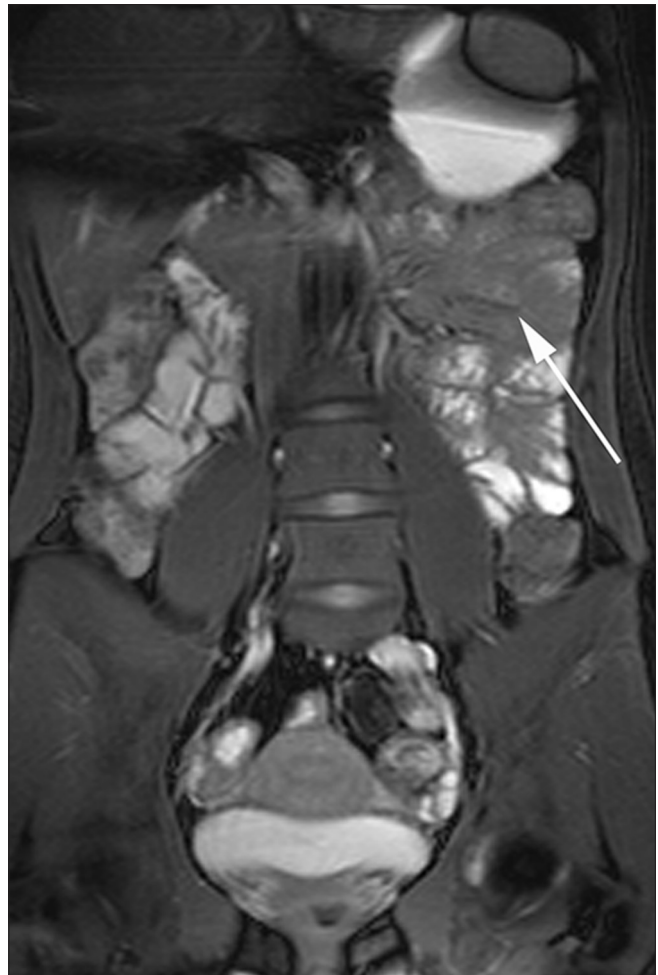


Figure 3: Poorly opacified jejunum (arrow) resulting in a non-diagnostic study. This study was categorized as Grade 1 for the jejunum

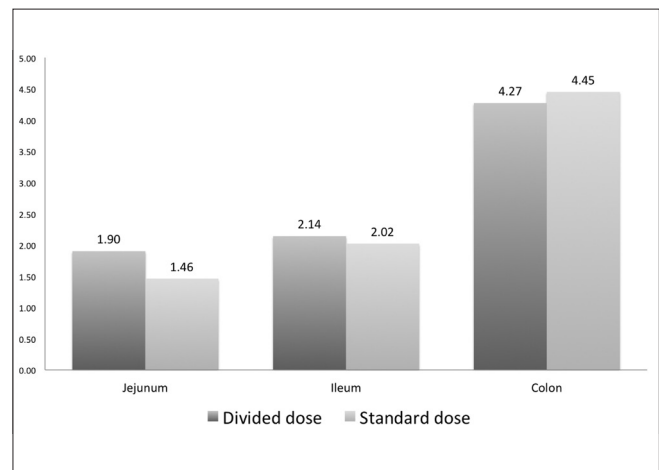


Figure 4: Bar graph showing diameters of jejunum, ileum, and colon with divided and standard oral preparations

curve (AUC) = 0.98 (0.97-1.0); $P < 0.0001$]. Grade 3 examination (optimal distension) was detected with a sensitivity and specificity of 80.3% and 100%, respectively, with a diameter >1.95 cm [AUC = 0.96 (0.93-0.98); $P < 0.0001$] [Figure 6].

Discussion

Distension and opacification of the small bowel is critical for a successful MRE examination.^[1] Opacification of the bowel is dependant on patient compliance, the amount of contrast ingested, and the timing of imaging. In particular, the intake of sufficient volumes of contrast medium combined with optimal timing of image acquisition is important.^[2-5] The importance of ingesting the contrast over the allocated time period is paramount, as delay in ingestion can result in majority of the contrast filling the colon, whereas reduced ingestion of the contrast can lead to suboptimal small

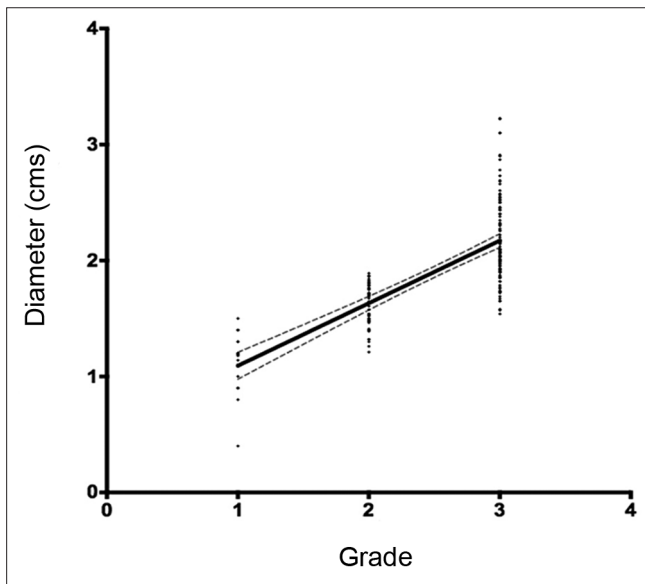


Figure 5: Regression plot (black line) shows correlation between increasing bowel diameter and diagnostic grade. Dashed line = 95% CI

bowel distension. Several studies have reported the use of different types of oral contrast which include solutions such as locust bean gum solution, mannitol solution, polyethyl glycol (PEG), and sorbitol.^[6-8] Mannitol solution has characteristics similar to that of water but is non-absorbable and non-metabolized, and therefore can produce optimal small bowel distension.^[1]

The majority of patients who underwent divided dose (97.9%) only needed one visit to the MRI suite for imaging; only one patient needed a further second visit. The patient who needed a second visit had ileal strictures which caused partial obstruction and delay in the transit of the oral contrast. Two patients who underwent standard preparation required a second visit to the scanner.

Majority of the patients who underwent divided preparation were graded as having optimal distension (Grade 3) of the ileum and right colon (87.6% and 100%, respectively). No patient had suboptimal or non-diagnostic opacification of the ileum or right colon. The distal small bowel (ileum and ileocecal region) consistently showed optimal or diagnostic bowel distension, and there were no recorded non-diagnostic studies of the ileum or colon. No significant differences were observed in bowel diameters of the colon and ileum on divided or standard preparation.

Suboptimal distension was observed in the jejunum in 5 patients (divided preparation) and 12 patients (standard preparation). Suboptimal distension of the jejunum is likely to be due to rapid transit of the oral contrast into the large bowel. Transit may also depend on various factors: Patients with inflammatory bowel disease may

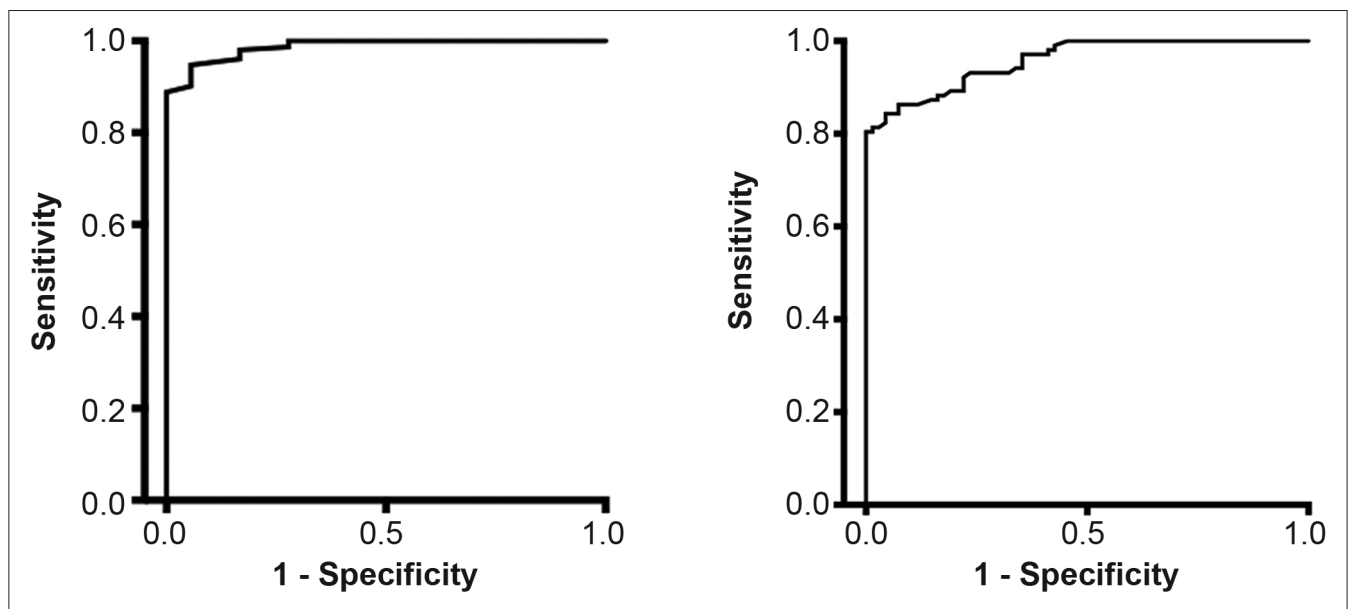


Figure 6: ROC plot for accuracy of bowel diameter compared to (a) diagnostic grade examinations [area under curve (AUC) = 0.98 (0.97-1.0); $P < 0.0001$] and (b) Grade 3 examinations [AUC = 0.96 (0.93-0.98); $P < 0.0001$]

have decreased transit times; osmotic effect of mannitol may cause rapid transit; a patulous ileocecal valve may facilitate transit into the colon; and, surgical procedures may reduce the length of the intestinal tract. A recent study has shown that PEG solution can reach the colon in 55 min.^[9] In the majority of patients with suboptimal distension of the jejunum, the head of the contrast column was present in the rectum. There was a significant improvement in diagnostic quality of images obtained in patients who underwent divided preparation. More patients had optimal distension (Grade 3) of the jejunum on divided preparation (40.8%) compared to standard preparation (25%).

It has been reported that the single most important factor in obtaining rapid transit of enteral contrast is a full stomach.^[10] Once oral contrast reaches the ileocecal junction, it causes distension of the terminal ileum. Distension of the terminal ileum can reduce peristalsis and bowel transit due to a neuronal and hormonal feedback mechanism. We hypothesize that the addition of a second dose of oral contrast fills the stomach and promotes peristalsis. Oral metoclopramide reaches its peak serum concentration at 20-30 min. Therefore, metoclopramide may help in maintaining gastric emptying by overriding the feedback mechanism.

The use of an extended period of drinking also promotes transit of enteral contrast and can produce uniform and consistent opacification of the proximal and distal small bowel. The first aliquot provided opacification of the distal small bowel and colon, whereas the second aliquot provided opacification of the proximal small bowel.

Poorer diagnostic quality and distension was seen in patients given standard preparation. Consistent distension of the bowel is not obtained due to several reasons. Firstly, the ingestion of contrast may not be constant - some patients may partake of the oral contrast during the initial part of the 60-min period and then wait for the MR imaging, while others who find the contrast unpalatable delay drinking until toward the end of the 60-min period. These approaches are not conducive to contrast and continuous distension of the bowel. By dividing the dose and closely monitoring the patients' drinking, this compliance factor is reduced.

Regression plots showed strong positive correlation of increasing bowel diameters and diagnostic image quality. ROC analysis showed that bowel diameter measurement of >1.95 cm was closely correlated with optimal (Grade 3)

image quality and was considered to be best for diagnostic interpretation.

This study again confirms the value of a divided dose oral contrast regimen to provide optimal distension in patient undergoing MRE examinations. Consistent, good-quality images of the small bowel can be obtained using this approach. Usage of this divided preparation can reduce the number of visits to the MR scanner and most patients could be scanned with only one visit to the MRI suite, thus maximizing scanner usage. However, this extended approach does require close supervision by the radiologist and higher compliance by the patients. It is therefore important that the oral ingestion is supervised by the radiologist or trained radiographer in charge of the examination in order to achieve consistently good results.

References

1. Sinha R, Verma R, Verma S, Rajesh A. MR enterography of Crohn disease: Part 1, rationale, technique, and pitfalls. *AJR Am J Roentgenol* 2011;197:76-9.
2. Sinha R. Recent advances in intestinal imaging. *Indian J Radiol Imaging* 2011;21:170-5.
3. Schreyer AG, Scheibl K, Heiss P, Feuerbach S, Seitz J, Herfarth H. MR colonography in inflammatory bowel disease. *Abdom Imaging* 2006;31:302-7.
4. Negaard A, Paulsen V, Sandvik L, Berstad AE, Borthne A, Try K, *et al.* A prospective randomized comparison between two MRI studies of the small bowel in Crohn's disease, the oral contrast method and MR enteroclysis. *Eur Radiol* 2007;17:2294-301.
5. Kuehle CA, Ajaj W, Ladd SC, Massing S, Barkhausen J, Lauenstein TC. Hydro-MRI of the small bowel: Effect of contrast volume, timing of contrast administration, and data acquisition on bowel distention. *AJR Am J Roentgenol* 2006;187:375-5.
6. Laghi A, Paolantonio P, Catalano C, Dito L, Carbone I, Barbato M, *et al.* MR imaging of the small bowel using polyethylene glycol solution as an oral contrast agent in adults and children with celiac disease: Preliminary observations. *AJR Am J Roentgenol* 2003;180:191-4.
7. Sinha R, Murphy P, Hawker P, Sanders S, Rajesh A, Verma R. Role of MRI in Crohn's disease. *Clin Radiol* 2009;64:341-52.
8. Sinha R, Rajiah P, Murphy P, Hawker P, Sanders S. Utility of high-resolution MR imaging in demonstrating transmural pathologic changes in Crohn disease. *Radiographics* 2009;29:1847-67.
9. Lohan D, Cronin C, Meehan C, Alhajeri AN, Roche C, Murphy J. MR small bowel enterography: Optimization of imaging timing. *Clin Radiol* 2007; 62: 804-7
10. Richard DG, Stevenson GW. Laxatives prior to small bowel follow through: Are they necessary for a rapid good-quality examination? *Gastrointest Radiol* 1990;15:66.

Cite this article as: Sinha R, Rawat S. MRI enterography with divided dose oral preparation: Effect on bowel distension and diagnostic quality. *Indian J Radiol Imaging* 2013;23:86-91.

Source of Support: Nil, **Conflict of Interest:** None declared.