

Utility of mobile devices in the computerized tomography evaluation of intracranial hemorrhage

Sridhar G Panughpath, Savith Kumar, Arjun Kalyanpur

Department of Emergency Radiology, Teleradiology Solutions Pvt Ltd., Bangalore, Karnataka, India

Correspondence: Dr. Sridhar G. Panughpath, Department of Emergency Radiology, Teleradiology Solutions Pvt Ltd., #7G, opp. Graphite India, Whitefield, Bangalore - 560 048, India. E-mail: sridhar.pg@telradsol.com

Abstract

Aim: To evaluate the utility of a mobile device to detect and assess intracranial hemorrhage (ICH) on head computed tomographs (CT) performed in the emergency setting. **Materials and Methods:** 100 head CT scans were randomly selected from our emergency radiology database and anonymized for patient demographics and clinical history. The studies were independently interpreted by two experienced radiologists in a blinded manner, initially on a mobile device (iPad, Apple computers) and subsequently, at an interval of one week, on a regular desktop workstation. Evaluation was directed towards detection, localization and characterization of hemorrhage. The results were assessed for accuracy, sensitivity, specificity and positive predictive value. Statistical significance was ascertained using Fisher's exact test. **Results:** 27 of the examinations were positive for ICH, of which 11 had multiple hemorrhages. Of these there were 17 subdural, 18 intraparenchymal, 8 subarachnoid, 4 intraventricular and 2 extradural hemorrhages. In 96 of the studies there was complete concurrence between the iPad and desktop interpretations for both radiologists. Of 49 hemorrhages, 48 were accurately detected on the iPad by one of the radiologists. In the remaining case, a tiny intraventricular hemorrhage was missed by both radiologists on the iPad as well as on the workstation, indicating that the miss was more likely related to the very small size of the hemorrhage than the viewer used. **Conclusion:** We conclude that in the emergency setting, a mobile device with appropriate web-based picture archiving and communication system (PACS) is effective in the detection of intracranial hemorrhage present on head CT.

Key words: Intracranial hemorrhage; iPad; mobile device

Introduction

With the advancement of mobile technology, development of newer applications for handheld devices, and the proliferation of broadband options, the gap between the real and virtual radiology department is decreasing day by day. Following the release of the iPad in 2010, much of the attention of researchers has been concentrated on the iPad, as it has high monitor spatial and contrast resolution,

robust battery life, and is extremely portable. These features add exceptional value in the setting of emergency radiology. Several authors have outlined the potential usefulness of hand-held devices for emergency computerized tomography (CT),^[1-3] intracranial hemorrhage (ICH),^[4] and renal colic.^[5] The objective of our study was to evaluate the utility of iPad in the interpretation of head CTs performed in the emergency/trauma setting for detection/assessment of ICH.

Materials and Methods

One hundred CT head studies were randomly selected from our archive and anonymized. A unique identification number was assigned to each study on the picture archiving and communication system (PACS) RADSpa™ (Telrad Tech Pvt. Ltd., Bangalore, India). A mobile platform of the same PACS was utilized for iPad (Apple Inc.) review.

Access this article online

Quick Response Code:



Website:
www.ijri.org

DOI:
10.4103/0971-3026.113610

The iPad^[6,7] review was compared with review on a two megapixel Dell UltraSharp™ 2007FP liquid crystal display (LCD) desktop monitor (Dell Inc.) [Table 1].

These studies were independently reviewed by two radiologists, who were blinded to the patient's clinical presentation. Initially both radiologists interpreted the studies on the iPad to assess for presence or absence of ICH. ICH was further categorized into extradural, subdural (SDH), subarachnoid, intraparenchymal, and intraventricular (IVH). Following a gap of 1 week, all studies were reviewed on the desktop workstation by both radiologists. All discordant studies were further assessed by two senior fellowship trained neuroradiologists.

Accuracy rate, sensitivity, specificity, positive and negative predictive values were calculated. Statistical significance was ascertained using Fisher's exact test.

Results

Of the 100 studies evaluated, 27 demonstrated intracranial bleeds [Figures 1 and 2]. Eleven of these studies had multiple bleeds, with a total of 49 on intracranial bleeds [Table 2]. There was complete (100%) concurrence between the iPad and desktop in 99 of the studies. Forty-eight of the 49 bleeds were detected by one of the radiologists on the iPad. A tiny IVH was missed by both radiologists on the iPad as well as on the desktop workstation [Figure 3]. A small isodense SDH was missed by one of the radiologists on the iPad.

Table 1: Comparison of iPad touch and monitor display specifications

	iPad	Monitor
Maximum luminance	388 cd/m ²	300 cd/m ²
Contrast ratio	881:1	800:1
Display resolution (in pixels)	1024×768	1600×1200
Screen type	In-plane switching liquid crystal display (IPS LCD) extended graphics array (XGA), Light emitting diode (LED) backlight	LCD
Interaction method	Touch	Mouse
Screen size (diagonal)	9.7 inches	20.1 inches
Aspect ratio	4:3	4:3

LCD: Liquid crystal display

Table 2: Distribution of ICH

Type of intracranial bleed	No.
Subdural	17
Extradural	2
Subarachnoid	8
Intraparenchymal	18
Intraventricular	4

ICH: Intracranial hemorrhage

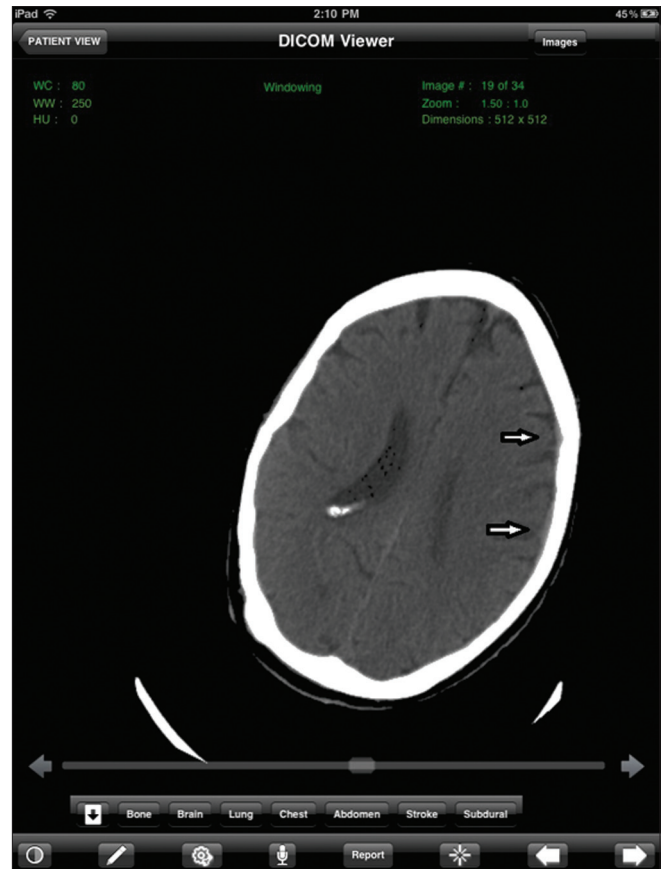


Figure 1: Axial computerized tomography section on an iPad at the level of the body of the lateral ventricles in subdural (SDH) window demonstrates a tiny left frontoparietal acute SDH (arrows)

The accuracy rate for the iPad and desktop workstation in detection of hemorrhage was 99.86% and 99.92%, respectively. The sensitivity, specificity, positive and negative predictive values of the iPad were 96%, 100%, 100%, and 99%, respectively. There was no statistically significant difference (P value <1.00) between the iPad and desktop workstation in detection of hemorrhage [Figure 4].

Discussion

The iPad holds great potential in medical imaging, especially for small matrix scans, such as CT, magnetic resonance imaging, and ultrasound, which have a spatial resolution of 512×512 pixels or less. The iPad has a resolution of 1024×768 pixels, therefore any small matrix scans can be viewed at their full resolution.

American College of Radiology recommends that a minimum contrast ratio for display device for images other than mammography should be more than 50:1.^[8] The contrast ratio of the iPad is significantly higher than this stipulated requirement at 881:1.^[7]

The iPad is portable and lightweight and is a powerful computing device with an intuitive interface. The other

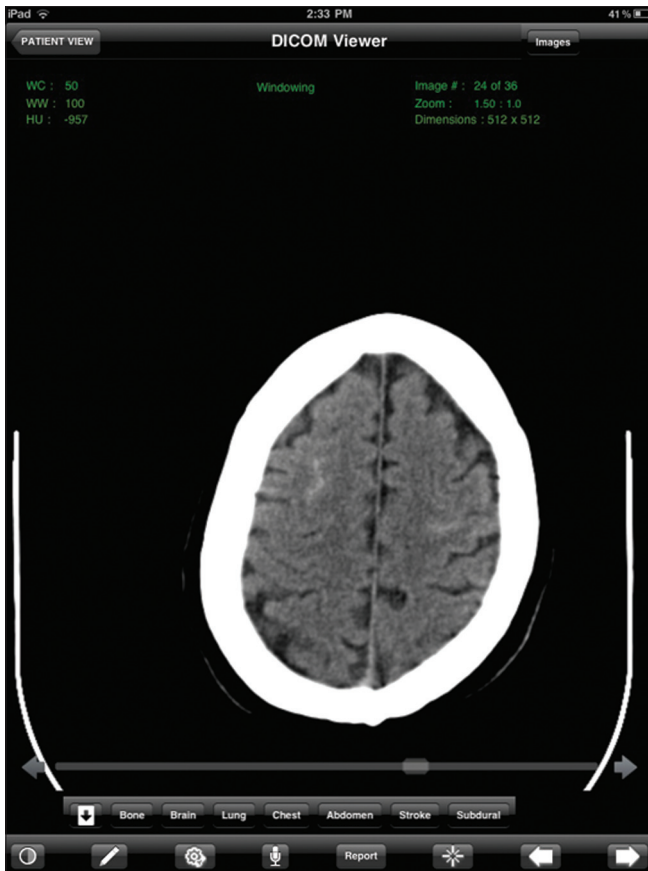


Figure 2: Axial computerized tomography image on an iPad at the level of the high frontal lobes demonstrates bilateral acute subarachnoid hemorrhage that was seen on only one image

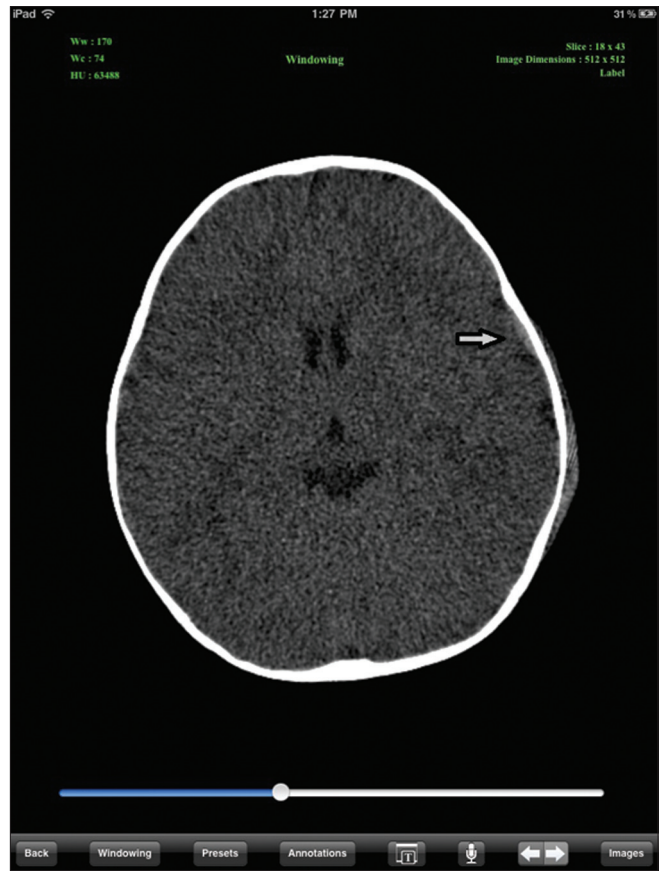


Figure 4: Axial computerized tomography section at the level of the thalamus on an iPad demonstrates a tiny left frontal acute extradural hematoma (arrow)

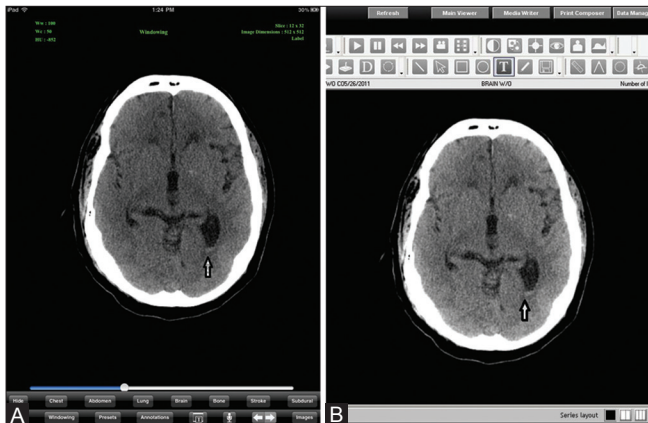


Figure 3 (A, B): Axial computerized tomography images at the level of the basal ganglia (A) on an iPad and (B) on a desktop workstation demonstrate a tiny acute intraventricular hemorrhage in the trigone of the left lateral ventricle (arrow)

advantage of the iPad is that it turns on quickly as compared to laptop or desktop workstation, which can be of great value in emergency radiology situations.

Mc Laughlin *et al.*^[9] demonstrated a 93% diagnostic agreement between general radiologists interpreting brain CT scans on an iPad and final reads by

neuroradiologists. Mitchell *et al.* had demonstrated 100% sensitivity, specificity, and accuracy in detecting IPH using the iPhone with a perfect interrater agreement ($K = 1$).^[10] Our findings are also similar to these published results.

There are certainly some limitations of iPad, as for instance, the relatively small screen size. iPad has the option of connecting over a wireless network if the physician is indoors. Further, with newer versions of the iPad that utilize 3G and 4G networks for image download, the speed of connectivity allows for interpretation from anywhere instantly.

There are some limitations of our study. All the iPad evaluations were conducted within our department where the ambient light is kept at a necessary minimum for radiologic interpretation. In a real-life scenario, during an emergency, the physician may not have the luxury of such a viewing ambience, which may limit his/her reading efficacy. Further, this was a relatively small study that included only 100 CTs, therefore additional generalizations about the clinical utility should be deferred until additional studies on larger series of data have been performed.

The results of our study indicate that the iPad may indeed be adequate for the display of small matrix radiological images, equaling the performance of desktop computers.

Conclusion

We conclude that in the emergency setting, a mobile device with appropriate web-based PACS is effective in the detection of ICH present on head CT and can be utilized to expedite diagnosis, especially in the background of radiologist shortages.

References

1. Toomey RJ, Ryan JT, McEntee MF, Evanoff MG, Chakraborty DP, McNulty JP, *et al.* Diagnostic efficacy of handheld devices for emergency radiologic consultation. *AJR Am J Roentgenol* 2010;194:469-74.
2. Yamamoto LG, Williams DR. A demonstration of instant pocket wireless CT teleradiology to facilitate stat neurosurgical consultation and future telemedicine implications. *Am J Emerg Med* 2000;18:423-6.
3. Reponen J, Ilkko E, Jyrkinen L, Tervonen O, Niinimäki J, Karhula V, *et al.* Initial experience with a wireless personal digital assistant as a teleradiology terminal for reporting emergency computerized tomography scans. *J Telemed Telecare* 2000;6:45-9.
4. Yaghmai V, Kuppaswami S, Berlin JW, Salehi SA. Evaluation of personal digital assistants as an interpretation medium for computed tomography of patients with intracranial injury. *Emerg Radiol* 2003;10:87-9.
5. Johnston WK 3rd, Patel BN, Low RK, Das S. Wireless teleradiology for renal colic and renal trauma. *J Endourol* 2005;19:32-6.
6. Available from: <http://www.en.wikipedia.org/wiki/IPad>. [Last accessed 2012 Mar 28].
7. CNET updates tablet test results. Available from: http://www.reviews.cnet.com/8301-19736_7-20080768-251/cnet-updates-tablet-test-results. [Last accessed 2012 Mar 28].
8. ACR technical standard for electronic practice of medical imaging. Available from: http://www.acr.org/secondarymainmenucategories/quality_safety/guidelines/med_phys/electronic_practice.aspx. [Last accessed 2013 Jan 30].
9. Mc Laughlin P, Neill SO, Fanning N, Mc Garrigle AM, Connor OJ, Wyse G, *et al.* Emergency CT brain: Preliminary interpretation with a tablet device: Image quality and diagnostic performance of the Apple iPad. *Emerg Radiol* 2012;19:127-33.
10. Mitchell JR, Sharma P, Modi J, Simpson M, Thomas M, Hill MD, *et al.* A smartphone client-server teleradiology system for primary diagnosis of acute stroke. *J Med Internet Res* 2011;13:e31.

Cite this article as: Panughpath SG, Kumar S, Kalyanpur A. Utility of mobile devices in the computerized tomography evaluation of intracranial hemorrhage. *Indian J Radiol Imaging* 2013;23:4-7.

Source of Support: Nil, **Conflict of Interest:** None declared.

Announcement

Android App



Download
**Android
application**

FREE

A free application to browse and search the journal's content is now available for Android based mobiles and devices. The application provides "Table of Contents" of the latest issues, which are stored on the device for future offline browsing. Internet connection is required to access the back issues and search facility. The application is compatible with all the versions of Android. The application can be downloaded from <https://market.android.com/details?id=comm.app.medknow>. For suggestions and comments do write back to us.