

# Sonography of scrotal trauma

Meka Srinivasa Rao, Kalyanpur Arjun

Department of Radiology and Imaging, Teleradiology Solutions Pvt. Ltd., Whitefield, Bangalore, India

**Correspondence:** Dr. Meka Srinivasa Rao, Flat No. 111, Prime Blue Forest Apts, Rajpalya, Hoody, Mahadevpura Post, Bangalore, India.  
E-mail: srinivas.meka@telradsol.com

## Abstract

The purpose of this article is to depict the spectrum of scrotal injuries in blunt trauma. Scrotal injuries are not very common and are mostly due to blunt trauma from direct injury, sports injuries or motor vehicle accidents. To minimize complications and ensure testicular salvage, rapid and accurate diagnosis is necessary. High-resolution USG is the investigation of choice, as it is readily available, accurate and has been seen to improve outcomes. An understanding of and familiarity with the sonographic appearance of scrotal injuries on the part of the radiologist/sonographer is therefore of key importance.

**Key words:** Blunt testicular trauma; scrotal injuries; sonography

## Introduction

Scrotal trauma accounts for less than 1% of all trauma-related injuries, because of the anatomic location and mobility of the scrotum.<sup>[1]</sup> Direct trauma to the scrotum, typically during a sporting injury or other similar mechanism is the commonest form of scrotal injury followed by motor vehicle collision and penetrating injuries. Scrotal trauma patients present with acute pain, and accurate diagnosis is necessary to minimize complications and prevent loss of the testis. A thorough history and detailed physical examination are essential for an accurate diagnosis. High-resolution USG with Doppler flow evaluation is the investigation of choice for the evaluation of scrotal abnormalities.<sup>[2]</sup> It is noninvasive and can be used to quickly evaluate scrotal contents, testicular integrity and blood flow.

A thorough knowledge of scrotal and testicular anatomy is essential for evaluating testicular injuries.

## Anatomy

The outermost layer of the scrotum is the scrotal skin,

which is rugose. The next layer is formed by a series of fascia, which are contiguous with the fascia of the abdominal wall, penis and perineum; the individual layers are not appreciated on USG. The next layer is the tunica vaginalis, which is composed of an outer (parietal) layer and an inner (visceral) layer, a potential space where fluid accumulates. The tunica albuginea is a tough, white, fibrous, capsule-like layer surrounding the seminiferous tubules of the testis; this layer is well appreciated on USG as an echogenic structure. The visceral layer of the tunica vaginalis adheres to this layer.

The tunica albuginea extends inward posteriorly to form the mediastinum testis, the point where the vessels and ducts traverse the testicular capsule. The epididymis attaches posterolaterally.

Scrotal injuries can be classified as extratesticular and intratesticular types.

### Extratesticular injuries

*Scrotal wall/extratesticular hematoma*

Scrotal wall abrasion or wall thickening is commonly associated with blunt scrotal trauma. Hematomas are also a common finding and may appear as focal thickening of the scrotal wall or as fluid collections [Figure 1A and B] within the scrotal wall.<sup>[2,3]</sup> Hematomas appear echogenic on USG when acute and evolve with age [Figure 2A-C]. Extratesticular hematomas [Figure 3A-C] are located in the extratesticular soft tissues other than the scrotal wall, and have an appearance similar to scrotal wall hematoma. These are managed conservatively, unless very large.

### Access this article online

#### Quick Response Code:



**Website:**  
www.ijri.org

**DOI:**  
10.4103/0971-3026.111482

*Hydroceles or hematoceles*

Hydroceles may occur in up to 25% of patients with major trauma [Figure 4A and B]. Rupture of the bulbous urethra may result in extravasation of urine into the scrotum, which may mimic a hydrocele.

Similar to hydroceles, hematoceles are complex collections that separate the visceral and parietal layers of the tunica vaginalis [Figure 5A and B]. Like hematomas, they are acutely echogenic and become more complex and more hypoechoic with age. Subacute and chronic hematoceles may contain fluid–fluid levels or low-level internal echoes and septae.<sup>[4,5]</sup>

The presence of a large acute hematocele may result in decreased blood flow to the testis due to extrinsic pressure on the vessels and thus may mimic testicular torsion or partial torsion.<sup>[6]</sup> The presence of a large hematocele warrants surgical exploration irrespective of any USG evidence of tunica albuginea rupture. In children, hematoceles may occur secondary to abdominal trauma.<sup>[7]</sup>

*Epididymal injuries*

Isolated epididymal injuries are not very common and these are usually associated with testicular injuries. Contusion or traumatic epididymitis appears as an enlarged and heterogeneous epididymis [Figure 6A and B] on USG with increased vascularity and sometimes associated with hematocele.<sup>[8]</sup> This mimics infectious epididymitis on USG and the history of trauma differentiates traumatic epididymitis from its infectious counterpart. Small

hematomas may also be demonstrated in traumatic epididymitis [Figure 6C and D].

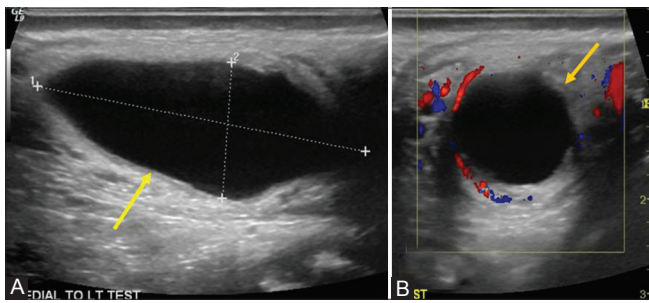
*Intratesticular injuries*

a. Intratesticular hematoma: Intratesticular hematomas are usually focal and fairly well defined [Figure 7A and B] and may be multiple [Figure 8A and B]. They are usually hyperechoic in the acute phase or hypoechoic (as the hemorrhage evolves) and lack vascularity.<sup>[4]</sup> When hematomas become infected, an increase in peripheral vascularity may be noted [Figure 9A and B]. A large intratesticular hematoma appears heterogeneous and normal testicular tissue may barely be seen [Figure 10A-E]. Doppler imaging helps in differentiating from testicular tumors. Testicular hematomas may be treated conservatively with scrotal support, pain medication and ice packs, unless very large, in which case surgical exploration and debridement may be necessary.

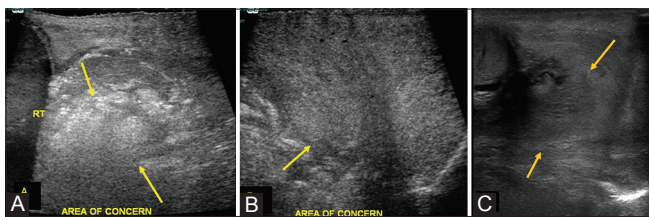
*Testicular fracture*

This serious injury usually appears as a linear hypoechoic band [Figure 11A and B] extending across the testicular parenchyma.<sup>[9-11]</sup> The contour remains smooth with the shape of the testicle maintained. The tunica albuginea is intact. An associated hematocele or testicular hematoma may be seen. The fracture line may not be visible if filled with isoechoic hematoma. Doppler imaging plays an important role in determining vascular integrity.

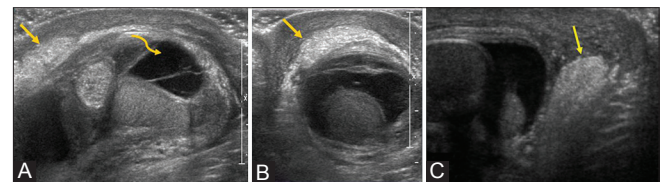
Testicular fractures are treated conservatively if normal flow is identified in the surrounding testicular parenchyma.



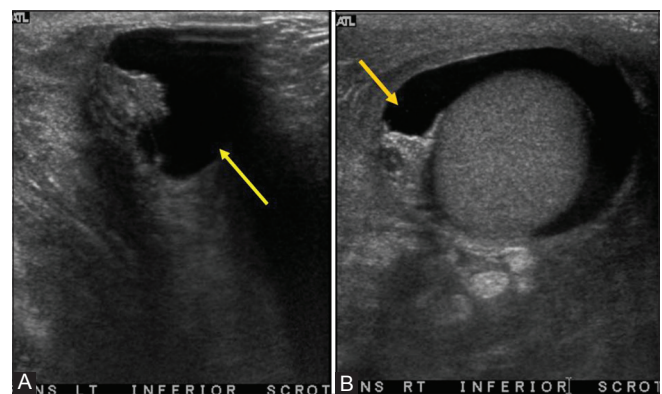
**Figure 1 (A, B):** Sagittal (A), Transverse (B) images in a patient with history of scrotal trauma a week ago: Note anechoic collection in left scrotal wall (arrow), representing an evolving hematoma



**Figure 3 (A-C):** A Transverse (A), Sagittal (B) images demonstrate an ill-defined hyperechoic area that represents a hematoma (arrows) posterior to the right testis suggestive of extratesticular hematoma. Transverse (C) image of an extratesticular hematoma (arrows) in another patient located posterior to the left testis. Scrotal wall thickening is also noted

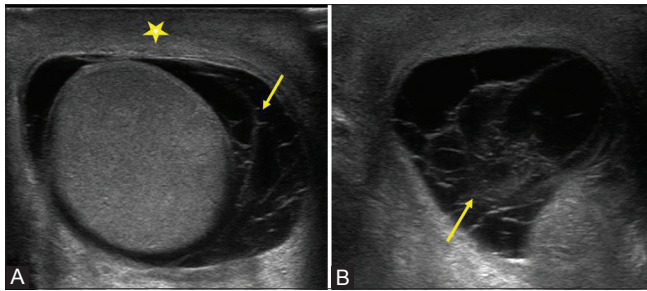


**Figure 2 (A-C):** Sagittal (A), Transverse (B) images demonstrate an hyperechoic layer in the scrotal wall that represents scrotal wall hematoma (straight arrows) with an associated hematocele (Curved arrow). Note that the left testicle is itself intact. Sagittal (C) image of another patient demonstrates similar findings of scrotal wall hematoma (arrow)

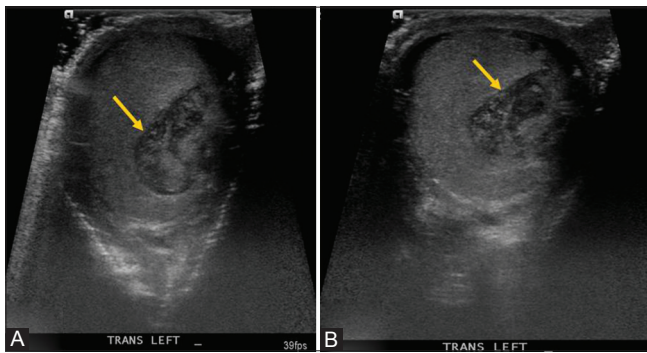


**Figure 4 (A, B):** Left (A) and Right (B) transverse images demonstrate bilateral hydroceles (arrows) in a patient with blunt scrotal trauma

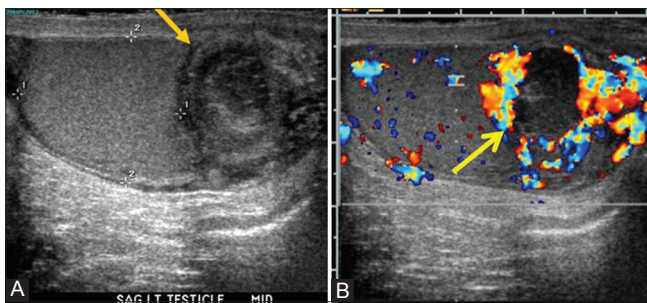




**Figure 5 (A, B):** Transverse images demonstrate scrotal wall thickening (star) with hematocele in a patient with blunt scrotal trauma. Note fibrinous septations (arrows). A homogeneous intact testicle is also noted



**Figure 7 (A, B):** Transverse images in a patient with blunt trauma to the scrotum demonstrating heterogeneous area that represents an intratesticular hematoma (arrows) in the left testis



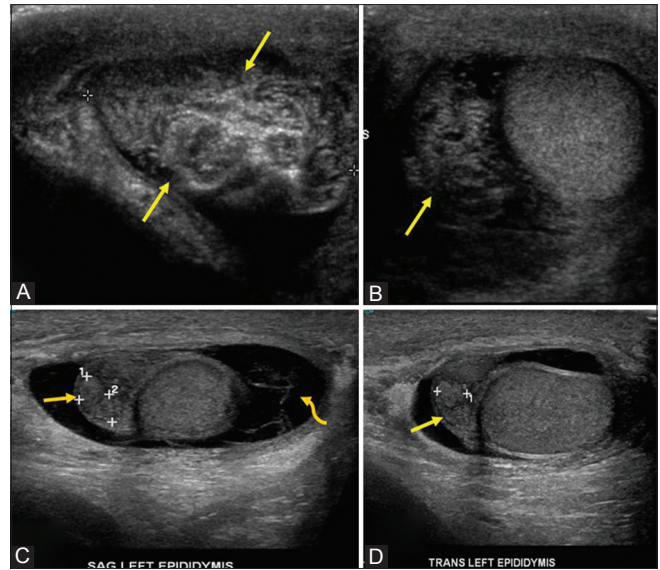
**Figure 9 (A, B):** Sagittal (A) demonstrating an intratesticular heterogeneous hypoechoic area (arrow) and sagittal (B) Doppler image with peripheral vascularity (arrow) in a patient with history of scrotal trauma a week ago, representing an evolving hematoma (possibly infected)

If flow is absent, emergent exploration is indicated, as this finding represents ischemia.

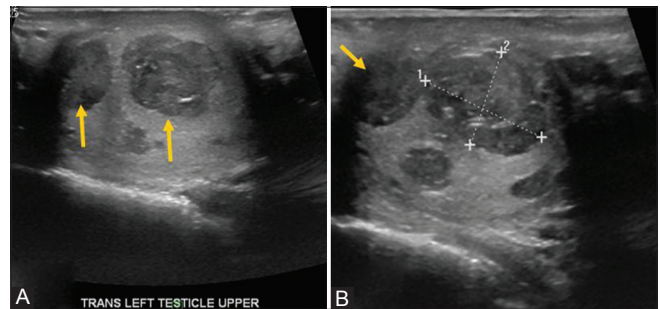
#### Testicular rupture

In testicular rupture there is discontinuity of the echogenic tunica albuginea with hemorrhage and extrusion of testicular contents into the scrotal sac [Figure 12A-E]. This is an indication for emergency scrotal exploration to salvage the testis.

In this type of injury, USG also demonstrates poorly defined testicular margins and heterogeneous echotexture, with areas of hemorrhage or infarction.<sup>[11-13]</sup> Associated findings may include scrotal wall thickening and hematocele.



**Figure 6 (A-D):** Sagittal (A) and Transverse (B) images in a patient with history of blunt scrotal trauma demonstrating heterogeneous and thickened epididymis (arrows), representing traumatic epididymitis. Sagittal (C) and Transverse (D) images of another patient with blunt scrotal trauma demonstrating heterogeneous and thickened left epididymis with a small hematoma (arrows). An associated hematocele (curved arrow) is also noted

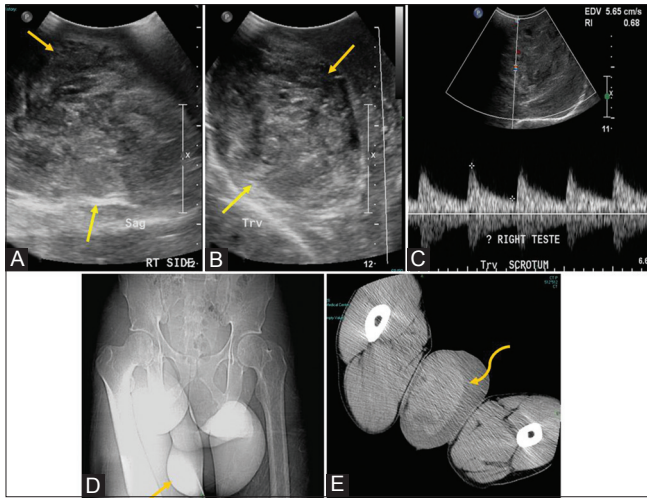


**Figure 8 (A, B):** Transverse images demonstrating well-defined heterogeneous areas that represent hematomas (arrows) in the left testis, suggestive of intratesticular hematomas in patient with history of blunt scrotal trauma

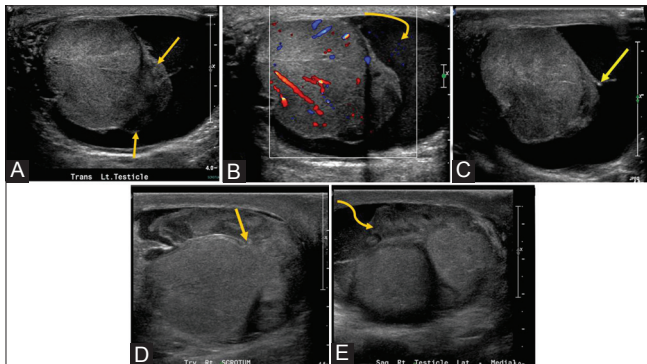
In a study by Buckley and McAninch, in their series of 65 patients with blunt scrotal trauma, based on USG findings of a heterogeneous echotexture and contour abnormality, they demonstrated a sensitivity of 100% and a specificity of 93.5% in the diagnosis of testicular rupture.<sup>[13]</sup> Kim *et al.* demonstrated that loss of definition of the tunica albuginea is the only significant predictor for the diagnosis of testicular rupture in patients with blunt scrotal trauma.<sup>[14]</sup>

Color Doppler imaging is essential and invaluable to assess traumatic injuries to the testis.<sup>[15,16]</sup> Tunica albuginea rupture is almost always associated with a disruption of vascularity to the testicular parenchyma due to close apposition of the tunica vasculosa to the tunica albuginea. This may result in loss of vascularity to a portion of or the entire testis [Figure 13A-C], depending on the grade of injury. The avascular and lacerated portion of the ruptured testis





**Figure 10 (A-E):** Sagittal (A) and transverse (B) images in a mentally challenged patient with history of scrotal swelling demonstrating large heterogeneous echogenic area in the right scrotal sac, from which the testis is not separately visualized, suggestive of testicular hematoma (arrows). Image (C) on Doppler, note the low resistance flow in the testicular tissue. computed tomography-Topogram (D) and axial (E) images of the same patient with enlarged scrotum (arrow) and a large hyperdense structure in the right scrotal sac consistent with a testicular hematoma (curved arrow)

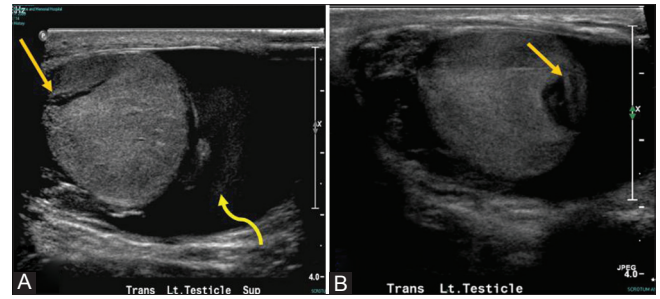


**Figure 12 (A-E):** Transverse (A) image with history of blunt scrotal trauma demonstrating left testicular rupture with extrusion of contents (arrows). Transverse (B) image, Doppler demonstrating preserved testicular vascularity. Large hematocoele (curved arrow) is also noted. Transverse (C) image of same patient with left testicular rupture demonstrating discontinuity of Tunica albuginea (arrow). Transverse (D) and Sagittal (E) images of another patient with testicular rupture demonstrating discontinuity of Tunica albuginea (arrow) and extrusion of contents (curved arrow)

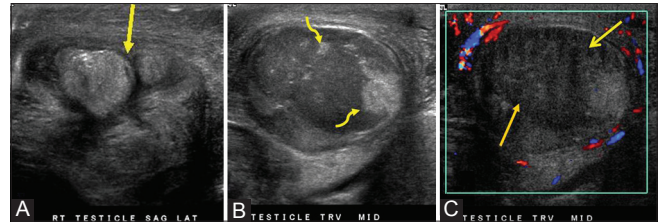
is usually debrided, and the viable portions are left behind. Orchiectomy is performed if there is no or little vascularity.

### Summary

USG in scrotal trauma reveals a wide spectrum of morphology, ranging in severity from simple scrotal wall edema to testicular rupture and infarction. As the management is determined by the severity of the injury, it is important for the sonologist to be well versed with the appearance of each type of injury along this spectrum.



**Figure 11 (A, B):** Transverse images of the left testis demonstrate a hypoechoic linear area (arrow) indicative of a testicular fracture in a patient with history of kick to the scrotum. Tunica albuginea was intact (not completely shown on images). Associated hematocoele (curved arrow) is also noted



**Figure 13 (A-C):** Sagittal (A) lateral aspect of the right testis demonstrating extruded testicular contents in a patient with blunt scrotal trauma. Transverse (B) Grey-Scale and Doppler (C) images demonstrating hypoechoic testis without color flow (arrow), indicating infarction. Also noted are small focal hyperechoic areas (curved arrows) within the infarcted testis representing (barely) viable portions of the right testis

Accurate USG diagnosis is therefore the essence of appropriate therapy in scrotal trauma.

### References

1. Deurdulian C, Mittelstaedt CA, Chong WK, Fielding JR. US of acute scrotal trauma: Optimal technique, imaging findings, and management. *Radiographics* 2007;27:357-69.
2. Ragheb D, Higgins JL Jr. Ultrasonography of the scrotum: Technique, anatomy, and pathologic entities. *J Ultrasound Med* 2002;21:171-85.
3. Micallef M, Ahmad I, Ramesh N, Hurley M, McInerney D. Ultrasound features of blunt testicular injury. *Injury* 2001;32:23-6.
4. Bhatt S, Ghazale H, Dogra VS. Sonographic evaluation of scrotal and penile trauma. *Ultrasound Clin* 2007;2:45-56.
5. Haddad FS, Manne RK, Nathan MH. The pathological, ultrasonographic and computerized tomographic characteristics of chronic hematocoele. *J Urol* 1988;139:594-5.
6. Dogra VS, Bhatt S, Rubens DR. Sonographic evaluation of testicular torsion. *Ultrasound Clin* 2006;1:55-66.
7. Koumanidou C, Manopoulou E, Pantazis J, Dermentzoglou V, Georgoulis P, Vakaki M, et al. Scrotal hematocoele as an unusual presentation of blunt abdominal trauma in three male infants. *J Clin Ultrasound* 2000;28:190-3.
8. Gordon LM, Stein SM, Ralls PW. Traumatic epididymitis: Evaluation with color Doppler sonography. *AJR Am J Roentgenol* 1996;166:1323-5.
9. Jeffrey RB, Laing FC, Hricak H, McAninch JW. Sonography of testicular trauma. *AJR Am J Roentgenol* 1983;141:993-5.
10. Dogra VS, Gottlieb RH, Oka M, Rubens DJ. Sonography of the scrotum. *Radiology* 2003;227:18-36.

11. Blaivas M, Brannam L. Testicular ultrasound. *Emerg Med Clin North Am* 2004;22:723-48, ix.
12. Guichard G, El Ammari J, Del Coro C, Cellarier D, Looock PY, Chabannes E, *et al.* Accuracy of ultrasonography in diagnosis of testicular rupture after blunt scrotal trauma. *Urology* 2008;71:52-6.
13. Buckley JC, McAninch JW. Use of ultrasonography for the diagnosis of testicular injuries in blunt scrotal trauma. *J Urol* 2006;175:175-8.
14. Kim SH, Park S, Choi SH, Jeong WK, Choi JH. Significant predictors for determination of testicular rupture on sonography: A prospective study. *J Ultrasound Med* 2007;26:1649-55.
15. Muttarak M, Thinyu S, Lojanapiwat B. Clinics in diagnostic imaging (114). Rupture of the right testis. *Singapore Med J* 2007;48:264-8.
16. Gross M. Rupture of the testicle: The importance of early surgical treatment. *J Urol* 1969;101:196-7.

**Cite this article as:** Rao MS, Arjun K. Sonography of scrotal trauma. *Indian J Radiol Imaging* 2012;22:293-7.

**Source of Support:** Nil, **Conflict of Interest:** None declared.

### Author Help: Reference checking facility

The manuscript system ([www.journalonweb.com](http://www.journalonweb.com)) allows the authors to check and verify the accuracy and style of references. The tool checks the references with PubMed as per a predefined style. Authors are encouraged to use this facility, before submitting articles to the journal.

- The style as well as bibliographic elements should be 100% accurate, to help get the references verified from the system. Even a single spelling error or addition of issue number/month of publication will lead to an error when verifying the reference.
- Example of a correct style  
Sheahan P, O'leary G, Lee G, Fitzgibbon J. Cystic cervical metastases: Incidence and diagnosis using fine needle aspiration biopsy. *Otolaryngol Head Neck Surg* 2002;127:294-8.
- Only the references from journals indexed in PubMed will be checked.
- Enter each reference in new line, without a serial number.
- Add up to a maximum of 15 references at a time.
- If the reference is correct for its bibliographic elements and punctuations, it will be shown as CORRECT and a link to the correct article in PubMed will be given.
- If any of the bibliographic elements are missing, incorrect or extra (such as issue number), it will be shown as INCORRECT and link to possible articles in PubMed will be given.