

Case Series: Pericardial gossypibomas detected after cardiovascular surgery: Imaging findings

Cengiz Erol, Mustafa Koplay, Yahya Paksoy, Fikret Kanat¹

Departments of Radiology, and ¹Chest Diseases, Selcuk University, Selcuklu Faculty of Medicine, Alaeddin Keykubat Campus, Selcuklu, Konya, Turkey

Correspondence: Dr. Cengiz Erol, Selcuk University, Selcuklu Faculty of Medicine, Department of Radiology, Alaeddin Keykubat Campus, Konya - 42250, Turkey. E-mail: drcengizerol@yahoo.com

Abstract

We present the chest radiograph, computed tomography (CT), and magnetic resonance imaging (MRI) findings of three pericardial gossypibomas, which are rarely reported and an exceptional complication of cardiovascular surgery. The diagnosis is usually possible with surgical history, high clinical suspicion, and awareness of variable imaging findings. Usage of sponges with radiopaque markers facilitates early detection by chest radiographs and CT. In case of radiolucent gossypibomas, specific MRI features help to differentiate this pathology from other masses and diffusion-weighted images can be used to distinguish it from an abscess.

Key words: Computed tomography; imaging findings; magnetic resonance imaging; pericardial gossypiboma

Introduction

Gossypiboma and textiloma are used interchangeably to define an accidentally left surgical gauze sponge in the surgical bed. This complication is more frequently seen after abdominal surgery and rarely reported after cardiothoracic surgery.^[1] Gossypiboma can lead to misdiagnosis, and cause medical–medicolegal consequences.^[1] Our aim is to present chest radiograph, computed tomography (CT), and magnetic resonance imaging (MRI) features of three pericardial gossypiboma cases detected after cardiovascular surgery.

Case Reports

Case 1

A 68-year-old male patient who had undergone coronary artery bypass graft surgery 1 month earlier was admitted to our hospital for routine control. Chest radiograph showed folded linear radiopaque sponge markers superposed on the left side of the heart that was not there on the preoperative

radiograph [Figure 1]. The patient underwent a second operation, and a retained surgical sponge was removed from the left atrioventricular groove on the site of left circumflex artery anastomosis.

Case 2

A 54-year-old male patient was admitted to our hospital with the complaint of cough. Chest radiograph showed a mass on the left side of the heart [Figure 2A]. A contrast-enhanced chest CT revealed a sharply defined, rounded, giant mass at the left atrioventricular groove, compressing the left atrium and left ventricle. The mass had a hyperdense, well-enhanced rim with central high-density curvilinear stripes [Figure 2B].

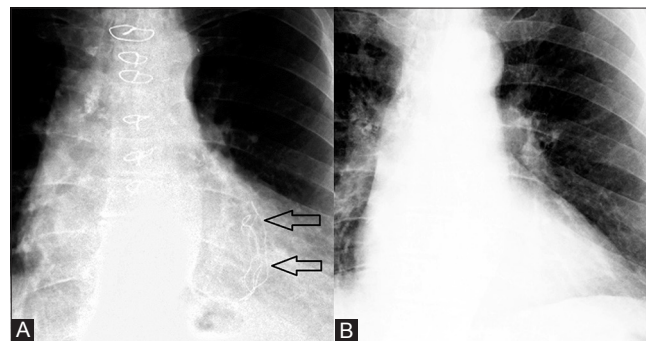


Figure 1 (A, B): Radiopaque sponge markers in a 68-year-old male patient who had undergone coronary artery bypass graft surgery 1 month earlier. Posteroanterior chest radiograph taken after cardiovascular surgery (A) shows folded linear radiopaque sponge markers (arrows) superposed on the left side of the heart that was not there on the preoperative chest radiograph (B)

Access this article online

Quick Response Code:



Website:
www.ijri.org

DOI:
10.4103/0971-3026.111479

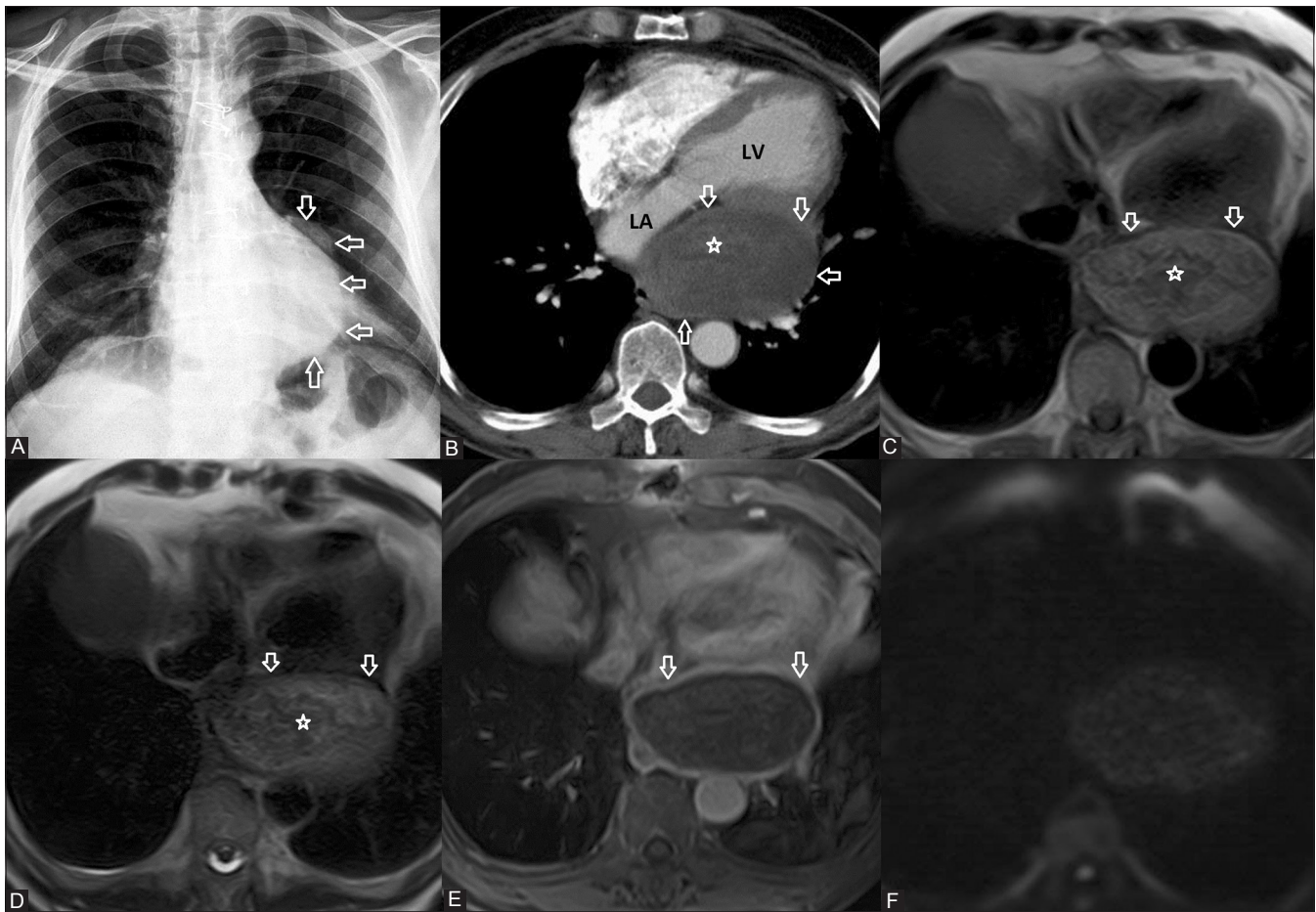


Figure 2 (A-F): Pericardial gossypiboma in a 54-year-old male patient. Posteroanterior chest radiograph (A) shows a mass on the left side of the heart (arrows). Contrast-enhanced chest CT (B) reveals sharply defined rounded mass with enhanced rim (arrows) and central high-density curvilinear stripes (asterisks) at the left atrioventricular groove, compressing the left atrium and left ventricle. Cardiac MRI demonstrates enhancing smooth capsula (arrows) which was hypointense on T1- and T2-weighted images (C–E) and whorled wavy hypointensities (asterisks) on T1- and T2-weighted images (C, D). Internal component did not have any contrast enhancement. Diffusion-weighted images showed no diffusion reduction excluding an abscess (F). LA, left atrium; LV, left ventricle

Cardiac MRI was performed on a 1.5-T MRI system and demonstrated a lesion with whorled internal configuration on T1- and T2-weighted images and wavy hypointensities on T2-weighted images [Figures 2C and D]. The lesion had a smooth, thick capsula which was hypointense on T1- and T2-weighted images, and enhanced after contrast administration [Figure 2E]. Internal component of the lesion did not enhance [Figure 2E]. Diffusion-weighted images (DWI) showed no reduction of diffusion excluding an abscess [Figure 2F]. We had learned that the patient had bypass surgery 8 months earlier and the lesion was not seen on chest radiograph taken just after surgery. The patient was operated and a surgical gauze sponge was removed.

Case 3

A 36-year-old male patient who had undergone aortic valve replacement operation 18 months earlier was admitted to our hospital with the complaint of discharge at the low end of the sternotomy site. Chest radiograph showed a radiopaque marker on the superior vena cava–right atrium junction. An enhanced chest CT demonstrated well-defined right-sided intrapericardial

mass lesion near the aortic valve, which opened to the subxiphoid region with a fistula tract and also contained infolded linear dense sponge markers [Figures 3A and B]. The patient underwent a second operation and a sponge was removed [Figure 3C].

Discussion

Intrathoracic gossypibomas are usually found in the pleural or pericardial cavities and constitute 11% of all gossypiboma cases.^[1,2] The clinical presentation of gossypibomas is variable and depends on the location of the sponge and the type of reaction.^[1] Gossypibomas cause aseptic exudative inflammation in the early postoperative period, and if infected, may result in abscess and fistula formation. This reaction is followed by a fibrotic reaction which can lead to adhesion, encapsulation, and granuloma formation.^[1-3] It is commonly asymptomatic as in our first case and can cause nonspecific symptoms such as chronic chest pain, purulent sputum, hemoptysis, fever, cough as in our second case, and fistula as in our third case.^[1,2] Organ compression,

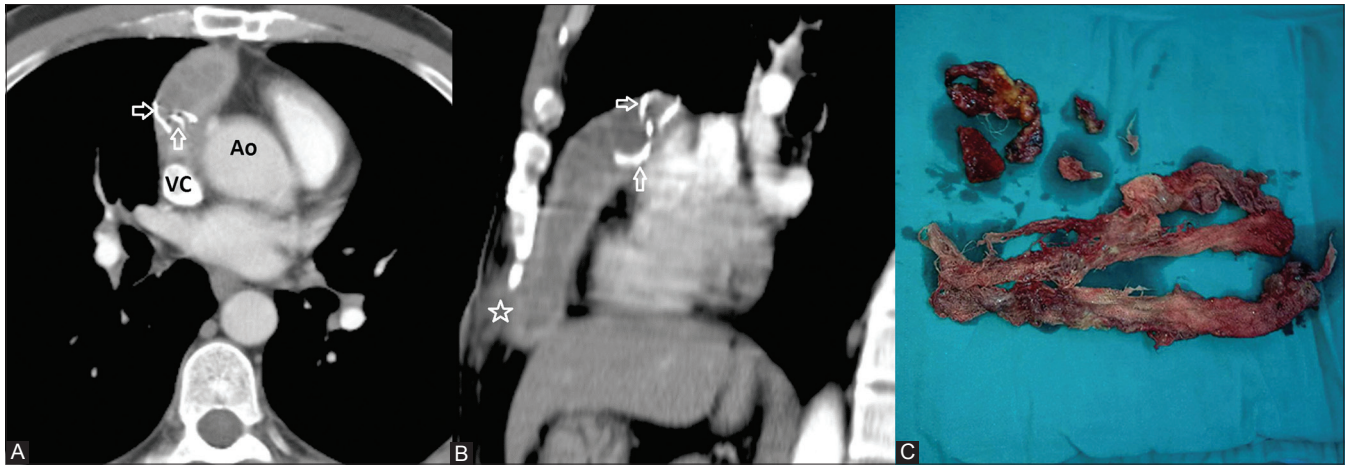


Figure 3 (A-C): Pericardial gossypiboma in a 36-year-old male patient who had undergone aortic valve replacement operation 18 months earlier. (A, B) An enhanced chest CT examination demonstrates well-defined right-sided intrapericardial mass lesion near the aortic valve which contains infolded linear dense sponge markers (arrows) and opens to the subxiphoid region with a fistula tract (asterisks). (C) The patient underwent a second operation, and a surgical gauze sponge was removed. VC, vena cava superior; Ao, aorta

migration of the sponge, or fistula formation usually occurs during later stages.^[1] It has also significant medicolegal consequences for the surgical team because of chronic infections, delayed diagnosis, and misdiagnosis leading to unnecessary diagnostic interventions.^[2]

Chest radiograph is the first and most commonly used imaging modality to detect sponges that contain radiopaque markers, and as in our first case, it can be easily detected at the initial controls after cardiac surgery.^[1,3] As in our second case, gossypibomas that do not have radiopaque markers may appear as masses mimicking abscess, organized hematoma, hydatid cyst, aspergillomas, or tumors.^[2,4] CT is the preferred imaging modality in these cases and findings change depending on the location and the chronicity of retained sponge.^[1] Characteristic CT appearance of a pericardial gossypiboma in the early postoperative days is a soft tissue mass located in the mediastinum or pericardium with a contrast-enhanced hyperdense rim and air bubbles dispersed within spongiform high-density areas.^[1,3,4] CT is also useful to show possible complications of gossypibomas such as abscess and, as in our last case, fistula formation.^[1] Trapped air within the sponge is resorbed over a period of time.^[1] The diagnosis can be very difficult in the absence of radiopaque markers and air bubbles.^[1,4] To differentiate a neoplasm from a degenerated hydatid cyst and to show the relationship of the mass with the neighboring structures, cardiac MRI can be performed. MRI features of gossypibomas are less known and have been described in recent years.^[4,5] Absence of clear invasion and central contrast enhancement of the mass make the diagnosis of a neoplasm less likely. As in our second case, contrast-enhanced well-defined fibrous capsula around the mass which is formed as a fibrous reaction of the body to the sponge and hypointense whorled stripes within the central cavity which is compatible with sponge fibers on T2-weighted images were specific findings with the diagnosis of gossypiboma.^[4,5] To the best of our knowledge,

this is the second report in which DWI were used to differentiate a gossypiboma from an abscess formation, which was achieved by showing no reduction of diffusion.^[5] All of our cases were operated with a definitive preoperative diagnosis of gossypiboma.

Conclusion

Pericardial gossypiboma is a rarely reported and exceptional complication of cardiovascular surgery. The clinical manifestations are nonspecific and diagnosis is usually possible with the surgical history, high clinical suspicion, and awareness of variable imaging findings. Usage of surgical sponges with radiopaque markers can facilitate early detection by chest radiographs and CT. In case of radiolucent gossypibomas, specific MRI features help to differentiate this pathology from other masses and DWI can be used to distinguish it from an abscess.

References

1. Manzella A, Filho PB, Albuquerque E, Farias F, Kaercher J. Imaging of gossypibomas: Pictorial review. *AJR Am J Roentgenol* 2009;193:S94-101.
2. Szarf G, Mussi de Andrade TC, Nakano E, Szejnfeld D, Costa AS Jr, Rymkiewicz E, et al. Forty-year-old intrathoracic gossypiboma after cardiac valve surgery. *Circulation* 2009;119:3142-3.
3. Karabulut N, Herek D, Kiroglu Y. CT features of intrathoracic gossypiboma (textiloma). *Diagn Interv Radiol* 2011;17:122-4.
4. Ridene I, Hantous-Zannad S, Zidi A, Smati B, Baccouche I, Kilani T, et al. Imaging of thoracic textiloma. *Eur J Cardiothorac Surg* 2011;39:e22-6.
5. Erdem G, Ateş O, Koçak A, Alkan A. Lumbar gossypiboma. *Diagn Interv Radiol* 2010;16:10-2.

Cite this article as: Erol C, Koplay M, Paksoy Y, Kanat F. Case Series: Pericardial gossypibomas detected after cardiovascular surgery: Imaging findings. *Indian J Radiol Imaging* 2012;22:276-8.

Source of Support: Nil, **Conflict of Interest:** No.