

Fusion of intravenous contrast-enhanced C-arm CT and pretreatment imaging for ablation margin assessment of liver tumors: A preliminary study

Jin Iwazawa, Naoko Hashimoto, Takashi Mitani, Shoichi Ohue¹

Department of Radiology, Nissay Hospital, Itachibori, Nishiku, Osaka, ¹Department of Radiology, Komatsu Hospital, Kawakatsucho, Neyagawa, Japan

Correspondence: Dr. Jin Iwazawa, Department of Radiology, Nissay Hospital, 6-3-8 Itachibori, Nishiku, Osaka 550-0012, Japan.
E-mail: iwazawa.jin@nissay-hp.or.jp

Abstract

The aim of this preliminary study was to evaluate the feasibility of assessing ablation margins after radiofrequency ablation (RFA) of liver tumors from fusion images of post-treatment C-arm computed tomography (CT) images fused to pretreatment images. Five patients with liver tumors underwent RFA. Intravenous contrast-enhanced C-arm CT images were obtained for all patients immediately after RFA, and multi-detector CT (MDCT) images were obtained 3-7 days later. The C-arm CT and MDCT images were fused to pretreatment images using a multimodality image fusion software. The minimum ablation margins were assessed in the C-arm CT and MDCT fusion images. Ablation margins after RFA of liver tumors can be measured using intravenous contrast-enhanced C-arm CT images fused with pretreatment images. This technique has the potential for use in the intra-procedural assessment of liver tumor ablation.

Key words: Cone-beam CT; multimodality fusion; radiofrequency ablation; safety margin

Introduction

Radiofrequency ablation (RFA) is an established local therapy for managing localized liver tumors. Ablation margins are usually evaluated using contrast-enhanced multi-detector computed tomography (MDCT) after RFA therapy.^[1] However, immediate therapeutic assessment using these techniques is limited unless the equipment is available during RFA. Recent advances in C-arm cone-beam technology allow operators to acquire optimal images during procedures without requiring patient transfer.^[2,3] A

digital flat-panel detector on the upper side of the C-arm rotates around the patient to generate volumetric images similar to conventional CT images. In this preliminary study, we used this novel modality and injected a contrast medium through a peripheral vein into patients undergoing RFA of liver tumors to assess ablation margins using a recently developed multimodality fusion software.

C-arm Computed Tomography

Five patients (4 men, 1 woman; mean age, 68.2 years), each of whom had a solitary liver tumor (4 hepatocellular carcinomas, 1 metastatic tumor; range, 8-30 mm; mean size, 15.0 mm), underwent RFA using a C-arm cone-beam system (Innova 3100; GE Healthcare, Waukesha, WI, USA). Prior to RFA treatment, we obtained images of each patient's treatment area using either triphasic dynamic contrast-enhanced MDCT or magnetic resonance (MR) imaging. Contrast-enhanced C-arm CT images were obtained immediately after RFA. A 90-ml bolus of

Access this article online

Quick Response Code:



Website:
www.ijri.org

DOI:
10.4103/0971-3026.111470

iopamidol (300 mgI/ml; flow rate, 1 ml/s) was injected through the antecubital vein using a power injector and the C-arm CT images were obtained 2 min later.^[4] The image acquisition parameters included were the following: Total scanning angle, 200 degrees; acquisition time, 10 s; matrix size, 1500 × 1500; isotropic voxel size, 0.2 mm; and effective field-of-view, 18 cm². Raw data sets were transferred to an external workstation (Advantage Workstation 5.0; GE Healthcare), upon which the images were reconstructed with a 1-mm slice thickness in multiple planes. Images were reconstructed within approximately 1 min of scan completion.

Multi-detector Computed Tomography

Post-treatment MDCT images were obtained for each patient 3-7 days after RFA therapy. Triphasic contrast-enhanced MDCT images were obtained using a 16-MDCT scanner (Somatom Sensation; Siemens Medical Solutions, Forchheim, Germany) using the following scanning parameters: 120 kV; 182 mA; beam collimation, 0.75 mm; helical pitch, 1.15 mm; and rotation table speed, 0.5 s. Helical acquisition for arterial, portal, and venous phase imaging was initiated at 20, 60, and 160 s, respectively, after a threshold level of 100 HU was reached in the abdominal aorta. Images were reconstructed with a 1-mm slice thickness in multiple planes.

Image Fusion

We used a multimodality image fusion software (Integrated Registration; GE Healthcare) to fuse multimodality images before and after RFA. The volume data sets of contrast-enhanced C-arm CT, portal-phase MDCT, and hepatobiliary-phase MR images were transferred to an Advantage Workstation 5.0 (GE Healthcare). Images were

first displayed side by side on the workstation screen and then manually adjusted so that the intrahepatic vessels adjacent to the target tumor were similarly displayed. A hepatic or portal vein that was identical in both images was then selected as the landmark for image registration in another plane. If image registration was unsatisfactory, one or two additional intrahepatic vein landmarks were selected to ensure more precise image registration adjustment. Once the images were registered, the fusion images were reconstructed as 3-mm-thick multi-planar images by the same radiology technician.

Results

The fused post-treatment C-arm CT and pretreatment images were sufficiently delineated to permit measurement of the ablation margins [Figure 1]. However, the interface of the ablated margin was not sharp and inflammatory peripheral enhancement was more eminent for C-arm CT fusion than MDCT fusion in all cases. The minimum ablation margins measured using C-arm CT and MDCT fused with the pretreatment images are listed in Table 1.

Table 1: Minimum ablation margins of liver tumors after radiofrequency ablation as determined from fusion of pretreatment images and post-treatment C-arm CT and MDCT images

Patient	Tumor size (mm)	Prior image	Minimum ablation margin (mm)	
			C-arm CT fusion	MDCT fusion
A	15	MR	1.7	2.0
B	10	CT	2.1	3.1
C	8	CT	10.6	9.3
D	12	MR	4.2	5.3
E	30	CT	0	0

CT: Computed tomography, MDCT: Multi-detector computed tomography, MR: Magnetic resonance

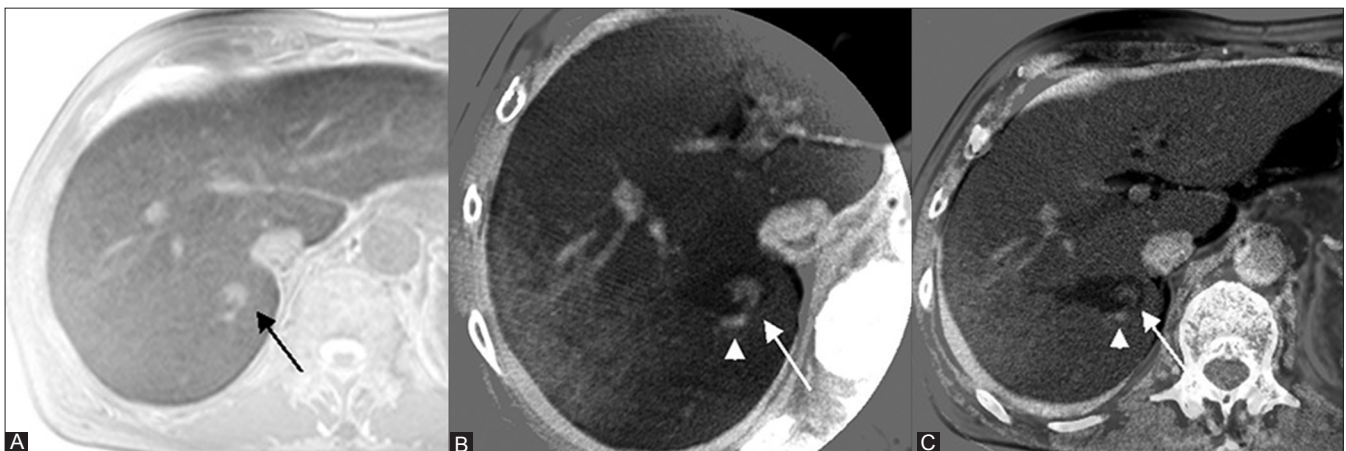


Figure 1 (A-C): A 66-year-old man with a 15-mm hepatocellular carcinoma. (A) An inverted hepatobiliary-phase MR image obtained before RFA showing the target tumor (arrow) at hepatic segment VII. (B) A transverse fusion image of intra-procedural contrast-enhanced C-arm CT and pretreatment hepatobiliary-phase MR image revealing insufficient ablation margins (arrow) due to the heat-sink effect of the adjacent portal vein (arrowhead). (C) A fusion image of a portal-phase multi-detector CT image and a pretreatment hepatobiliary-phase MR image showing an insufficient ablation margin (arrow) and an adjacent portal vein (arrowhead) that are similar to those seen in the C-arm CT fusion image.

Discussion

Complete ablation of tumors with margins ≥ 5 mm is recommended for curative ablation.^[5] Ablation margins are usually evaluated using side-by-side comparisons of transverse pre- and post-treatment image views. This approach is limited by manual assessment errors only. To overcome this shortcoming, we adopted a new image fusion software that can fuse multimodal image sets. Using this technique, fusion images enable quantitative evaluation of ablation margins. Our results suggest that intra-procedural ablation margin assessment can be performed using a fusion image from C-arm CT images obtained during RFA and pretreatment CT/MR imaging. In this study, image fusion took approximately 1-2 min, allowing immediate decisions regarding further treatment. If insufficient ablation margins or residual lesions are detected on fusion C-arm CT images, additional targeted ablation can be promptly applied under C-arm CT guidance. Conversely, when sufficient ablative margins are confirmed on C-arm CT images, additional therapeutic assessments with other imaging modalities may not be required.

Conclusion

Intravenous contrast-enhanced C-arm CT images fused with pretreatment images for the assessment of treatment efficiency demonstrated sufficiently delineated ablation

margins after RFA of liver tumors. This novel technique may potentially be used in the intra-procedural assessment of liver tumor ablation.

References

1. Kim KW, Lee JM, Klotz E, Kim SJ, Kim SH, Kim JY, *et al.* Safety margin assessment after radiofrequency ablation of the liver using registration of preprocedure and postprocedure CT images. *AJR Am J Roentgenol* 2011;196:W565-72.
2. Wallace MJ, Kuo MD, Glaiberman C, Binkert CA, Orth RC, Soulez G. Three-dimensional C-arm cone-beam CT: Applications in the interventional suite. *J Vasc Interv Radiol* 2008;19:799-813.
3. Orth RC, Wallace MJ, Kuo MD. C-arm cone-beam CT: General principles and technical considerations for use in interventional radiology. *J Vasc Interv Radiol* 2008;19:814-20.
4. Iwazawa J, Ohue S, Hashimoto N, Mitani T. Ablation margin assessment of liver tumors with intravenous contrast-enhanced C-arm computed tomography. *World J Radiol* 2012;4:109-14.
5. Mori K, Fukuda K, Asaoka H, Ueda T, Kunimatsu A, Okamoto Y, *et al.* Radiofrequency ablation of the liver: Determination of ablative margin at MR imaging with impaired clearance of ferucarbotran—feasibility study. *Radiology* 2009;251:557-65.

Cite this article as: Iwazawa J, Hashimoto N, Mitani T, Ohue S. Fusion of intravenous contrast-enhanced C-arm CT and pretreatment imaging for ablation margin assessment of liver tumors: A preliminary study. *Indian J Radiol Imaging* 2012;22:251-3.

Source of Support: Nil, **Conflict of Interest:** None declared.

Announcement

Android App



Download
**Android
application**

FREE

A free application to browse and search the journal's content is now available for Android based mobiles and devices. The application provides "Table of Contents" of the latest issues, which are stored on the device for future offline browsing. Internet connection is required to access the back issues and search facility. The application is compatible with all the versions of Android. The application can be downloaded from <https://market.android.com/details?id=comm.app.medknow>. For suggestions and comments do write back to us.