

Bipolar radiofrequency-induced thermotherapy of great saphenous vein: Our initial experience

Venkatesh Kasi, Tejas M Kalyanpur, Kaustubh Narsinghpura, Deyananda Chakravarthy, Pankaj Mehta, Mathew Cherian

Department of Radiology, Kovai Medical Center and Hospital, Avinashi Road, Coimbatore, Tamil Nadu, India

Correspondence: Dr. Mathew Cherian, Department of Radiology, Kovai Medical Center and Hospital, Avinashi Road, Coimbatore - 641 014, Tamil Nadu, India. E-mail: dr.mathewcherian@gmail.com

Abstract

The incidence of varicose veins in lower limbs is increasing in the Indian subcontinent. With the advent of radiofrequency ablation (RFA), an effective minimally invasive technique is now available to treat varicose veins. RFA can be performed with either unipolar or bipolar probes. We present a simple technique for bipolar radiofrequency-induced thermotherapy of the great saphenous vein. This can be a safe and effective alternative to surgical procedures.

Key words: Radiofrequency ablation; varicose veins; bipolar electrode

Introduction

Varicosity of the lower limb veins is a common vascular problems encountered in practice. The most common site of reflux is the great saphenous vein (GSV).^[1] The standard management for GSV reflux has been surgical ligation of the sapheno-femoral junction (SFJ), with stripping of the GSV. In the recent past there has been a radical shift towards minimally invasive techniques, one of which is radiofrequency ablation (RFA). RFA operates by resistive heating of the vein wall. It is clearly effective and less painful than surgery and laser ablation,^[2] and has established itself as the treatment of choice for varicose veins. Bipolar probes for RFA have only recently been introduced in India. We present a step-by-step approach for the use of bipolar probes in RFA of the GSV.

Materials and Methods

Inclusion and exclusion criteria

Patients with Doppler evidence of an incompetent SFJ and reflux into the GSV (more than 0.5 s) are candidates for RFA. Exclusion criteria include deep venous thrombosis, extremely tortuous GSV identified during preprocedure USG, inability to ambulate, and pregnancy.

Equipment

Bipolar radiofrequency-induced thermotherapy (RFITT) is. The basic equipment consists of a radiofrequency generator unit (CelonLab POWER, Celon AG Medical Instruments, Teltow, Germany) with a maximum power output of 250 watts and a bipolar RFITT applicator (CelonProCurve® 1200-S15, Celon AG Medical Instruments, Teltow, Germany). The applicator's diameter is 2mm; it has an active length of 15 mm and a flexible shaft of 115 cm [Figure 1].

Procedure

1. The patient is placed in the reverse Trendelenburg position.
2. Local anesthetic cream is applied along the course of the GSV.
3. The GSV is accessed using the Seldinger technique; a 70-cm long 6F sheath is positioned with its proximal end 4cm distal to the SFJ [Figure 2].

Access this article online

Quick Response Code:



Website:
www.ijri.org

DOI:
10.4103/0971-3026.101075

4. The radiofrequency applicator is inserted through the sheath and positioned 2 cm below the SFJ.
5. Under USG guidance, perivenous tumescent fluid (a mixture of 300 ml of normal saline and 30 ml of 1% Xylocaine®) is injected to reduce treatment-related pain [Figure 3], reduce vein diameter, and protect perivenous tissue from heat damage.^[2]
6. Mild intravenous sedation is given.
7. The radiofrequency applicator, along with the sheath, is steadily pulled out (at approximately 0.5 cm/s) [Figure 4].
8. The procedure is terminated when the wider mark on the shaft of the applicator is visible at the puncture site.
9. Post procedure, a single dose of 40 or 60mg low-molecular-weight heparin is injected subcutaneously.
10. Crepe bandage is applied from the foot to the groin immediately after the procedure; this is to be removed the following day and replaced with a type II compression stocking (30–40 mmHg) for a period of at least 3 weeks. All patients are mobilized within 1 hr of the procedure.



Figure 1: Bipolar probe: Two poles are separated by a white insulator. The wider black mark on the shaft serves as an indicator: when it is visible at the puncture site the operator should terminate the procedure

Follow-up

All patients are advised to come for follow-up after 7, 21, 90, and 180 days; at these visits, the patient's symptoms are recorded and clinical and Doppler examinations are done.

Discussion

Endovenous RFA is a minimally invasive technique for the treatment of varicose veins. In bipolar RFITT, the venous wall acts as a conductor between the two poles.^[3] The high-

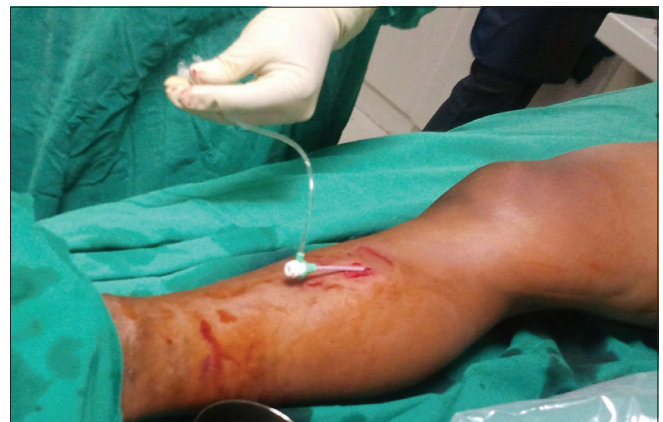

Figure 2: A 70-cm long 6F sheath is placed in the GSV; through this the RFA probe is introduced

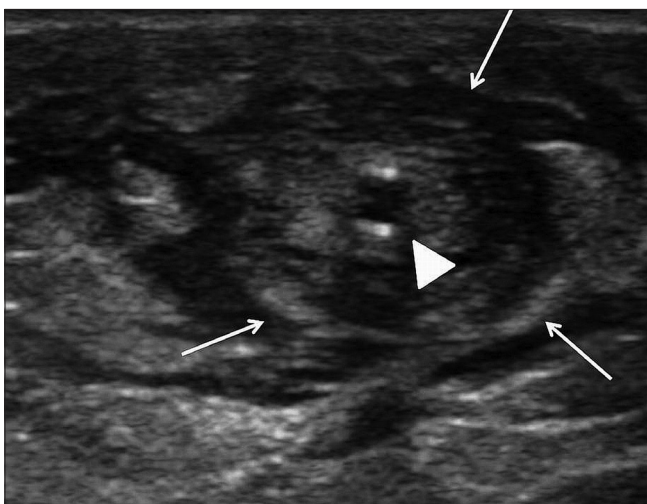

Figure 3: Transverse USG shows perivenous tumescent fluid (arrows) around the sheath in the long saphenous vein (arrowhead)

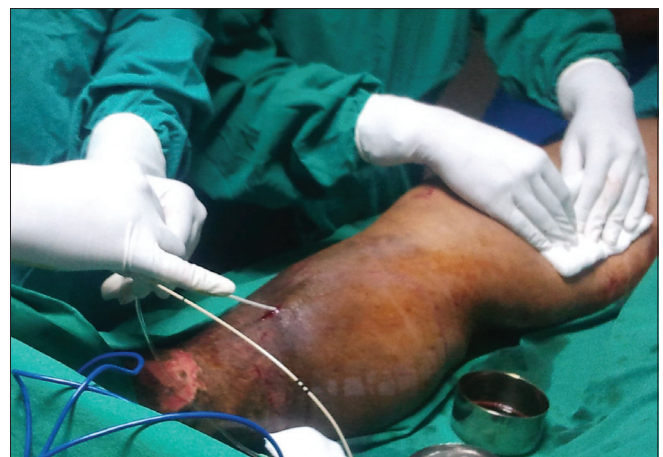

Figure 4: The sheath and RFA probe are being steadily withdrawn, at approximately 0.5 cm per second, such that the acoustic signal is maintained at a constant frequency and pitch

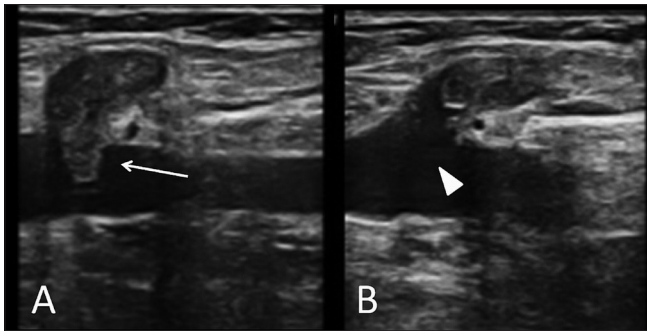


Figure 5 (A, B): Oblique sagittal USG (A) shows prolapse of thrombus (arrow) from the GSV into the superficial femoral vein. Follow-up USG (B) after anticoagulant therapy shows complete resolution of the thrombus (arrowhead) within the superficial femoral vein

frequency alternating current between the poles heats the vein wall to 85–95°C, causing shrinkage of the vein and adherence of the walls, thus resulting in total occlusion of the vessel. When large veins are involved, intravascular thrombosis is also noted.

Perala *et al.*, reported a study of patients who underwent RFA of GSV where none of the subjects showed recanalization even after 3 years.^[4] In a study by Probestle *et al.*, the vein occlusion and reflux-free rate was about 99.6% at 6 months.^[5]

The incidence of prolapse of thrombus from the GSV into the deep venous system has ranged from 0% to 16% in various studies.^[2] If this is seen at the follow-up scan in the first week, anticoagulant therapy needs to be administered [Figure 5].

Rautio *et al.*, demonstrated less postprocedural pain, shorter sick leave periods, and faster restoration of physical function in RFA patients as compared to patients treated with surgery.^[6] Stotter *et al.*, also reported lower pain score in RFA patients than in patients undergoing stripping in their randomized trial.^[7]

A randomized controlled trial by Morrison *et al.*, showed better primary obliteration and less postoperative pain and bruising in RFA compared to laser therapy of GSV.^[8]

In our initial experience of 52 patients, no recanalization

of the GSV has been seen over follow-up periods ranging from 7 to 180 days. None of the patients had any major complication, other than two cases with extension of thrombus into the common femoral vein (treated successfully with a one-week course of low-molecular-weight heparin) and one case of thrombophlebitis (treated with anti-inflammatory medication). Our patients are still being followed up.

In conclusion, endovenous RFA is a safe and effective method and an alternative to surgical procedures in the treatment of varicose veins. Even though RFA requires high doses of thermal energy, it is well tolerated by patients and has only insignificant side effects.

References

1. Sybrandy JE, Wittens CH. Initial experiences in endovenous treatment of saphenous vein reflux. *J Vasc Surg* 2002;36:1207-12.
2. Roth SM. Endovenous radiofrequency ablation of superficial and perforator veins. *Surg Clin North Am* 2007;87:1267-84.
3. Zierau UT, Lahl W. The endovenous RFITT-treatment of varicose veins, a new method of interventional phlebology. Technique and first results. *Phlebologie* 2009;38:12-6.
4. Perälä J, Rautio T, Biancari F, Ohtonen P, Wiik H, Heikkinen T, *et al.* Radiofrequency endovenous obliteration versus stripping of the long saphenous vein in the management of primary varicose veins: 3-year outcome of a randomized study. *Ann Vasc Surg* 2005;19:669-72.
5. Probestle TM, Vago B, Alm J, Göckeritz O, Lebard C, Pichot O. Treatment of the incompetent great saphenous vein by endovenous radiofrequency powered segmental thermal ablation: First clinical experience. *J Vasc Surg* 2008;47:151-6.
6. Rautio T, Ohinmaa A, Perälä J, Ohtonen P, Heikkinen T, Wiik H, *et al.* Endovenous obliteration versus conventional stripping operation in the treatment of primary varicose veins: A randomized controlled trial with comparison of the costs. *J Vasc Surg* 2002;35:958-65.
7. Stötter L, Schaaf I, Fendl R, Bockelbrink A. Radiofrequency obliteration, invagination or cryostripping: Which is best tolerated treatment by the patients? *Phlebologie* 2005;34:19-24.
8. Morrison N. Saphenous ablation: What are the choices, laser or RF energy. *Semin Vasc Surg* 2005;18:15-8.

Cite this article as: Kasi V, Kalyanpur TM, Narsinghpura K, Chakravarthy D, Mehta P, Cherian M. Bipolar radiofrequency-induced thermotherapy of great saphenous vein: Our initial experience. *Indian J Radiol Imaging* 2012;22:86-8.

Source of Support: Nil, **Conflict of Interest:** None declared.

Announcement

iPhone App



Download
**iPhone, iPad
application**

FREE

A free application to browse and search the journal's content is now available for iPhone/iPad. The application provides "Table of Contents" of the latest issues, which are stored on the device for future offline browsing. Internet connection is required to access the back issues and search facility. The application is Compatible with iPhone, iPod touch, and iPad and Requires iOS 3.1 or later. The application can be downloaded from <http://itunes.apple.com/us/app/medknow-journals/id458064375?ls=1&mt=8>. For suggestions and comments do write back to us.