

Original Article

The outcome of Jarcho–Levin syndrome treated with a functional latissimus dorsi flap – A series of three cases

Bipin A. Gangurde, Binita Raut, Rujuta Mehta¹, Mukund R. Thatte

Departments of Plastic and Reconstructive Surgery, ¹Department of Paediatric Orthopaedics, Bai Jerbai Wadia Hospital for Children, Parel, Mumbai, India

Address for correspondence: Dr. Mukund R. Thatte, 402, Vimal Smruti, 770 Ghanti road, Parsi Colony, Dadar (East), Mumbai, India. E-mail: mthatte@gmail.com, mthatte@vsnl.com.

ABSTRACT

Introduction: Jarcho-Levin syndrome is manifested by vertebral body and rib malformations. Large rib defects with paradoxical chest motion lead to early death due to progressive respiratory insufficiency, hence it is a lethal syndrome. The only means of improving survival is early stabilisation of the chest wall defect by containing the thoracic herniation. Nitcher *et al.* and Thatte *et al.* showed that reconstruction of the chest wall was life saving. Thatte *et al.* had postulated that early coverage of the lungs and thoracic contents with functional latissimus dorsi may prevent the visceral overgrowth and secondary pleural changes. **Materials and Methods:** Our three cases which had medium- and long-term follow-up help to support this postulation. Three patients were assessed retrospectively. Their ages at surgery were 6 months, 8 months and 1 year, respectively. All had laboured breathing and paradoxical respiration. All of them were operated with ipsilateral latissimus dorsi flap. **Results:** The results were evaluated clinically. The patients had reduced or no respiratory infections. The lung compliance improved and they had no tachypnoea on walking, running or playing. **Conclusion:** Hence, this can be used as a life-saving procedure for Jarcho-Levin syndrome on a long-term basis.

KEY WORDS

Functional latissimus dorsi flap; Jarcho–Levin syndrome; long-term growth

INTRODUCTION

Jarcho–Levin syndrome (JLS) is a rare developmental malformation of ribs and the vertebral column. Jarcho and Levin in 1938 had described this syndrome.^[1] In 1978, Solomon *et al.* classified JLS as spondylocostal dysostosis (SCD) and spondylothoracic dysostosis

(STD), but the revised International Nomenclature of Constitutional Diseases of Bone recommended that only the term spondylocostal dysostosis be used for all patients with vertebral segmental defects and rib anomalies.^[2] Mortier *et al.* divided JLS into three presentations: Jarcho–Levin itself for the autosomal recessive condition which is usually lethal, STD for the autosomal recessive condition with a less severe phenotype and SCD for the autosomal dominant or recessive condition with intrinsic rib anomalies, without severe thoracic impairment and usually with a better prognosis.^[3] However, for all practical purposes, they are classified into SCD and STD. The patients with this syndrome usually have paradoxical respiration due to lung herniation, which causes respiratory distress.^[4] This, along with repeated respiratory infections, unstable chest

Access this article online

Quick Response Code:



Website:

www.ijps.org

DOI:

10.4103/0970-0358.96582

wall and severe restrictive lung disease are responsible for death within the first 2 years of life.^[3]

Nichter in his case report showed that chest wall reconstruction was life saving for this syndrome with high mortality, but there was no long-term follow-up of the operated patient.^[5] Thatte and Hosalkar used latissimus dorsi flap but had the same drawback,^[6] i.e. they did not show long-term follow-up. In this paper, we describe three cases of JLS treated with functional latissimus dorsi flap, with a medium- to long-term follow-up. To the best of our knowledge, this is the only series in the literature of this rare syndrome treated with the functional latissimus dorsi flap and showing results of a long-term follow-up.

MATERIALS AND METHODS

Three patients were assessed retrospectively. We have named the patients as A, B and C. Their ages at presentation were A=6 months, B=8 months and C=1 year. All were males. A and C were an issue of nonconsanguineous marriage and B was born of consanguineous marriage. All had congenital left-sided chest wall defects and they had paradoxical respiration with laboured breathing. All were managed in the intensive care unit immediately after birth as they had breathing difficulties. All of them had repeated respiratory infections requiring hospitalisation at least three times in a month. All showed failure to thrive [Figures 1 and 2a, b].

Preoperatively, all the patients were investigated with chest radiograms. All the three showed absence of ribs on the left side of the chest with a spinal deformity. Ultrasonographic examination showed all had lung and diaphragm herniation. Patient A had herniation

of spleen. Presence of ipsilateral latissimus dorsi muscle was confirmed by clinical examination and ultrasonographic examination. Computer tomography was also done to quantify the chest defect [Figure 3].

All the patients were operated with ipsilateral functional latissimus dorsi flap.

Surgical technique

The operation was performed under thoracic epidural anaesthesia administered through an indwelling catheter in the epidural space and supplemented with nitrous oxide and halothane through mask; no paralysing agents were used. Lateral position was given where the side with chest defect was higher. A single oblique incision along the anterior border of latissimus dorsi muscle was used to expose the muscle and the chest defect [Figure 4]. Latissimus dorsi muscle was elevated along with its tendon and the neuromuscular bundle. The nerve was specifically preserved so that the muscle could act dynamically, hence it was called functional latissimus dorsi muscle transfer. The muscle was then swung over to cover the defect and secured with 3-0 Vicryl® [Figure 5]. This allowed containment of the herniation. The skin and subcuticular layer was closed over a suction drain. Oral feeds were allowed 3–4 hours after surgery. The drain was removed after significant reduction in drainage, typically at 48–72 hours. The patients were discharged in an average of 1 week after drain removal following suture removal. No external splintage was necessary. Postoperatively, in all the patients, the defect was covered with a dynamic functioning muscle cover, paradoxical respiration disappeared, and there was no lung herniation. The respiratory dynamics improved immediately.

RESULTS

At present, the patients are 10 years, 6 years, and 1 year 5 months old. They were assessed at follow-up postoperatively every month for the first 6 months, then every 3 months for the next year and later on yearly.

All of them were assessed at every follow-up with complete examination to look for herniation, from the chest wall, frequency of respiratory infections, and tachypnoea during walking, climbing stairs and playing or running [Table 1].

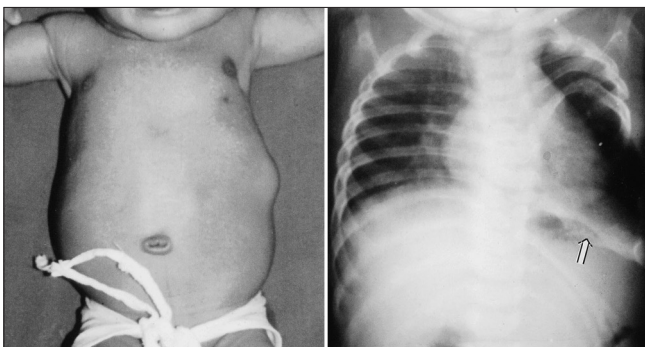


Figure 1: Clinical picture of patient A when he was a neonate, showing left-sided chest defect and chest radiograph showing rib defect

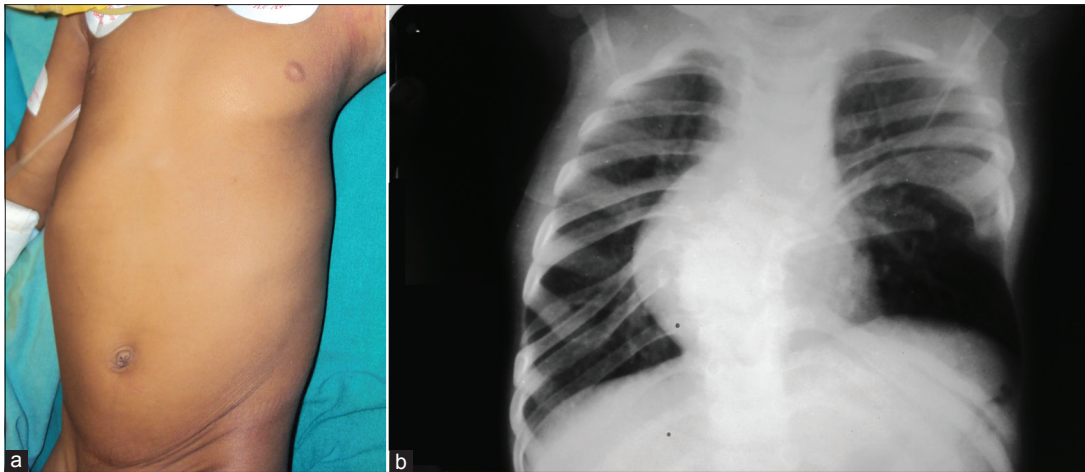


Figure 2: (a) Patient C having left-sided chest defect; (b) chest radiograph of patient C showing rib defect on the left side

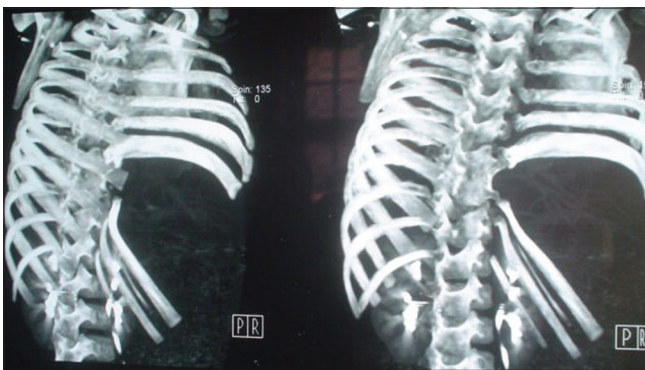


Figure 3: 3D computed tomogram showing rib defect in patient B

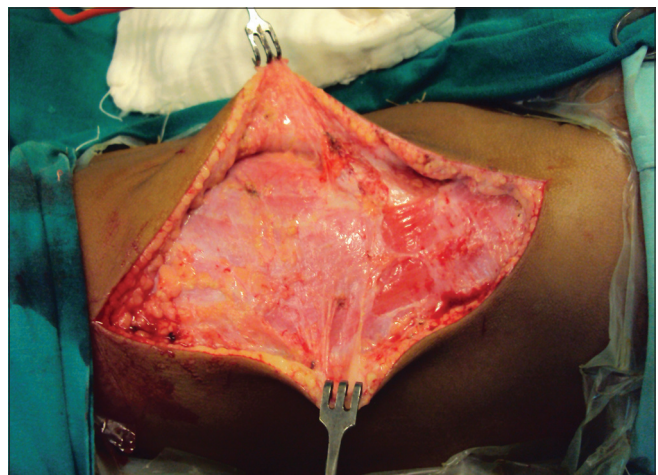


Figure 4: Incision and exposure of latissimus dorsi muscle

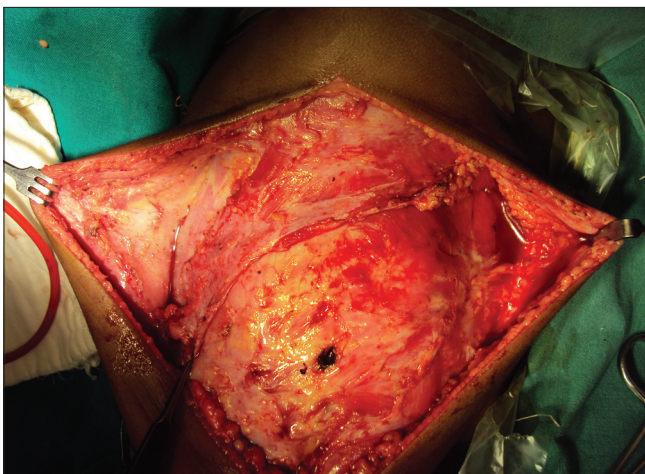


Figure 5: Latissimus dorsi muscle rotated and sutured

Table 1: Follow up of patients

	A	B	C
Months of follow-up	9 years and 2 months	5 years and 6 months	5 months
Number of respiratory infections in recent 1 year	Nil	Nil	Two episodes in 5 months (as against up to three per month)
Tachypnoea on walking and playing	Nil	Nil	Mild

The respiratory infections gradually decreased in patient A, who experienced four episodes in 8 months, then one episode twice a year and from 5 years of age has had no complaints till date. This patient was again intervened at 6 years for Sprengel's shoulder to improve the scapular position. Patient B also had a similar improvement with respiratory infections tapering down; he had initially five episodes yearly and single episode in last 2 years, with none at 6 years of his life. Patient C had a 5-month follow-up and he had experienced two episodes of respiratory infection since surgery [Figure 6].

Tachypnoea also followed a downward trend in all. Children A and B can walk and play without experiencing tachypnoea that restricts their activity. Child C experiences mild tachypnoea after running. All patients during their last follow-ups had contained chest wall defects with no herniation.

DISCUSSION

JLS has a high mortality in children; hence, elective termination of pregnancy is considered an alternative. Prenatal diagnosis using ultrasonography can diagnose the anomaly and can help in elective termination of pregnancy in the second trimester.^[7-9] Genetic counselling is also important as in the recessive form there would be 25% risk to the siblings of affected child. In the dominant form, even though the siblings would hardly be affected but the risk of affection rose to 50% for the child of a long term survivors^[10,11] Historically, various nonsurgical and surgical methods were used in the treatment of JLS. Most of the aggressive recessive types had lethal outcomes.^[3] Nonsurgical methods of bracing required repeated changes and were not able to restrict the lung herniation.^[6] Herold *et al.* had postulated that surgical corrections might help in these patients.^[12] Nichter *et al.* performed a staged reconstruction using a polypropylene mesh and reinforcing it with methyl methacrylate. Even though herniation of the lung was prevented and the patient could be weaned from the ventilator, they observed that the acrylic mesh acted as the tether which prevented the growth of the chest wall. Thus, there was a chance of developing severe restrictive disease in the near future, hence they removed the acrylic mesh.^[5]

Thatte and Hosalkar showed that the functional vascularised ipsilateral latissimus dorsi flap prevented the lung herniation and paradoxical respiration. They observed in their case that the patient's respiratory dynamics improved immediately after the surgery. They also observed that the functional muscle adapted well with the chest dynamics.^[6] Even though genetic studies were not done in our cases, the fact that all the patients had failure to thrive indicates that they might be recessive types.

Patient A in our series is the same patient reported by Thatte and Hosalkar. The other two patients have also been operated by the senior author. Patient A is now 10 years of age with no respiratory infections, no tachypnoea at play and no contracture of the chest wall. The muscle has adapted itself with the body growth and the chest dynamics, and in fact has grown with the child [Figure 7].

Thus, latissimus dorsi cover for JLS helps in survival of these patients. However, the scoliotic deformity of the

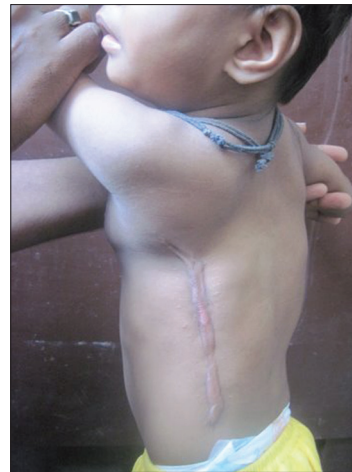

Figure 6: Patient C at 8 months showing healed scar

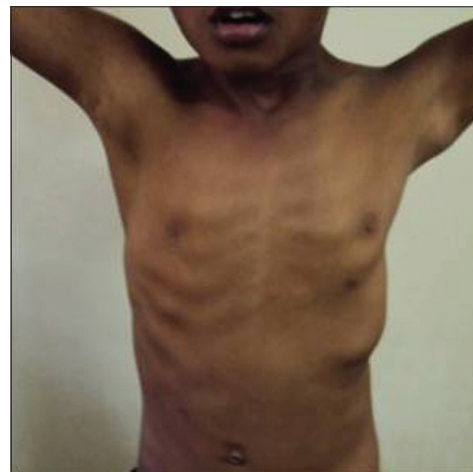


Figure 7: Patient A's clinical picture of follow-up after 10 years

spine is difficult to correct. This deformity may lead to restrictive lung disease and neurological problems if the deformity progresses. Vertically expanding titanium prosthesis might offer a benefit to these patients and help them achieve a straight spine with growth.^[13] Child A is now under the care of the Spine Surgeons for this consideration. This would also help in improving the lung compliance. Hence, we recommend that patients with JLS with distress should initially be treated with a latissimus dorsi flap as a life-saving procedure and later on treated for scoliotic correction.

ACKNOWLEDGMENT

The Plastic and Orthopaedic Surgery departments of Bai Jerbai Wadia Hospital are acknowledged.

REFERENCES

1. Jarcho S, Levin PM. Hereditary malformation of the vertebral
Indian Journal of Plastic Surgery January-April 2012 Vol 45 Issue 1

- bodies. Bull Johns Hopkins Hosp 1938;62:216-26.
2. International Nomenclature of Constitutional Diseases of Bone: Revision, May 1977. Am J Med Genet 1979;3:21-6.
 3. Mortier GR, Lachman RS, Bocian M, Rimoin DL. Multiple vertebral segmentation defects: Analysis of 26 new patients and review of the literature. Am J Med 1996;61:310-91.
 4. Karnes PS, Deborah D, Berry S, Pierpont M. Jarcho-Levin syndrome: Four new cases and classification of subtypes. Am J Med Genet 1991;40:264-70.
 5. Nichter LS, Chapin SD, Wells, Downey SE. Chest wall reconstruction for spondylocostal dysostosis. Plast Reconstr Surg 1993;92:746-9.
 6. Hosalkar H, Thatte MR, Yagnik MG. Chest wall reconstruction in spondylocostal dysostosis: Rare use of Latissimus dorsi flap. Plast Reconstr Surg 2002;110:537-40.
 7. Perez-Comas A, Garcia-Castro JM. Prenatal diagnosis of OFCTAD dysplasia or Jarcho-Levin syndrome. Birth Defects 1979;15:39.
 8. Tolmie JL, Whittle MJ, McNay MB, Gibson AA, Connor JM. Second trimester prenatal diagnosis of the Jarcho-Levin syndrome. Prenat Diagn 1987;7:129-34.
 9. Romero R, Ghidini A, Marthanda EA, Margretta SR. Prenatal findings in a case of spondylocostal dysplasia type I. Obstet Gynecol 1988;71:988-91.
 10. Roberts AP, Conner AN, Tolmie JL, Connor JM. Spondylothoracic and spondylocostal dysostosis. Hereditary forms of spinal deformity. J Bone Joint Surg Br 1988;70:123-6.
 11. Aslan Y, Erduran E, Mocan H, *et al.* Multiple vertebral segmentation defects: Brief reports of three patients and nosological consideration. *Genet Couns.* 1997;8:241-248.
 12. Herold H, Michael E, Baruchin A. Spondylothoracic dysplasia: A report of ten cases. Spine 1988;13:478-81.
 13. Campbell RM, Anna K. Growth of thoracic spine in congenital scoliosis after expansion thoracoplasty. J Bone Joint Surg Am 2003;85-A:409-20

How to cite this article: Gangurde BA, Raut B, Mehta R, Thatte MR. The outcome of Jarcho-Levin syndrome treated with a functional latissimus dorsi flap - A series of three cases. Indian J Plast Surg 2012;45:40-4.

Source of Support: Nil, **Conflict of Interest:** None declared.

Staying in touch with the journal

1) Table of Contents (TOC) email alert

Receive an email alert containing the TOC when a new complete issue of the journal is made available online. To register for TOC alerts go to www.ijps.org/signup.asp.

2) RSS feeds

Really Simple Syndication (RSS) helps you to get alerts on new publication right on your desktop without going to the journal's website. You need a software (e.g. RSSReader, Feed Demon, FeedReader, My Yahoo!, NewsGator and NewzCrawler) to get advantage of this tool. RSS feeds can also be read through FireFox or Microsoft Outlook 2007. Once any of these small (and mostly free) software is installed, add www.ijps.org/rssfeed.asp as one of the feeds.