

Case Report

Revision breast and chest wall reconstruction in Poland and pectus excavatum following implant complication using free deep inferior epigastric perforator flap

Dimitrios Dionyssiou, Efterpi Demiri, Georgios Batsis, Leonidas Pavlidis

Department of Plastic Surgery, Medical School, Papageorgiou Hospital, Aristotle University of Thessaloniki, Periferiaki odos Thessalonikis, Thessaloniki 56403, Greece

Address for correspondence: Dr. Dimitrios Dionyssiou, Department of Plastic Surgery, Medical School, Papageorgiou Hospital, Aristotle University of Thessaloniki, Periferiaki Odos Thessalonikis, Thessaloniki 56403, Greece. E-mail: ddionyssiou@gmail.com

ABSTRACT

This study aims to present the case of a female patient with Poland's syndrome and pectus excavatum deformity who underwent breast and chest wall reconstruction with a pre-shaped free deep inferior epigastric perforator flap. A 57-year-old female patient with Poland's syndrome and pectus excavatum presented with a Baker III capsular contracture following a previously performed implant-based right breast reconstruction. After a chest and abdominal CT angiography, she was staged as 2A1 chest wall deformity according to Park's classification and underwent implant removal and capsulectomy, followed by a pre-shaped free abdominal flap transfer, providing both breast reconstruction and chest wall deformity correction in a single stage operation. Post-operative course was uneventful, and the aesthetic result remains highly satisfactory 24 months after surgery. Deep inferior epigastric free flap represents an interesting reconstructive solution when treating Poland's syndrome female patients with chest wall and breast deformities.

KEY WORDS

Deep inferior epigastric perforator flap; pectus excavatum; Poland's syndrome

INTRODUCTION

Poland's syndrome is characterised by unilateral chest wall and upper limb abnormalities, with an incidence of 1:30,000-100,000 live births.^[1] The thoracic manifestations may vary from mild hypoplasia to complete absence of the pectoralis major muscle and/or costal cartilages, breast and nipple hypoplasia or aplasia and ipsilateral upper limb anomalies.^[1,2]

Many surgical procedures have been described to address breast reconstruction. Reconstructive procedures such as use of tissue expanders and silicone implants, pedicle flaps, autologous fat graft and free microvascular flaps have been previously described.^[3-6] Deep inferior epigastric perforator (DIEP) flap has become the workhorse for breast reconstruction, but its use for Poland's syndrome has rarely been reported in the literature.^[6]

Poland's syndrome, although frequently presents with thoracic deformities, is rarely associated with pectus excavatum. Pectus excavatum represents the most common congenital chest wall deformity.^[7] Indications for surgical reconstruction of pectus excavatum deformities is based on classification systems and include more commonly aesthetic considerations and rarely chest wall reconstruction or cardiovascular insufficiency.^[8]

Access this article online	
Quick Response Code: 	Website: www.ijps.org
	DOI: 10.4103/0970-0358.155277

CASE REPORT

A 57-year-old female patient presented with a painful right breast in a previously implant based right breast reconstruction for correction of Poland syndrome [Figure 1].

Clinical examination revealed hypoplasia of the right breast, absence of the right pectoralis major muscle, ipsilateral upper limb anomalies and pectus excavatum chest wall deformity without cardiac or respiratory impairment [Figure 2]. A Baker III capsular contracture was observed in the right reconstructed breast and a volume deficit over the inner and lower poles, compared with the left side, was also noted.

The patient was seeking treatment of the painful breast and aesthetic improvement of both the breast symmetry

and the sternal depression. CT angiography imaging of the chest and abdomen showed a 2A1 pectus excavatum chest wall deformity according to Park's classification [Figure 3], as well as a hypoplastic appearance and a substernal displacement of the internal mammary vessels. A free DIEP flap was considered for reconstruction.

After the implant and capsule removal, a new subglandular pocket was prepared, extending from the mid-axillary line to the left border of the sternum and from the manubrium to the xiphoid process. Thoracodorsal artery and vein were prepared to accommodate the flap. At the same time a pre-shaped DIEP flap based on the size of the contralateral breast was raised and anastomosed to the thoracodorsal vessels [Figure 4]. Almost the whole flap was de-epithelialised, sutures were placed to maintain the pre-shaped breast mound and buried into the prepared skin pocket to reconstruct the breast, providing both breast

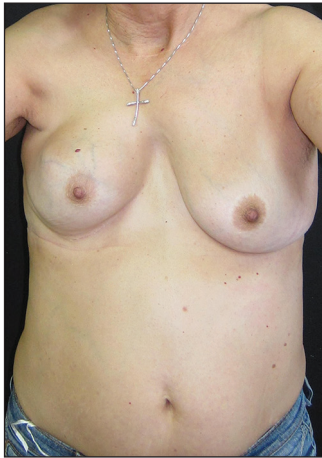

Figure 1: A 57-year-old female Poland's syndrome patient with a Baker III capsular contracture on her previously implant based right breast reconstruction

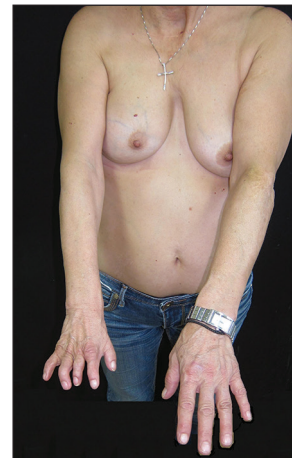

Figure 2: Volume deficits at the inner and lower poles of the right breast, and at the sternum are observed in association with ipsilateral upper limb anomalies

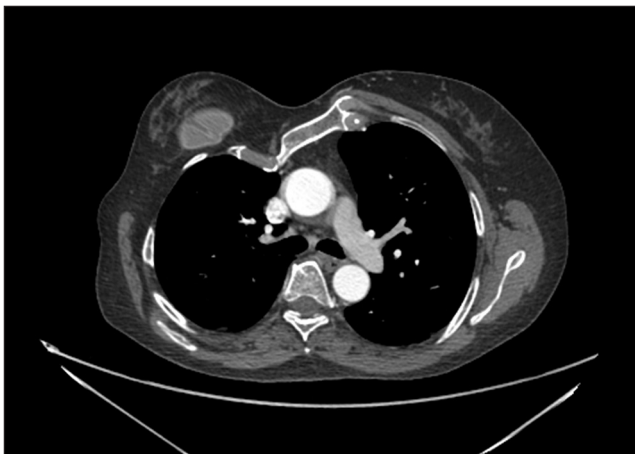


Figure 3: Computed tomography angiography of the chest shows a 2A1 pectus excavatum chest wall deformity according to Park's classification, as well as a hypoplastic appearance and a substernal displacement of the internal mammary vessels

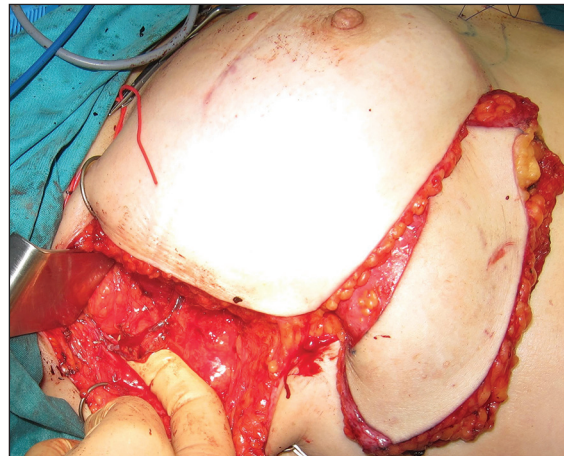


Figure 4: A new subglandular pocket was prepared, and the flap vessels were anastomosed to the thoracodorsal artery and vein in an end-to-end fashion

projection and pendulous appearance, and also forming the anterior axillary line in the area of the pectoralis major tendon and filling the depressed chest and sternum area. A small 2 cm × 1 cm skin island was left intact and placed at the inframammary fold for flap monitoring. Nylon bolster sutures were placed through the skin to the adipose tissue of the flap and remained for 2 weeks to secure the flap position and avoid any flap displacement.

Post-operative period was uneventful and at 24 months' follow-up the patient was free of pain over the right breast and highly satisfied with the aesthetic breast and chest wall appearance [Figures 5 and 6].

DISCUSSION

A number of surgical interventions for aesthetic correction of congenital breast and chest wall deformities have been described in the literature, such as tissue expansion, silicone implant and customized silicone prosthesis, pedicle flaps, autologous fat graft and free microvascular flaps.

Borschel *et al.* presented a series of 29 Poland's syndrome cases, including 8 male and 21 female patients; tissue expanders and/or implants were most commonly used in the female subgroup, a latissimus dorsi (LD) muscle flap with breast implant was performed in 4 cases and a custom-made chest wall implant in 1 case. Reported complication rates were reasonably low.^[3]

Latissimus dorsi muscle flap was mainly used in Papadopulos *et al.* study looking for changes in quality of life of the operated Poland syndrome patients.^[9]

Satisfactory outcome was achieved; concluding that the patients were satisfied or highly satisfied with their appearance and would recommend the same surgery to others under similar circumstances.

Fat grafting procedures have also been used by Yang and Lee for breast reconstruction in Poland's syndrome patients.^[5] Although they are simple procedures, fat grafting breast reconstructions have two main drawbacks; first, their results are largely inconsistent, mainly due to the variable amount of fat resorption after a lipo-filling session and second, the need for multiple fat grafting surgeries to achieve a satisfying outcome.

Deep inferior epigastric perforator flap is described in the literature as one of the microvascular options for correcting chest wall and breast deformities in Poland's syndrome.^[6] Liao presented a case report of a 52-year-old woman with severe chest wall deformity and breast hypoplasia who was treated with a free DIEP flap anastomosed to the internal mammary vessels.^[6]

The use of free tissue transfer tends to become the modern workhorse for reconstructing congenital chest wall abnormalities. Gautam *et al.*, presented a series of 8 Poland's syndrome cases, who were treated using microvascular perforator flaps; 4 superior gluteal artery perforator, 2 inferior gluteal artery perforator, 1 superficial inferior epigastric artery and 1 DIEP flap.^[4] Although all flaps survived, a relatively high complication rate was reported by the authors. However, donor-site morbidity is lower, functional compromise is less and recovery time is faster, as compared to LD muscle flap transfer procedures.

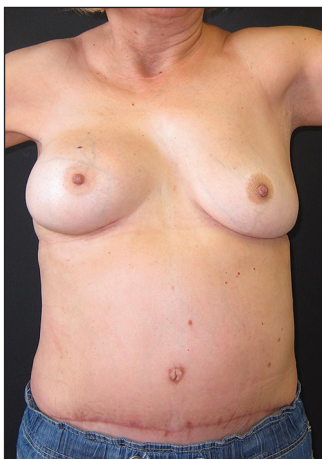

Figure 5: The patient remains free of pain and aesthetically pleased at 24 months follow-up

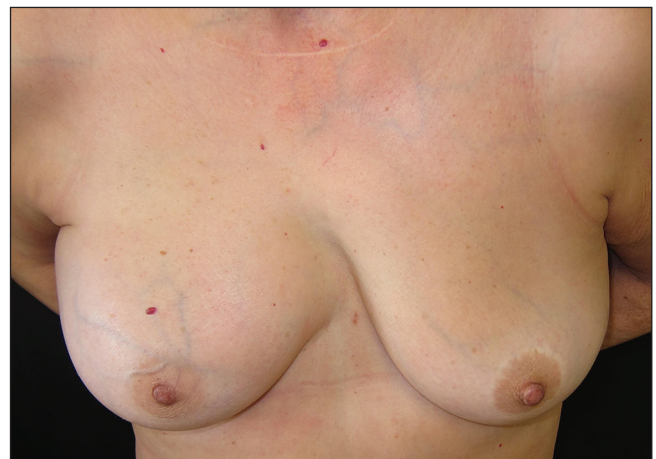

Figure 6: Reconstruction of the depressed sternum and of the inner breast pole was achieved

In our case, the reconstructive challenge was not only the replacement of the missing breast volume in order to achieve symmetry, but also the correction of both the anterior axillary fold due to the absence of the pectoralis major tendon, and the sternal depression due to funnel chest deformity. The use of de-epithelialized DIEP flap successfully addressed the patients' requirements.

CONCLUSION

The free DIEP flap should be considered a valuable reconstructive option for simultaneous correction of Poland's syndrome deformities and pectus excavatum depression; it provides adequate adipose tissue to replace both the missing breast volume and the sternal deficit; its long pedicle allows microvascular anastomoses either in the internal mammary or the thoracodorsal vessels. The need for larger tissue volume in female Poland's syndrome patients also makes DIEP flaps preferable to other autologous tissue.

REFERENCES

1. Zhu L, Zeng A, Wang XJ, Liu ZF, Zhang HL. Poland's syndrome in women: 24 cases study and literature review. *Chin Med J (Engl)* 2012;125:3283-7.
2. Fokin AA, Robicsek F. Poland's syndrome revisited. *Ann Thorac Surg* 2002;74:2218-25.
3. Borschel GH, Costantino DA, Cederna PS. Individualized implant-based reconstruction of Poland syndrome breast and soft tissue deformities. *Ann Plast Surg* 2007;59:507-14.
4. Gautam AK, Allen RJ Jr, LoTempio MM, Mountcastle TS, Levine JL, Allen RJ, *et al.* Congenital breast deformity reconstruction using perforator flaps. *Ann Plast Surg* 2007;58:353-8.
5. Yang H, Lee H. Successful use of squeezed-fat grafts to correct a breast affected by Poland syndrome. *Aesthetic Plast Surg* 2011;35:418-25.
6. Liao HT, Cheng MH, Ulusal BG, Wei FC. Deep inferior epigastric perforator flap for successful simultaneous breast and chest wall reconstruction in a Poland anomaly patient. *Ann Plast Surg* 2005;55:422-6.
7. Dean C, Etienne D, Hindson D, Matusz P, Tubbs RS, Loukas M. Pectus excavatum (funnel chest): A historical and current prospective. *Surg Radiol Anat* 2012;34:573-9.
8. Frantz FW. Indications and guidelines for pectus excavatum repair. *Curr Opin Pediatr* 2011;23:486-91.
9. Papadopulos NA, Eder M, Stergioula S, Teymouri HR, Mavroudis MC, Herschbach P, *et al.* Women's quality of life and surgical long-term outcome after breast reconstruction in Poland syndrome patients. *J Womens Health (Larchmt)* 2011;20:749-56.

How to cite this article: Dionyssiou D, Demiri E, Batsis G, Pavlidis L. Revision breast and chest wall reconstruction in Poland and pectus excavatum following implant complication using free deep inferior epigastric perforator flap. *Indian J Plast Surg* 2015;48:85-8.
Source of Support: Nil, **Conflict of Interest:** None declared.

Announcement

Subscription Information

Copies of the journal are provided free of cost to the member of the ASSOCIATION OF PLASTIC SURGEONS OF INDIA. A subscription to Journal of Indian Journal of Plastic Surgery comprises 3 issues. Prices include postage. Annual Subscription Rate for non-members-

- Institutional: INR 2400.00 for India and USD 210.00 for outside India
- Personal: INR 1500.00 for India and USD 120.00 for outside India

For mode of payment and other details, please visit www.medknow.com/subscribe.asp.

Claims for missing issues will be serviced at no charge if received within 60 days of the cover date for domestic subscribers, and 3 months for subscribers outside India. Duplicate copies cannot be sent to replace issues not delivered because of failure to notify publisher of change of address.

The journal is published and distributed by Medknow Publications and Media Pvt. Ltd. Copies are sent to subscribers directly from the publisher's address. It is illegal to acquire copies from any other source. If a copy is received for personal use as a member of the association/society, one cannot resale or give-away the copy for commercial or library use.

The copies of the journal to the members of the association are sent by ordinary post. The editorial board, association or publisher will not be responsible for non receipt of copies. If any member/subscriber wishes to receive the copies by registered post or courier, kindly contact the publisher's office. If a copy returns due to incomplete, incorrect or changed address of a member/subscriber on two consecutive occasions, the names of such members will be deleted from the mailing list of the journal. Providing complete, correct and up-to-date address is the responsibility of the member/subscriber.

Nonmembers: Please send change of address information to subscriptions@medknow.com.