

Original Article

A new paradigm in facial reanimation for long-standing palsies?

Rajeev B. Ahuja, Pallab Chatterjee¹, Rajat Gupta, Prabhat Shrivastava, Gaurav K. Gupta²

Department of Burns, Plastic, Maxillofacial and Microvascular Surgery, Maulana Azad Medical College, Lok Nayak Hospital, ¹Department of Plastic Surgery, Command Hospital Air Force, Bengaluru, Karnataka, ²Department of Plastic Surgery, BL Kapur Hospital, New Delhi, India

Address for correspondence: Dr. Rajeev B. Ahuja, Department of Burns, Plastic, Maxillofacial and Microvascular Surgery, Lok Nayak Hospital and associated Maulana Azad Medical College, New Delhi - 110 002. E-mail: rbahuja@gmail.com

ABSTRACT

Background: A chance observation of return of excellent facial movement, after 18 months following the first stage of cross-face nerve grafting, without free functional muscle transfer, in a case of long-standing facial palsy, lead the senior author (RBA) to further investigate clinically. **Patients and Methods:** This procedure, now christened as cross-face nerve extension and neurotization, was carried out in 12 patients of very long-standing facial palsy (mean 21 years) in years 1996-2011. The mean patient age and duration of palsy were 30.58 years and 21.08 years, respectively. In patients, 1-5 a single buccal or zygomatic branch served as a donor nerve, but subsequently, we used two donor nerves. The mean follow-up period was 20.75 months. **Results:** Successive patients had excellent to good return of facial expression with two fair results. Besides improved smile, patients could largely retain air in the mouth without any escape and had improved mastication. No complications were encountered except synkinesis in 1 patient. No additional surgical procedures were performed. **Conclusion:** There is experimental evidence to suggest that neurotization of a completely denervated muscle can occur by the formation of new ectopic motor end plates. Long-standing denervated muscle fibres eventually atrophy severely but are capable of re-innervation and regeneration, as validated by electron microscopic studies. In spite of several suggestions in the literature to clinically validate functional recovery by direct neurotization, the concept remains anecdotal. Our results substantiate this procedure, and it has the potential to simplify reanimation in longstanding facial palsy. Our work now needs validation by other investigators in the field of restoring facial animation.

KEY WORDS

Cross face nerve grafting; facial palsy; facial reanimation; neurotization

Video available on www.ijps.org

Access this article online

Quick Response Code:



Website:

www.ijps.org

DOI:

10.4103/0970-0358.155265

INTRODUCTION

Facial reanimation in long-standing palsy is extremely challenging. Cross-facial nerve grafting with free-muscle transfer has become the accepted method to restore spontaneous smile in patients with long-standing facial paralysis,^[1] as is evident by several landmark publications on the topic.^[2-5] This two-staged approach utilizing a cross-facial nerve graft (CFNG) and subsequent free functional muscle transfer (FFMT) while an effective

and 'state of the art' technique, can be disappointing on several parameters because of inconsistent results.^[6] It is felt that an early axonal penetration is essential to prevent muscle atrophy^[6] and a 'babysitter' procedure has been designed to provide axonal input to the free muscle graft in the first stage^[7] to keep the motor end plates 'alive' till neural input starts from the CFNG. Dissatisfied with the time lag in restoration of useful facial animation in a two-staged approach, many investigators proposed a one-stage reconstruction using a free-muscle transfer with a long supplying nerve to reach the contralateral facial nerve.^[8-12] Even if results are promising with this single staged approach they are not superior to current two staged procedures.^[1,13] To further shorten the period of fresh axonal input into the motor end plates, it has been alternatively proposed that the ipsilateral masseteric nerve may serve as a permanent donor motor nerve.^[14,15] Ipsilateral masseteric nerve may be more acceptable as a motor donor in selective cases for an earlier restoration of animation, with the hope that cerebral plasticity over a period of time may result in an acceptable smile, albeit a bit less symmetrical and synchronous.^[15,16] Another concern besetting the single staged or two-staged approach to facial reanimation is the need for supplemental interventions to adjust muscle bulk, tension, anchoring and support, etc.^[13] It has been mentioned that CFNG with free muscle transfer procedure should be offered as a three-stage concept to optimize the results.^[17]

The senior author (RBA) started facial reanimation in long-standing palsies with classic cross-face nerve transfer with pectoralis minor or gracilis muscle transfers in 1989. A surgical technique with the inherent need for a long-term follow-up was fraught with difficulties in the developing world where the rigours of life compel patients to address livelihood issues before returning for a follow-up visit for enhanced facial expression! Many patients were lost to follow-up after the first stage itself, but those who returned underwent the second stage at 9-10 months. They were only benefitted by excellent static symmetry and the functional transferred muscle yearning for adjustment of tension. If the patient could afford a gold weight, it was placed in the eyelid, or else a temporalis transfer or tarsorrhaphy was carried out in the first stage. No patient ever returned/consented for the third stage in this experience till 1996. With little to show by way of 'dynamic' results disheartenment crept in, but the craft was pursued doggedly. In personal communications, similar experience was shared by many

plastic surgeons transcending boundaries. A high volume work with close follow-ups was recognised as additional requirements to surgical skill set to obtain some excellent results with CFNG + FFMT.

Serendipity changed this state of despair, when in 1997, a patient returned for the second stage after almost 18 months, and after us having assumed him being lost to follow-up. Astonishingly, his excellent facial movements and symmetry, although unexplainable, opened a fresh paradigm which lead us to review basic science literature, work on a hypothesis, and substantiate it with more surgical evidence.

PATIENTS AND METHODS

Between 1996 and 2011, we carried out cross-face nerve transfer procedures in 12 patients of very long-standing facial palsy. Patient age ranged from 14 to 44 years (mean 30.58 years, median 29 years), and the duration of palsy ranged from 5 to 40 years (mean 21.08 years, median 19.5 years). Table 1 reflects the patient demographic details, duration of palsy, surgical procedure and duration of follow-up. This report conforms to Helsinki declaration and its amendments.

Surgical procedure

We prefer to call this procedure cross-face nerve extension and 'neurotization' (CFNEN) procedure. A preauricular incision is combined with Risdon's incision for exposing the facial nerve branches, on the normal side, as they pass under the superior and anterior borders of the parotid. All steps of the procedure are performed under 6× to 8× loupe magnification. In the initial part of our experience (patients 1-5), a single buccal or zygomatic branch of substantial caliber was identified as a donor nerve. Subsequently, we used two donor nerves on the non-paralysed side. A single medial sural nerve, harvested simultaneously, served as a graft for extending the facial nerve branch(s) to the paralysed side. Sural nerve graft was reversed in first 5 patients, and tunnelled through upper lip, except in patient 2 where a short nerve graft was retrieved intra-orally by a left lower labial sulcus incision, and then inserted amongst muscle fibres of depressor labii inferioris and angularis. In the patients 6-12 either an interfascicular dissection of the sural graft provided two individual fascicles for co-aptation or else a sural communicating nerve was harvested simultaneously. In these patients (patients 6-12), the sural nerve graft

Table 1: Patient demographic variables, aetiology, duration of palsy, follow-up, patient assessment and objective scoring on Terzis grading system (reference 5)

Patient	Sex	Age (years)	Cause	Side	Grade	Duration (years)	Procedure	Follow-up (months)	Patient satisfaction	Score on Terzis grading
1	Male	39	Bell's palsy	Right	Complete palsy	35	CFNEN to pre-tragal area	18	Excellent	IV
2	Female	19	Unknown	Left	Partial palsy	5	CFNEN to left DLI and angle of mouth	12	Excellent	V
3	Female	28	Bell's palsy	Left	Complete palsy	19	CFNEN to pre-tragal area	18	Very good	III
4	Male	30	Bell's palsy	Right	Complete palsy	22	CFNEN to pre-tragal area	16	Good	III
5	Male	55	Parotidectomy	Left	Complete palsy	8	CFNEN to pre-tragal area	14	Good	III
6	Male	36	Congenital	Left	Complete palsy	36	CFNEN to mid cheek region	40	Excellent	V
7	Female	14	Bell's palsy	Right	Complete palsy	12	CFNEN to pre-tragal area	14	Fair	II
8	Male	24	Congenital	Right	Complete palsy	24	CFNEN to mid cheek region	24	Very good	IV
9	Female	26	Bell's palsy	Left	Complete palsy	20	CFNEN to pre-tragal area	18	Good	III
10	Female	30	Bell's palsy	Left	Complete palsy	17	CFNEN to pre-tragal area	19	Fair	II
11	Male	22	Bell's palsy	Left	Near complete palsy	15	CFNEN to pre-tragal area	26	Very good	IV
12	Female	44	Bell's palsy	Left	Complete palsy	40	CFNEN to pre-tragal area	30	Excellent	V

Excellent: Symmetrical smile with teeth showing, full contraction (V); Good: Symmetry, nearly full contraction (IV); Moderate: Moderate symmetry, moderate contraction, mass movement (III); Fair: No symmetry, bulk, minimal contraction (II); Poor: Deformity, no contraction (I). CFSNG: Cross-face sural nerve graft, DLI: Depressor labii inferioris, CFNEN: Cross-face nerve extension and neurotization

was used without reversing. Skin tunnelling, although blind, was facilitated by naso-labial skin incisions and kept over the superficial muscular aponeurotic system on the paralysed side. In patient 1 and patients 3-9, the end of the sural nerve graft was placed in pre-tragal region on the paralysed side. A 6 '0' prolene suture was used to mark the epineurium (but not anchor) at the end of the nerve graft, which was then turned toward the cheek. Prolene suture ends were long enough to reach back the pre-tragal incision. As a matter of principle, the sural nerve graft end was never strangulated by the prolene suture. For last 3 patients, the procedure was similar but the end of the nerve graft was cut short to lie about 3 cm anterior to pre-tragal region to overlie the region of zygomaticus major and levator labii superioris. To address lagophthalmos, a gold weight was inserted either during the stage of nerve grafting or in a short procedure carried out independently, only if the patient could afford it.

Except for the index patient [patient 1, Table 1] where a two-staged procedure of CFNG + FFMT was planned (but not executed) we intended a CFNEN procedure in the remaining 11 patients. In patients 3-9 although we intended a CFNEN procedure we were prepared to execute the second stage of FFMT should there be insufficient return of facial movement.

Axonal growth through the graft was monitored by a progressive reverse Tinel's sign. Patient satisfaction level was recorded at each follow-up visit after 12 months of surgery. Photographic records were maintained.

RESULTS

It can be observed from Table 1 that all 12 patients had very long-standing facial palsy (average 21 years) of one side of the face. The aetiology of facial palsy is listed in Table 1. There were eight patients as a result of Bell's palsy, two were congenital, one followed a parotidectomy, and the cause could not be ascertained in 1 patient. 8 patients had palsy on the left side and four on the right side. Patients were equally distributed between the sexes. The facial paralysis was complete in 10 patients and nearly complete in 1 patient. The patient with near complete palsy had a weak eye closure but no lagophthalmos and very mild facial contractions on extreme grimacing. 1 patient had palsy of only the left sided lip depressors (patient 2), and for which the cause could not be ascertained.

A gold weight was inserted to correct lagophthalmos in 6 patients. 1 patient had a temporalis muscle transfer for eye closure. 1 patient did not need any procedure as eye closure was just sufficient. Remaining 4 patients had no procedure for correction of lagophthalmos as they seemed somewhat compensated over the long period of palsy and gave no history of any corneal problem resulting from the deformity; neither could they afford a gold weight.

The return of facial expression of the index patient observed at first follow-up visit at 18 months was baffling [Figure 1] as it surpassed all previous results of the senior author with the two staged CFNG + FFMT

procedure. Such forceful and symmetrical return of function was totally unexpected. Most of the successive patients, thereafter, had excellent to a good return of facial expression [Figures 2-4 and video 1 and 2]. The level of patient satisfaction and a retrospective scoring of results on Terzis and Noah scoring system^[5] is reflected in Table 1. 2 patients were only 'fairly' satisfied with the procedure, partly because of less return of animation and partly because of high expectations. In patient 11, we observed a synkinetic movement of the upper portion of the orbicularis oculi with facial excursion. This patient otherwise had a reasonable lid closure

preoperatively. The mean follow-up period was 20.75 months (range 12-40 months). Although return of facial movements and function were not rated objectively in a prospective manner, postoperatively all patients (patient 2 not included) could reasonably retain air in the mouth, without any escape, when cheeks were blown out. They all also reported improved mastication. There was no return of movement in frontalis and the lip depressors (except patient 2).

As mentioned earlier, synkinesis was observed in only patient 11. No complications like hematoma or skin necrosis were encountered, and all patients healed

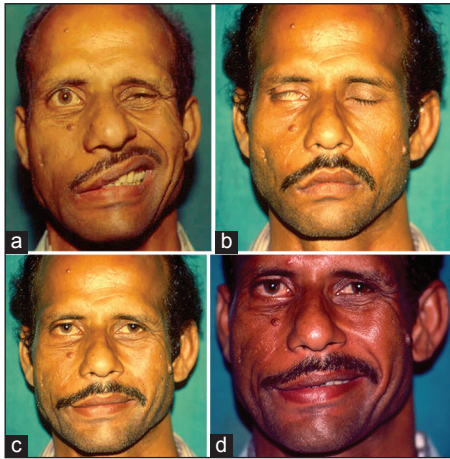

Figure 1: Patient 1 (index case) - a 39 years male with right side Bell's palsy of 35 years duration. (a) preoperatively demonstrating extreme deviation of left oral commissure on movement (b) preoperative facial position in repose. Also showing right lagophthalmos (c) at first follow-up visit after 18 months of cross-facial nerve grafting. Patient is attempting to smile with obvious excursion of the right oral commissure. The gold weight in right upper eyelid is noticeable (d) a very symmetrical smile is maintained even after extra exertion (follow-up visit of 18 months)

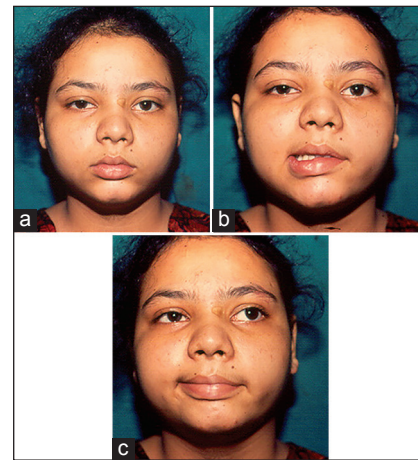

Figure 2: Patient 2 - a 19 years girl with isolated palsy of left lower lip and commissure depressors of 5 year duration. (a) Perfect preoperative symmetry at rest (b) lower lip movement unmasking the palsy of left lower lip depressors (c) excellent symmetry seen at 12 months follow-up following cross-facial nerve grafting to left lower lip depressors

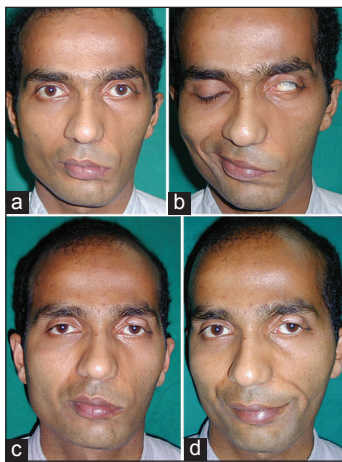

Figure 3: Patient 6 - A 36 years old priest with left-sided congenital facial palsy. (a) Lip asymmetry in repose (b) lack of any left-sided excursion on forceful smile. Severe lagophthalmos is also noticeable (c) at 15 months follow-up the patient shows improved symmetry of lips in repose. A gold weight placed to correct lagophthalmos can be noticed (d) at 40 months follow-up the patient shows excellent and perfect symmetry on smiling

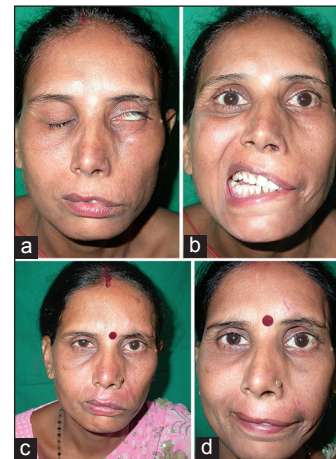

Figure 4: Patient 12 - a 44 years old lady with left sided Bell's palsy of over 40 years duration. (a) preoperatively patient is showing some facial asymmetry in repose (b) gross asymmetry and lack of left-sided lip excursion is noticed when patient attempts to smile forcefully (she actually ends up grimacing instead of smiling because of distress) (c) at 30 months follow-up, the patient shows improved symmetry in repose (d) a happy patient with excellent symmetry on smiling at 30 months follow-up

uneventfully. No secondary surgical procedures were carried out except for correction of lagophthalmos, as mentioned above. No additional sensory deficit was noticed in patients in whom the lateral sural communicating branch was harvested.

DISCUSSION

Quite logically, had there been any potential in the native motor end plates of the paralysed side to recover, the procedure of choice would have been CFNG to a distal end of the paralysed nerve as it would have restored movement in all facial muscles to achieve normalcy. Unfortunately, the native motor end plates atrophy rapidly and axons delivered to them beyond 8-9 months are fraught with failure in reactivating them. In this scenario, axonal input to FFMT with a CFNG from the nonparalysed side does bring synchronicity to smile, and this procedure remains the best-validated option to restore symmetry and expression to the paralysed face in long-standing palsy. Notwithstanding that the FFMT to the paralysed face is called upon to mimic the action of several superficial skeletal facial muscles which not only have a bilateral synchronous movement, but also work in tandem with each other for nuanced facial expressions. It seems in the sequential evolution of these procedures we missed the possibility of clinically exploring CFNEN as another viable option. Perhaps, this resulted from a blanket rejection of the term 'neurotization' when results of Thompson's procedure^[18] were not plausible enough for replication. The strength of the movement of a nonvascularised muscle graft, 'neurotized' by placement over an innervated muscle, could only enunciate a principle without clinical application. With the advent of microsurgery, at that time, the emphasis was directed to transferring a vascularised muscle, and innervating it, to obtain function. At the same time, it seems, we missed clinically investigating significant related publications which endorse and validate direct muscle 'neurotization' by nerve implantation. Recently, Terzis and Karypidis^[19] published their experience with direct muscle neurotization to augment facial expression as part of multistage facial animation, but only when muscle retained a degree of native innervation as demonstrated by some electromyography activity. Our report deals with long-standing facial palsy where neurotization has been achieved by CFNG.

The concept of muscle neurotization by direct nerve implantation was introduced way back in 1914 by Payne

and Brushart.^[20] Since then neurotization has been the subject of much investigation in animal models even if the clinical application of this technique has been infrequent in literature.^[21-26] These studies have concluded that neurotization occurs both by the reinnervation of the native motor end plates and the formation of new ectopic motor end plates.^[20] No ectopic end-plates form on the muscle fibre by a foreign nerve implantation in normally innervated muscles as there exists a state of nerve-muscle equilibrium.^[27] The potential to form ectopic end plates in the most atrophic of muscle fibres was demonstrated by Gutmann and Young.^[28] As atrophy proceeds, the proportion of old plates which may re-innervate falls rapidly because of compression of end plate protoplasm making it difficult for the arriving axoplasm to penetrate^[28] but when a nerve fibre makes direct contact with the sarcoplasm it produces a differentiation of that substance into the material characteristic of the end-plate.^[28] This is similar to what happens during development. End-plate remains with relatively little change on most of the fibres for a considerable period (at least 9 months) of atrophy, albeit with a reduced value because of atrophy around it.^[28] These authors feel that much of the reinnervation, by direct repair after a prolonged period of denervation, also takes place by production of a new end-plate by nerve fibres which 'escape' and make direct contact with sarcoplasm.^[28] In fact, in a recent study on an animal model of chronically denervated muscle, comparing neurotization with direct nerve repair in establishing innervation, it was established that neurotization was a more efficient method.^[29] The site of nerve implantation in a denervated muscle also has a bearing on the overall reinnervation, as it was demonstrated that more ectopic motor end plates were generated with nerve implantation further to the native motor endplate zone.^[20]

The next important question is how ectopic end plates will form if the muscle fibre has totally atrophied in long-standing palsy? It has been known for a while that denervated muscle fibres eventually atrophy severely, but they do not degenerate for years and are capable of getting reinnervated.^[30] After electron microscopic studies on denervated facial muscles, Conley *et al.*^[31] concluded that the facial muscles never totally disappear and muscle fibres could be noticed even 20-30 years after injury. Gulati stated that extended denervation did not abolish the capability of muscle regeneration as the precursor myosatellite cells retained their regenerative potential.^[32] This view was shared by Belal^[33] who observed that facial

muscle atrophy began as early as 1-month after paralysis, but these muscles seemed resistant to degeneration. It was postulated earlier that in long-standing facial palsy there exists a subliminal (muscular) system which is nonfunctional but has potential for rehabilitation, and that facial muscles survived denervation longer than any other skeletal muscle system in the body.^[31]

Erlacher concluded in 1915 that in suitable patients muscular neurotization could be recommended.^[21] Perhaps, Conley *et al.* were first to suggest that when peripheral facial nerve system was absent, nerve implantation into residual mimetic muscles was indicated.^[31] Not just as a plausible expectation for facial muscles, but this general need to determine if long denervated muscle regenerates permit functional recovery was expressed many times.^[29,32] Our results could be substantive clinical evidence of neurotization being a viable clinical option in chronically denervated facial muscles.

For neurotization to be effective the sprouting axons of the nerve graft must arborize under the skin flap to make contact with sarcolemma of the residual facial musculature, develop ectopic end plates to innervate them, and finally initiate muscle regeneration. The powerful muscle contractions seen in some of our results would validate this sequence of events. We did not feel the need to prove it further by any electrical or histopathological (or histochemical) studies because the same has been published many times in the last century and some of which have been quoted above. How far this process can continue cannot be completely answered by this small number of patients and a presumably short mean follow-up period of 20.75 months in the natural history of 'neurotization'. But, our results deserve attention and further investigation. Certainly, there will occur a plateauing of functional recovery after neurotization when a state of nerve — muscle equilibrium is attained.^[27] How the sprouting axons attain this equilibrium over a large surface area, across different muscle groups, is another enigma. To maximize this potential, the senior author made two important changes in patients 6-12 using two donor nerves for anastomosis and by not reversing the sural nerve graft. It was rightly assumed that the axons sprouting through the sural nerve branches would innervate en route muscles like orbicularis oris, labii superioris and zygomaticus group. That this strategy contributed to results is evident in Figures 3 and 4, but importantly the first sign of muscle contraction appeared at around 5-7 months

in these last 7 patients compared to 9-10 months for patients 3-5 (patient 1 being index patient and patient 2 received a short nerve graft). In patient 11, this 'en route' innervation also resulted in synkinesis with simultaneous closure of left upper eyelid with lip excursion. Although, synkinesis may be viewed as a 'complication' it is again a *sine qua non* of neurotization. In patients with >2 years follow-up, it was noticed that the incremental change in facial contraction had slowed. To take further the intent of speedier neurotization, the nerve graft end was placed 3 cm ahead of pre-tragal region in the last 3 patients to directly overlie the region of zygomaticus major and levator labii superioris. We are tempted to attribute our good-fair results to failure of sufficient axonal input to the sural nerve graft due to a single donor nerve anastomosis or a 'technically poor' anastomosis rather than question the principle of neurotization, even if the anastomosis was done by the senior author in all patients. There is also a possibility of fibrosis at the terminal end of the nerve graft, limiting the escape of axons, since there is no opportunity to freshen the cut end as the axons arrive.

The advantages of CFNEN procedure are that it considerably shortens the period of return of facial movement, and it is a straight forward, simple and single stage procedure. Needless to say this is the only method with the potential to restore function to a group of mimetic muscles for best symmetrical and synchronous movement. The most obvious disadvantage of CFNEN is that there are no means to determine the most strategic location to leave the free end of the nerve graft even if logically it is placed over the region of targeted muscle group. Return of innervation also spreads to deeper muscles as is evident by patient's ability to retain air in the mouth. Another disadvantage is that there is no opportunity to 'revisit' should the return of function be average. At the same time, we have not had a 100% failure with CFNEN in any of our patients. However, as a matter of abundant caution CFNEN may be considered as the first stage of CFNG + FFMT if the return of function is not adequate even after 18 months.

The placement of the nerve end under the skin flap has been rather arbitrary and empirical. It is hypothesised that the results may be improved further by also providing simultaneous innervation to orbicularis oculi, frontalis and lip depressors, and the authors are working on a surgical plan of using three nerve grafts as shown in Figure 5. This procedure has the potential for providing animation to many facial mimetic muscles. But, it is too

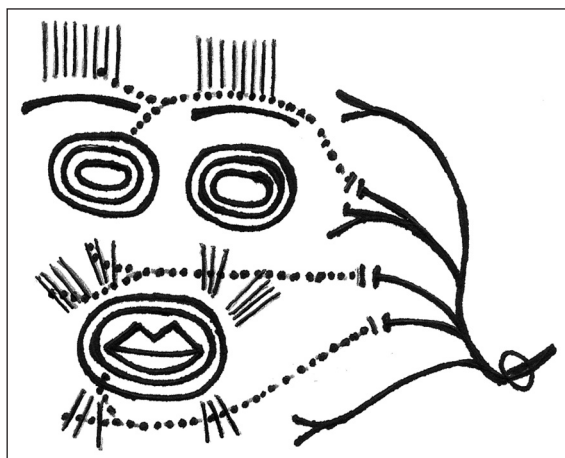


Figure 5: A schematic sketch of the surgical plan to employ three cross-face nerve grafts to harness the potential for complete restitution of all facial movements by neurotization

premature to even comment on these results. Another possibility, not explored as yet, and more applicable in bilateral patients, is to neurotize the atrophic facial muscles with ipsilateral masseteric or hypoglossal grafts.

This CFNEN procedure now needs to be validated by other workers. Our results are only clinical proof of the concept of neurotization of atrophic facial muscles taking place to provide functional recovery.

REFERENCES

- Kumar PA, Hassan KM. Cross-face nerve graft with free-muscle transfer for reanimation of the paralyzed face: A comparative study of the single-stage and two-stage procedures. *Plast Reconstr Surg* 2002;109:451-62.
- O'Brien BM, Franklin JD, Morrison WA. Cross-facial nerve grafts and microvascular free muscle transfer for long established facial palsy. *Br J Plast Surg* 1980;33:202-15.
- Manktelow RT. Free muscle transplantation for facial paralysis. *Clin Plast Surg* 1984;11:215-20.
- Terzis JK. Pectoralis minor: A unique muscle for correction of facial palsy. *Plast Reconstr Surg* 1989;83:767-76.
- Terzis JK, Noah ME. Analysis of 100 cases of free-muscle transplantation for facial paralysis. *Plast Reconstr Surg* 1997;99:1905-21.
- O'Brien BM, Pederson WC, Khazanchi RK, Morrison WA, MacLeod AM, Kumar V. Results of management of facial palsy with microvascular free-muscle transfer. *Plast Reconstr Surg* 1990;86:12-22.
- Terzis JK, Tzafetta K. The "babysitter" procedure: Minihypoglossal to facial nerve transfer and cross-facial nerve grafting. *Plast Reconstr Surg* 2009;123:865-76.
- Jiang H. Microvascular free abductor hallucis muscle transplantation for resuscitation of facial paralysis in one stage. *Zhonghua Wai Ke Za Zhi* 1992;30:420-2, 444.
- Koshima I, Moriguchi T, Soeda S, Hamanaka T, Tanaka H, Ohta S. Free rectus femoris muscle transfer for one-stage reconstruction of established facial paralysis. *Plast Reconstr Surg* 1994;94:421-30.
- Kumar PA. Cross-face reanimation of the paralyzed face, with a single stage microvascular gracilis transfer without nerve graft: A preliminary report. *Br J Plast Surg* 1995;48:83-8.
- Harii K, Asato H, Yoshimura K, Sugawara Y, Nakatsuka T, Ueda K. One-stage transfer of the latissimus dorsi muscle for reanimation of a paralyzed face: A new alternative. *Plast Reconstr Surg* 1998;102:941-51.
- Sajjadian A, Song AY, Khorsandi CA, Deleyiannis FW, VanSwearingen JM, Henkelmann TC, *et al.* One-stage reanimation of the paralyzed face using the rectus abdominis neurovascular free flap. *Plast Reconstr Surg* 2006;117:1553-9.
- Terzis JK, Olivares FS. Long-term outcomes of free-muscle transfer for smile restoration in adults. *Plast Reconstr Surg* 2009;123:877-88.
- Lifchez SD, Matloub HS, Gosain AK. Cortical adaptation to restoration of smiling after free muscle transfer innervated by the nerve to the masseter. *Plast Reconstr Surg* 2005;115:1472-9.
- Manktelow RT, Tomat LR, Zuker RM, Chang M. Smile reconstruction in adults with free muscle transfer innervated by the masseter motor nerve: Effectiveness and cerebral adaptation. *Plast Reconstr Surg* 2006;118:885-99.
- Faria JC, Scopel GP, Ferreira MC. Facial reanimation with masseteric nerve: Babysitter or permanent procedure? Preliminary results. *Ann Plast Surg* 2010;64:31-4.
- Frey M, Giovanoli P. The three-stage concept to optimize the results of microsurgical reanimation of the paralyzed face. *Clin Plast Surg* 2002;29:461-82.
- Thompson N. Treatment of facial paralysis by free skeletal by free skeletal muscle grafts. In: *Transactions of the Fifth International Congress of Plastic and Reconstructive Surgery*. Melbourne: Butterworth; 1971. p. 66.
- Terzis JK, Karypidis D. Outcomes of direct muscle neurotisation in adult facial paralysis. *J Plast Reconstr Aesthet Surg* 2011;64:174-84.
- Payne SH Jr, Brushart TM. Neurotization of the rat soleus muscle: A quantitative analysis of reinnervation. *J Hand Surg Am* 1997;22:640-3.
- Erlacher R. Direct and muscular neurotization of paralyzed muscle. *Am J Orthop Surg* 1915;13:22-32.
- Brunelli G. Direct neurotization of denervated muscles. New York: Raven Press; 1981. p. 523-27.
- Brunelli G. Direct neurotization of severely damaged muscles. *J Hand Surg Am* 1982;7:572-9.
- Brunelli G, Monini L. Direct muscular neurotization. *J Hand Surg Am* 1985;10:993-7.
- Brunelli GA, Brunelli GR. Direct muscle neurotization. *J Reconstr Microsurg* 1993;9:81-90.
- Mackinnon SE, McLean JA, Hunter GA. Direct muscle neurotization recovers gastrocnemius muscle function. *J Reconstr Microsurg* 1993;9:77-80.
- Aitken JT. Growth of nerve implants in voluntary muscle. *J Anat* 1950;84:38-49.
- Gutmann E, Young JZ. The re-innervation of muscle after various periods of atrophy. *J Anat* 1944;78:15-43.
- Swanson AN, Wolfe SW, Khazzam M, Feinberg J, Ehteshami J, Doty S. Comparison of neurotization versus nerve repair in an animal model of chronically denervated muscle. *J Hand Surg Am* 2008;33:1093-9.
- Sher JH. *Pathophysiology of denervation in facial neuromuscular motor unit*. St. Louis: Mosby; 1977. p. 40.
- Conley J, Hamaker RC, Donnenfeld H. Long-standing facial paralysis rehabilitation. *Laryngoscope* 1974;84:2155-62.

32. Gulati AK. Long-term retention of regenerative capability after denervation of skeletal muscle, and dependency of late differentiation on innervation. *Anat Rec* 1988;220:429-34.
33. Belal A. Postdenervation muscular changes in facial paralysis. *Eur Arch Otorhinolaryngol* 1994; [Suppl]:S31-6.

How to cite this article: Ahuja RB, Chatterjee P, Gupta R, Shrivastava P, Gupta GK. A new paradigm in facial reanimation for long-standing palsies?. *Indian J Plast Surg* 2015;48:30-7.

Source of Support: Nil, **Conflict of Interest:** None declared.

Announcement

	<h1>APSICON 2015</h1> <p>www.apsicon2015.com</p> <p>50th Annual Conference of the Association of Plastic Surgeons of India. Theme : Advocacy and Mass Education Dates : 28th to 31st December, 2015 Venue : The Renaissance, Mumbai, Hotel & Convention Centre.</p>		
Dr. Prabha Yadav Organizing Chairperson	Dr. Vinita Puri Organizing Secretary	Dr. Medha Bhawe Treasurer	Dr. Utpala Mulawkar Scientific Chairperson