

Original Article

Effects of limited access dressing in chronic wounds: A biochemical and histological study

Thittamaranahalli Muguregowda Honnegowda, Pramod Kumar¹, Padmanabha Udupa E G², Anurag Sharan, Rekha Singh³, Hemanth K. Prasad², Pragna Rao²

Departments of Plastic Surgery and Burns and ²Biochemistry, Kasturba Medical College, Manipal, ³Department of Pathology, Vydehi Institute of Medical Sciences and Research Center, Bengaluru, Karnataka, India, ¹King Abdulaziz Specialist Hospital, Sakaka, Al Jouf, Saudi Arabia

Address for correspondence: Dr. Pramod Kumar, King Abdul Aziz Hospital, Sakaka, Al-Jouf 42421, Saudi Arabia.
E-mail: pkumar86@hotmail.com

ABSTRACT

Background: Negative pressure wound therapy has emerged as an attractive treatment modality for the management and healing of chronic ulcers. Though numerous clinical studies are available, there is a lack of biochemical and histological studies evaluating the healing of chronic wounds.

Materials and Methods: In the present study, a total 60 patients were divided into two groups: Limited access dressing (LAD) group ($n = 30$) and conventional dressing group ($n = 30$). Various biochemical parameters such as hydroxyproline, total protein and antioxidants such as reduced glutathione (GSH), glutathione peroxidase (GPx), catalase (CAT) and oxidative biomarker malondialdehyde (MDA) are measured in the granulation tissue. Histologically amount of inflammatory infiltrate, angiogenesis, and collagen deposition are studied to assess wound healing.

Results: Patients treated with LAD have shown significant increase in the mean (\pm standard deviation) hydroxyproline (77.3 ± 30.1 vs. 32.3 ± 16.18 ; $P = 0.026$), total protein (13.89 ± 9.0 vs. 8.9 ± 4.59 ; $P = 0.004$), GSH (7.4 ± 1.91 vs. 5.1 ± 1.28 ; $P = 0.039$), GPx (122.3 ± 59.3 vs. 88.7 ± 34.11 ; $P = 0.030$), CAT (1.80 ± 1.14 vs. 0.9 ± 0.71 ; $P = 0.002$) and decrease in MDA (13.4 ± 5.5 vs. 8.6 ± 3.8 ; $P = 0.004$). Histological study showed comparatively fewer inflammatory cells, increased and well organised collagen bundles, and more angiogenesis in the LAD group when compared with that with conventional dressing after 10 days of treatment.

Conclusion: In the present study, we have found beneficial effect of newer intermittent negative pressure therapy in combination with moist environment (LAD) on chronic wound healing by increasing collagen deposition and angiogenesis; and reducing oxidative stress and inflammatory infiltrate.

KEY WORDS

Antioxidants (glutathione; glutathione peroxidase; catalase); chronic wound healing; hydroxyproline; limited access dressing; reactive oxygen species and oxidative stress biomarker (malondialdehyde); total protein

Access this article online	
Quick Response Code: 	Website: www.ijps.org
	DOI: 10.4103/0970-0358.155263

INTRODUCTION

Wound healing is a dynamic process involving biochemical and physiological phenomena that behave in a harmonious way for restoration of tissue.^[1] Wound is a disturbed state of tissue caused by physical, chemical, microbial and/

or immunological insults, and typically associated with anatomical and functional loss.^[2] Wound healing is an interaction of the complex cascade of cellular and biochemical actions leading to the restoration of structural and functional integrity with regain of strength of injured tissues. It involves continuous cell-cell interaction and cell matrix interactions that allow the process to proceed in different overlapping phases such as inflammation, wound contraction, reepithelialisation, remodeling and formation of granulation tissue with angiogenesis.^[3] Several factors delay the wound healing process such as bacterial infection, necrotic tissue, and interference with blood supply, lymphedema and diabetes mellitus. In general, if these factors could be altered by any agent, an increased healing rate could be achieved.^[4]

Oxidative stress is a challenge in which pro-oxidants predominate over antioxidants;^[5] it may be due to either increased production of reactive oxygen species (ROS) or decreased levels of antioxidants (enzymatic and non-enzymatic) or both. Oxidative stress, apart from affecting wound healing, is implicated in the aetiopathogenesis of variety of diseases like cardiovascular diseases, neurological diseases, malignancies, renal diseases, diabetes, inflammatory problems, skin diseases, etc.^[6] Oxidative stress is also thought to play a crucial role in the development of chronic wounds.^[7] Healing impairment by oxidative stress is characterised by increased free-radicals-mediated damage, delayed granulation tissue formation, and decreased collagen reorganisation leading to chronic wound.^[8]

Chronic wounds exhibit progressive edema, compromise of perfusion, and elevated levels of proteolytic enzymes and cytokines that inhibit granulation tissue formation and epithelialisation. Negative pressure wound therapy (NPWT) plays an important role in the process of wound healing by removing wound exudates rich in inhibitory cytokines, acute-phase proteins, proteolytic enzymes, various pathogens, and ROS.^[9,10]

The present study evaluates role of intermittent negative pressure using limited access dressing (LAD) (cycle of 30 min suction and 3½ h rest) on chronic wounds of more than 4 weeks duration by assessing various biochemical and histological parameters.

MATERIALS AND METHODS

Ethical approval and informed consent

This prospective randomised study was carried out in the Department of Plastic Surgery and Burns, Kasturba Medical College and Hospital, Manipal. Institutional Ethics committee reviewed and approved the study protocol. Informed consent was obtained from all patients or their next of kin (as applicable) before inclusion into the study.

Study design

Seventy-five patients with chronic wounds of more than 4 weeks were enrolled and assessed for eligibility. After examined inclusion (nondiabetic chronic ulcers) and exclusion criteria (patients with collagen disorders, leprosy patients, pregnant women, liver cirrhosis, HIV +ve status, smoking), 60 patients were randomised by generating tables of random numbers through www.random.org of whom 30 each were assigned to the LAD group ($n = 30$), conventional dressing group ($n = 30$) by simple randomisation [Figure 1]. In LAD group, mean patient age was 38.3 (± 14.56) years, range (12-60 years) and in conventional dressing group mean age is 36.8 (± 14.0) years, range (17-65 years) in both group mean wound size at the time of admittance was 15 cm² (range: 2-39 cm²). LAD group-patients were treated LAD with intermittent negative pressure. Conventional closed dressing group-patients were dressed daily using squeezed 5% povidone iodine gauze (which becomes good absorbent of soakage). Wounds were washed daily both LAD group and conventional group prior to dressing by 5% povidone iodine solution. Biopsies were taken on 0th and 10th day from both the groups.

Chemicals

Standard L-hydroxyproline, bovine serum albumin (BSA), standard glutathione (GSH), nicotinamide adeninedinucleotide phosphate (reduced form), glutathione reductase (type III, Baker's yeast), cumene hydrogen peroxide, catalase (CAT) standard, 1, 1, 3, 3-tetraethoxypropane, trichloroacetic acid (TCA) and thiobarbituric acid (TBA) (Merck, India), alcohol, haematoxylin and eosin stain (Sigma, Mo, USA).

Tissue preparation for biochemical parameters

Tissue preparation for estimation of hydroxyproline

The biopsies obtained were used for the analysis. The wet weight of the tissues was noted and dried at 60°C for 24 h to obtain a constant dry weight. The dried tissues were treated with 10 mL 6N HCl and kept at 110°C for 24 h.

The neutralised acid hydrolysates of the dry tissue were used for determination of the hydroxyproline content by the method of Neuman and Logan.^[11]

Tissue preparation for estimation of antioxidants and malondialdehyde

Tissue biopsies were immediately immersed in cold phosphate buffer, pH 7. It was blotted free of blood, then weighed on the electronic balance (Sartorius, Germany) and constant wet weight was recorded. The tissues were minced into small pieces and homogenised by tissue homogeniser (Remi Motor) in ice-cold 0.2 M phosphate buffer (pH 7.4). This released soluble protein leaving only membrane and nonvascular matters in a sedimental form. It was then centrifuged in cooling centrifuge (Remi CM 12 Plus) at 15,000 rpm for 20 min; final clear supernatant was then used to determine total protein, reduced GSH, glutathione peroxidase (GPx), CAT, malondialdehyde (MDA) assays. CAT activity was determined immediately after sample preparation. Protein concentration was determined according to Lowry *et al.*^[12] using purified BSA as standard.

Estimation of biochemical parameters

Hydroxyproline

The dried tissue was added to 10 mL 6N HCl and kept at 110°C for 24 h. The neutralised acid hydrolysate of the dry tissue was used for determination of hydroxyproline. The reaction mixture contains 0.05 M copper sulfate, 2.5N sodium hydroxide, 6% hydrogen peroxide, 3N sulfuric acid, 5% p-dimethylaminobenzaldehyde using L-hydroxyproline as standard. The absorbance was measured at 540 nm and expressed in µg/mg dry tissue weight.^[11]

Total protein

The total protein content of the wound tissue homogenate was determined according to the method of Lowry *et al.*^[12] The reaction mixture contains 0.5 mL tissue sample, 4 mL alkaline copper tartrate and 0.5 mL of Folin's reagent. The absorbance was measured at 540 nm and expressed in mg/g of wet tissue weight. Standards were treated similarly using BSA at concentrations of 0, 20, 40, 60, 80, and 100 µg/mL in 0.1 M phosphate buffer at pH 7.4.

Reduced glutathione

The reaction mixture prepared by adding 80 µL tissue supernatant, 0.9 ml of 0.2 M sodium phosphate buffer of pH 7.00 and 20 µL of 10 mM 5, 5'-dithiobis 2-nitrobenzoic acid (DTNB) solution. The yellow-colored substance

formed by the reaction of GSH and DTNB was measured at 412 nm. The results were expressed as GSH µmole/mg protein.^[13]

Glutathione peroxidase activity

For the determination of GPx activity in the granulation tissue, samples were prepared by the homogenizing tissue in 0.2 M phosphate buffer. Then, the homogenized samples were centrifuged at 8000 rpm for 20 min at 4°C. The resultant supernatant was again centrifuged at 15,000 rpm for 15 min at 4°C. The level of GPx activity was determined using the method of Pagile *et al.*^[14] The reaction mixture contained 0.55 mL of phosphate buffer with ethylenediaminetetraacetic acid (50 mM; pH 7.0), 0.1 mL of sodium azide (1 mM), 0.1 mL of GSH (1 mM), 0.1 mL of nicotinamide adenine dinucleotide phosphate (NADPH) (0.2 mM), and 0.1 mL glutathione reductase (2.5 units). To this mixture, 0.1 mL of the tissue sample was added, incubated for 5 min at room temperature and the reaction was started by adding 0.1 mL of 0.25 mM hydrogen peroxide. The optical density was measured at 340 nm for 5 min at 1 min interval. The enzymatic activity was measured as the micromoles of NADPH oxidized per minute per milligram protein.^[14]

Catalase assay

Catalase activity was measured by the method of Aebi.^[15] The reaction mixture contained 1 mL of tissue sample homogenate and reaction was started by the addition of 1.0 mL of freshly prepared 30 mM H₂O₂. The rate of decomposition of H₂O₂ was measured spectrophotometrically from changes in absorbance at 240 nm. Activity of CAT was expressed as IU/s/mg protein.

Malondialdehyde

The MDA levels of wound tissue homogenate were measured using TBA reactive substances (TBARS) according to the method of Ohkawa *et al.*^[16] To 0.1 mL of test sample, 1 mL of 10% TCA and 1 mL of 0.67% TBA were added and then heated in a boiling water bath at 100°C for 30 min. Mixture was cooled under tap water and centrifugation at 12000 rpm for 10 min, TBARS were determined by the absorbance at 535 nm and expressed as nmole/mg protein.^[16]

All readings were taken in Thermo Scientific ultraviolet (UV)-Visible Spectrophotometer (GENESYS 10 UV-Vis).

Tissue preparation for histology

Wound biopsies on 0th day and 10th were collected, fixed in 10% buffered formalin, dehydrated through

graded alcohol series (50%, 70%, 90% and 100%), cleared in xylene and embedded (Leica EG1150 H) in paraffin wax (m.p. 56°C). Serial sections of 5-µm thickness were cut using microtome (Leica RM2255), stained with haematoxylin-eosin^[17] and examined under light microscopy (Olympus PM20).

Statistical analysis

Statistical analysis was performed using Student's *t*-test using the SPSS software 15th version package. The data were expressed as mean ± standard deviation (SD). A *P* < 0.05 was considered to be significant. When appropriate, statistical uncertainty was expressed by the 95% confidence levels.

RESULTS

In total, 75 patients enrolled and assessed for eligibility, 60 patients were randomised into two groups - LAD group (*n* = 30) and conventional group (*n* = 30) [Figure 1]. Of these 60 patients under study, ten participants (five in each group), were lost to follow-up by 10th day before biopsies were taken. The results of hydroxyproline, total protein, GSH, GPx, CAT and MDA, in remaining 50 nonhealing chronic ulcer patients of both groups was presented in Table 1.

Biochemical parameters

Hydroxyproline

After 10 days treatment, LAD group has significantly high hydroxyproline level (mean ± SD = 77.3 ± 30.1 µg/mg dry tissue weight) than the conventional group (32.3 ± 16.18 µg/mg dry tissue weight) (*P* = 0.026).

Total protein

After 10 days treatment, LAD group has significantly high total protein level (mean ± SD = 13.89 ± 9.00 mg/g wet

tissue weight) than in conventional group (8.9 ± 4.59 mg/g wet tissue weight) (*P* = 0.004).

Reduced glutathione

After 10 days treatment, reduced GSH level in LAD group was significantly higher (mean ± SD = 7.4 ± 1.91 µmole/mg protein) when compared with that in conventional dressing group (5.1 ± 1.28 µ mole/mg protein) (*P* = 0.039).

Glutathione peroxidase

After 10 days treatment, LAD group had high GPx level (mean ± SD = 122.3 ± 59.3 µmol/min/mg protein) than that of conventional group (88.7 ± 34.11 µMoles NADPH oxidised/min/mg protein)(*P* = 0.030).

Catalase

After 10 days treatment, LAD group had high CAT level (mean ± SD = 1.80 ± 1.14 IU/s/mg protein) than that of conventional group (0.9 ± 0.71 IU/s/mg protein) (*P* = 0.002).

Malondialdehyde

After 10 days treatment, MDA levels was significantly reduced in LAD group, (mean ± SD = 13.4 ± 5.5 nmole/mg protein) compared with conventional dressing group (8.6 ± 3.8 nmole/mg protein) (*P* = 0.004).

Histological analysis

Slides were stained with haematoxylin and eosin, and evaluated by an observer blinded to the experimental protocol under light microscopy. On 0th day, both groups showed a necrotic tissue with increase cellular infiltration [Figures 2a and 3a]. On 10th day, LAD group showed an increase in extracellular matrix (ECM) deposition, well-organised collagen bundles, decrease in cellular infiltration and increased angiogenesis

Table 1: Levels of hydroxyproline, total protein, GSH, GPx, catalase, MDA in granulation tissue of chronic ulcer in LAD group and conventional dressing group

Parameters	LAD group (<i>n</i> = 25) (mean ± SD)			Conventional dressing group (<i>n</i> = 25) (mean ± SD)			<i>P</i>
	0 th day	10 th day	0 th day-10 th day	0 th day	10 th day	0 th day-10 th day	
Hydroxyproline (µg/mg of dry weight of tissue)	62.5±9.39	139.8±25.3	77.3±30.1	69.7±11.21	102±16.3	32.3±16.18	0.026
Total protein (mg/g of wet weight tissue)	11.10±2.84	24.99±6.46	13.89±9.0	13.2±2.73	22.1±4.43	8.9±4.59	0.004
GSH (µmole/mg protein)	15.1±4.1	22.5±3.1	7.4±1.91	15.8±3.41	20.9±4.01	5.1±1.28	0.039
GPx (µmoles NADPH oxidized/min/mg protein)	265.5±59.2	387.8±71.9	122.3±59.3	260.1±78.9	348.8±84.9	88.7±34.11	0.030
CAT (IU/s/mg protein)	3.23±1.7	5.03±2.2	1.80±1.14	3.4±1.70	4.3±1.73	0.9±0.71	0.002
MDA (nmole/mg protein)	19.6±5.9	6.2±2.34	13.4±5.5	18.6±5.5	10.0±4.03	8.6±3.8	0.004

SD: Standard deviation, GSH: Reduced glutathione, GPx: Glutathione peroxidase, CAT: Catalase, MDA: Malondialdehyde, LAD: Limited access dressing, NADPH: Nicotinamide adenine dinucleotide phosphate

[Figure 2b] than that of the conventional dressing group [Figure 3b].

DISCUSSION

Chronic wounds are believed to be caused by impaired blood flow leading to impaired oxygen supply, decreased collagen and fibronectin synthesis due to protein malnutrition, impaired local immune cell defenses and decreased anabolic activity with decreased levels of growth factors.^[18] In response to tissue loss, fibroblasts proliferate and migrate into the ECM.^[19] Enhanced healing activity has been attributed to increased collagen deposition by fibroblasts and increased angiogenesis in granulation tissue.^[20] Various studies have shown that NPWT improves wound healing by inducing fibroblast and/or endothelial cell proliferation, and by increasing the amount of granulation tissue formation.^[21-23]

Collagen plays a central role in the healing of wounds, and it is a principal component of connective tissue that provides a structural framework for the regenerating tissue and tensile strength. The stimulation of angiogenesis and epithelial cell proliferation is important for wound healing.^[24] In the present study after 10 days therapy, in LAD group there was significant increase in mean hydroxyproline (\pm SD) content (LAD vs. conventional = 77.3 ± 30.1 vs. 32.3 ± 16.18 μ g/mg of dry weight of tissue; $P = 0.026$) and total protein level (LAD vs. conventional = 13.89 ± 9.00 vs. 8.9 ± 4.59 mg/g of wet weight tissue; $P = 0.004$).

Antioxidants such as GPx, CAT and GSH hasten the process of wound healing by destroying the free radicals.^[25,26] After 10 days of treatment, estimation of antioxidants

in granulation tissues revealed mean GSH (\pm SD) (LAD vs. conventional = 7.4 ± 1.91 vs. 5.1 ± 1.28 μ mole/mg protein; $P = 0.004$), GPx (\pm SD) (LAD vs. conventional = 122.3 ± 59.3 vs. 88.7 ± 34.11 μ moles NADPH oxidised/min/mg protein; $P = 0.030$), and CAT (\pm SD) (LAD vs. conventional = 1.80 ± 1.14 vs. 0.9 ± 0.71 IU/s/mg protein; $P = 0.002$), were significantly higher in LAD group than in conventional group.

Free radical damage and ROS-induced oxidative stress in response to cutaneous injury impedes the healing process by causing damage to cellular membranes, DNA, proteins, and lipids.^[27] MDA is biomarker for lipid peroxidation in the chronic wound. After 10 days of treatment, mean MDA (\pm SD) (LAD vs. conventional = 13.4 ± 5.5 vs. 8.6 ± 3.8 nmole/mg protein; $P = 0.004$), significant reduction was seen in LAD group than the conventional dressing group [Table 1]. There are no similar studies available in the literature specifically stating about the reduction of the reactive oxygen-induced oxidative stress through NPWT.

Histological analysis showed that a decreased inflammatory infiltrate, increase in angiogenesis as well as collagen deposition in LAD group [Figure 2b] when compared to that of the conventional group [Figure 3b] indicating better granulation and improved wound healing process.

Povidone iodine solution is an effective antiseptic and clinically has been used widely for considerable long period. Povidone iodine solution may be toxic to tissues in higher concentration^[28] however numerous randomised controlled trial studies on

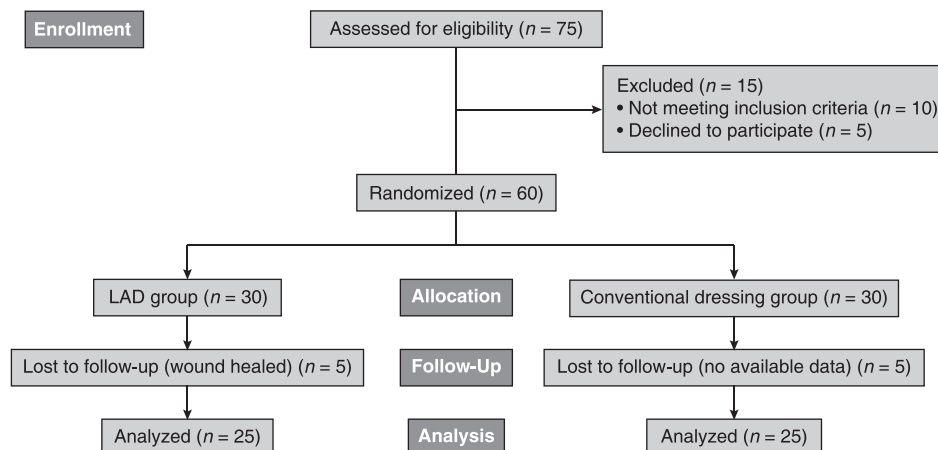


Figure 1: Consort flow chart

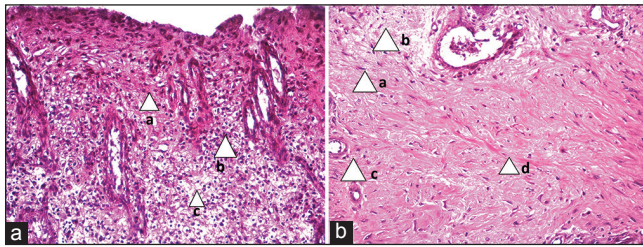


Figure 2: Histopathology of 0 and 10th days old granulation tissue in LAD group. (A) PreLAD (0th day) (arrow) numerous neutrophils infiltration, (a) minimum number of fibroblasts, (b) fewer collagen fibers. (c) (Photograph with Olympus PM20 photomicroscope, ×20). (B) PostLAD (10th day) (arrow) maximum number of fibroblasts, (a) fewer inflammatory cells, (b) more proliferating blood capillaries (neovascularisation), (c) collagen bundles organized well between the cells. (d) (Photograph with Olympus PM20 photomicroscope, ×20 magnification)

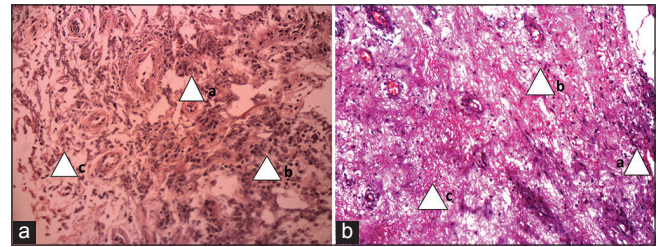


Figure 3: Histopathology of 0 and 10th days old granulation tissue in conventional group. (a) Preconventional (0th day) - (arrow) numerous neutrophils infiltration, (a) minimum number of fibroblasts, (b) poor collagen fibers. (c) (Photograph with Olympus PM20 photomicroscope, ×20). (b) Postconventional (10th day) (arrow) numerous neutrophils infiltration, (a) poorly developed matrix minimum number of fibroblasts, (b) poor collagen bundles. (c) (Photograph with Olympus PM20 photomicroscope, ×20)

chronic wounds including burn wound, concluded that quicker wound healing and a reduction of bacteria with povidone iodine-impregnated gauze dressing treated wounds.^[29-31] In our study in both group, wounds were daily washed with 5% povidone iodine solution and conventional group dressing was done with 5% povidone iodine soaked gauze after squeezing it to make it good absorbent of wound soakage by capillary action.

CONCLUSION

Biochemical and histological results showed that LAD group (intermittent NPWT in moist environment) has, significant reduction of oxidative stress (MDA), increased antioxidants levels (GSH, GPx and CAT), ground substance of the ECM (hydroxyproline and total protein), decreased inflammatory cells, increased angiogenesis and collagen deposition than the conventional dressing group. It was concluded that LAD exerts better beneficial effects on wound healing.

REFERENCES

1. Bowler PG. Wound pathophysiology, infection and therapeutic options. *Ann Med* 2002;34:419-27.
2. Hunt TK, Hopf H, Hussain Z. Physiology of wound healing. *Adv Skin Wound Care* 2000;13:6-11.
3. Martin P. Wound healing – aiming for perfect skin regeneration. *Science* 1997;276:75-81.
4. Chithra P, Sajithlal GB, Chandrakasan G. Influence of *Aloe vera* on collagen turnover in healing of dermal wounds in rats. *Indian J Exp Biol* 1998;36:896-901.
5. Venkatesh P, Satpal G, Verma L, Kumar TH, Garg S. Antioxidants: Basis concepts in relation to the eye. *Indian J Clin Biochem* 2001;16:9-14.
6. Irshad M, Chaudhuri PS. Oxidant-antioxidant system: Role and significance in human body. *Indian J Exp Biol* 2002;40:1233-9.
7. Walshe C. Living with a venous leg ulcer: A descriptive study of patients' experiences. *J Adv Nurs* 1995;22:1092-100.

8. Guo S, Dipietro LA. Factors affecting wound healing. *J Dent Res* 2010;89:219-29.
9. Joseph E, Hamori CA, Bergman S, Roaf E, Swann NF, Anastasi GW. A prospective randomized trial of vacuum-assisted closure versus standard therapy of chronic non-healing wounds. *Wounds* 2000;12:60-7.
10. Kumar P. Exploiting potency of negative pressure in wound dressing using limited access dressing and suction-assisted dressing. *Indian J Plast Surg* 2012;45:302-15.
11. Neuman RE, Logan MA. The determination of collagen and elastin in tissues. *J Biol Chem* 1950;186:549-56.
12. Lowry OH, Rosebrough NJ, Farr AL, Randall RJ. Protein measurement with the Folin phenol reagent. *J Biol Chem* 1951;193:265-75.
13. Beutler E, Duron O, Kelly BM. Improved method for the determination of blood glutathione. *J Lab Clin Med* 1963;61:882-8.
14. Rotruck JT, Pope AL, Ganther HE, Swanson AB, Hafeman DG, Hoekstra WG. Selenium: Biochemical role as a component of glutathione peroxidase. *Science* 1973;179:588-90.
15. Aebi H. Catalase *in vitro*. *Methods Enzymol* 1984;105:121-6.
16. Ohkawa H, Ohishi N, Yagi K. Assay for lipid peroxides in animal tissues by thiobarbituric acid reaction. *Anal Biochem* 1979;95:351-8.
17. Bancroft JD, Gamble M. *Theory and Practice of Histological Techniques*. 6th ed. China: Churchill Livingstone Elsevier; 2008. p. 123-30.
18. Davidson JM, Klagsbrun M, Hill KE, Buckley A, Sullivan R, Brewer PS, *et al.* Accelerated wound repair, cell proliferation, and collagen accumulation are produced by a cartilage-derived growth factor. *J Cell Biol* 1985;100:1219-27.
19. Clark RA. Regulation of fibroplasia in cutaneous wound repair. *Am J Med Sci* 1993;306:42-8.
20. Shukla A, Rasik AM, Dhawan BN. Asiaticoside-induced elevation of antioxidant levels in healing wounds. *Phytother Res* 1999;13:50-4.
21. Kumar P. Limited access dressing. *Wounds* 2008;20:49-59.
22. Mouës CM, van den Bemd GJ, Meering WJ, Hovius SE. An economic evaluation of the use of TNP on full-thickness wounds. *J Wound Care* 2005;14:224-7.
23. Armstrong DG, Lavery LA, Boulton AJ. Negative pressure wound therapy via vacuum-assisted closure following partial foot amputation: What is the role of wound chronicity? *Int Wound J* 2007;4:79-86.
24. Buntrock P, Jentzsch KD, Heder G. Stimulation of wound healing, using brain extract with fibroblast growth factor (FGF) activity. II. Histological and morphometric examination of cells and capillaries. *Exp Pathol* 1982;21:62-7.

25. Adamson B, Schwarz D, Klugston P, Gilmont R, Perry L, Fisher J, *et al.* Delayed repair: The role of glutathione in a rat incisional wound model. *J Surg Res* 1996;62:159-64.
26. Halliwell B, Grootveld M, Gutteridge JM. Methods for the measurement of hydroxyl radicals in biomedical systems: Deoxyribose degradation and aromatic hydroxylation. *Methods Biochem Anal* 1988;33:59-90.
27. Gupta A, Singh RL, Raghubir R. Antioxidant status during cutaneous wound healing in immunocompromised rats. *Mol Cell Biochem* 2002;241:1-7.
28. Balin AK, Pratt L. Dilute povidone-iodine solutions inhibit human skin fibroblast growth. *Dermatol Surg* 2002;28:210-4.
29. Laudanska H, Gustavson B. In-patient treatment of chronic varicose venous ulcers. A randomized trial of cadexomer iodine versus standard dressings. *J Int Med Res* 1988; 16:428-35.
30. Homann HH, Rosbach O, Moll W, Vogt PM, Germann G, Hopp M, *et al.* A liposome hydrogel with polyvinyl-pyrrolidone iodine in the local treatment of partial-thickness burn wounds. *Ann Plast Surg* 2007;59:423-7.
31. Sinha R, Agarwal RK, Agarwal M. Povidone iodine plus neosporin in superficial burns – a continuing study. *Burns* 1997;23:626-8.

How to cite this article: Honnegowda TM, Kumar P, Padmanabha Udupa EG, Sharan A, Singh R, Prasad HK, Rao P. Effects of limited access dressing in chronic wounds: A biochemical and histological study. *Indian J Plast Surg* 2015;48:22-8.

Source of Support: Nil, **Conflict of Interest:** None declared.