

Safe and versatile variation of the surgical technique for treating the underdeveloped antihelix in otoplasty

Sir,

Ear deformities, especially prominent ears, are relatively common; their incidence is approximately 5% in the Caucasian population. This condition is related to an autosomal dominant gene and is usually caused by a combination of two defects: Conchal cartilage hypertrophy and a defect in the development of antihelix fold. Several surgical techniques and tactics have been described for the correction of these two major defects. For the underdevelopment of antihelix, we have used a combination technique: Mustardé with sutures, associated with a variation of the usual scoring technique (described for Stenström) that uses the principle of Gibson and Davis, to minimize the trauma and complications.^[1-4]

Our technical variation to create a new antihelix fold was

performed in an anterior approach. First, we marked the limits of the new antihelix fold with a needle and ink. After a small incision of 5 mm over the crus superior of antihelix [Figure 1a], just behind the helix margin, we dissected the skin of the cartilage with iris scissors [Figure 1b]. Through the space formed, we proceeded using our technique variation: With a 15° Beaver blade (Beaver-Visitec, Inc., Waltham, MA, USA) sufficiently small to be introduced in this little incision, we made three parallel incisions in the anterior perichondrium [Figure 1c and d], replacing the scrapes used in usual techniques. These incisions were made with a reverse movement after introducing the blade in the space formed. Thereafter, we closed the small incision with a simple point with 6-0 Mononylon suture (Ethicon, Inc., Somerville, NJ, USA). Finally, we associated the technique with Mustardé points with 4-0 Mononylon suture (Ethicon, Inc., Somerville, NJ, USA) on the posterior surface of the cartilage.

The wounds were closed with a bandage for 7 days. Follow-up appointments were made at the end of the 1st week, 1 month, 3 months and 6 months. We analyzed the presence of edema, hematoma or epidermolysis. We used this tactic variation in six patients and found that they all had good results in the treatment of underdeveloped antihelix and no recurrence of the defect within 6 months postoperatively, nor any case of

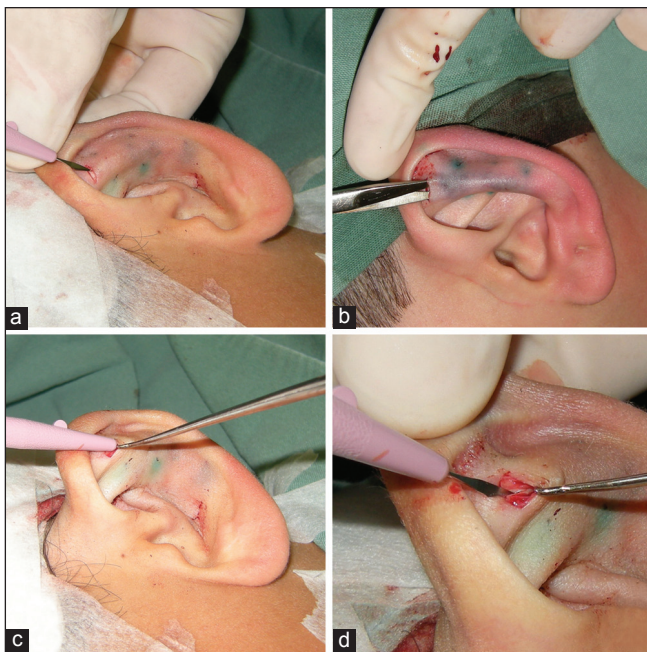


Figure 1: (a) 5 mm incision; (b) dissection with iris scissors; (c) Beaver blade introduction to make three parallel incisions in the perichondrium; (d) detail in the finish of incision

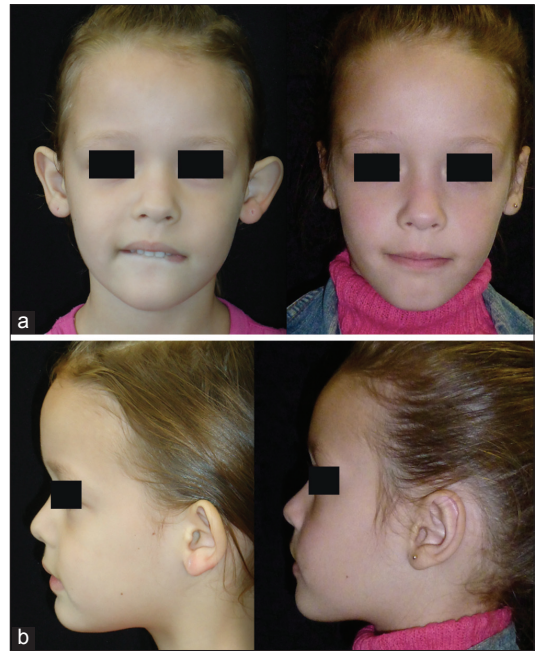

Figure 2: (a) Anterior pre-operative and post-operative evaluation at 6 months respectively; (b) lateral pre-operative and post-operative evaluation at 6 months respectively

epidermolysis and post-operative hematoma (a common complication in the scoring technique). The scar on the anterior antihelix became almost undetectable in all patients in the postoperative evaluation at 6 months [Figure 2a and b].

Thus in our hands the variation in surgical technique used in this study for the treatment of antihelix defect in patients with prominent ears has proved to be safe and with good short-term results. The Beaver blade (Beaver-Visitec, Inc., Waltham, MA, USA) is necessary as it is of small size and can be effectively used to make the perichondrial incisions. Kaul and Patil have used other instruments with a similar technique for keeping the post operative scar to minimum and reducing per operative trauma.^[5] We will continue to perform this technique in more patients and will follow the cases long-term to further show more results.

**Antonio Carlos Schilling Minuzzi Filho^{1,2},
Pedro Bins Ely^{1,2}, Marcos Ricardo de Oliveira
Jaeger^{1,2}, Jefferson André Pires^{3,4},
Darwin Lizot Rech^{1,2}**

¹Federal University of Health Sciences of Porto Alegre,
²Brazilian Society of Plastic Surgery, ³Brazilian College of
Surgeons, ⁴Academic League of Plastic Surgery of Federal
University of Pelotas, Brazil

Address for correspondence:

Dr. Antonio Carlos Schilling Minuzzi Filho,
Sarmento Leite, 245, Porto Alegre, RS, Brazil.
E-mail: acminuzzi@live.com

REFERENCES

1. Mustardé JC. The treatment of prominent ears by buried mattress sutures: A ten-year survey. *Plast Reconstr Surg* 1967;39:382-6.
2. Stenstroem SJ. A "natural" technique for correction of congenitally prominent ears. *Plast Reconstr Surg* 1963;32:509-18.
3. Gibson T, Davis W. The distortion of autogenous cartilage grafts: Its cause and prevention. *Br J Plast Surg* 1958;10:257.
4. Thorne CH, Wilkes G. Ear deformities, otoplasty, and ear reconstruction. *Plast Reconstr Surg* 2012;129:701e-16.
5. Koul AR, Patil RK. An effective technique of helical cartilage scoring for correction of prominent ear deformity. *Indian J Plast Surg* 2011;44:505-8.

Access this article online	
Quick Response Code: 	Website: www.ijps.org
	DOI: 10.4103/0970-0358.122031