

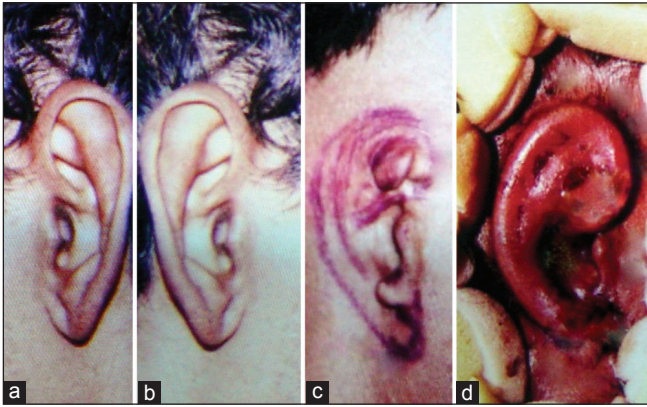
## Letters to Editor

---

### **Use of 'reverse prints', 'mirror image' or 'horizontal flip' in ear reconstruction**

Sir,

The field of plastic surgery is amongst the most photographed of all medical sciences allowing both patient and peers to appreciate the subtle changes



**Figure 1:** (a) Normal left ear, (b) 'reverse print' or 'horizontal flip' of the normal left ear, which in fact is the final appearance that needs to be achieved, (c) the deformed right ear with the ear landmarks and (d) the first stage of ear reconstruction using the costal cartilage

brought about by the surgeon's knife. Digital photography and computer imaging has ushered in a new revolution and is slowly replacing the classic photography. Total ear reconstruction in burn patients poses a technical challenge in that the reconstructed ear should resemble a normal human ear in addition to being similar to the contra lateral ear. Intraoperatively, the surgeon often looks to the contra lateral normal ear, reversing the image in his mind, to visualize the final appearance that he should attain while reconstructing the deformed ear. We have used a simple technique of reverse printing to aid us during surgery. The normal contra lateral ear is first photographed and a 'negative' film is developed. During printing, the 'negative' film is reversed so that the 'positive' print on paper appears as that of the ear to be reconstructed. This photograph is enlarged and used intraoperatively to guide the surgeon. With the advent of digital photography and special software, this procedure has been simplified by obtaining a 'mirror image' or 'horizontal flip' of the normal ear on a computer and then printing a magnified image on paper. During the operative procedure, the surgeon can easily view the final appearance that he should achieve and the presence of the photograph helps in creating the finer details that would otherwise have been difficult to imagine by looking at the contra lateral normal ear. Figure 1 shows the reconstruction of the right ear using the 'reverse print' of the contra-lateral normal left ear in a burn patient. Though the picture shown is only that of the ear, by taking the full profile picture of the face on the normal ear side and 'horizontally flipping' it, it is possible to review the correct site, size, direction and angle for the new ear reconstruction. Besides its use in all forms of ear reconstruction, the 'reverse prints', 'mirror images'

or horizontal flips are also useful while doing final 'touch ups' on the reconstructed ear. We believe that this simple method can be an additional tool helping the novice as well as the experienced plastic surgeon achieve their goals in ear reconstruction.

### Alexander George, Reena Alexander<sup>1</sup>

Department of Plastic Surgery, Kims Hospital,  
<sup>1</sup>Department of Physiology, Amrita Institute of Medical  
 Sciences, Cochin, Kerala, India

#### Address for correspondence:

Dr. Alexander George, Kims Hospital,  
 Cochin, Kerala, India.  
 E-mail: okalex@mailcity.com

#### Access this article online

##### Quick Response Code:



##### Website:

[www.ijps.org](http://www.ijps.org)

##### DOI:

10.4103/0970-0358.122030