

## Original Article

# Reconstruction of post-traumatic long bone defect with vascularised free fibula: A series of 28 cases

Gurdayal Singh Kalra, Pradeep Goel, Pradeep Kumar Singh

Department of Burn and Plastic Surgery, Sawai Man Singh Medical College, Jaipur, Rajasthan, India

**Address for correspondence:** Dr. Pradeep Kumar Singh, Flat 303, Sriram Apartment, Mangal Marg, Bapu Nagar, Jaipur - 302 015, Rajasthan, India. [drmatch28@gmail.com](mailto:drmatch28@gmail.com)

### ABSTRACT

**Introduction:** The severe long bone defects usually follow high-energy trauma and are often associated with a significant soft-tissue injury. The goal of management of these open long bone defects is to provide stable fixation with maintenance of limb length and soft-tissue coverage. The purpose of this article is to present the clinic-radiological outcome, complications and treatment of post-traumatic long bone defect with vascularised fibula transfer. **Materials and Methods:** Retrospective records of 28 patients were analysed who presented with post-traumatic long bone defects and in whom reconstruction with vascularised free fibula was done. Demographic data were recorded and clinical and radiological assessment was done. **Results:** Out of 28 patients in whom vascularised free fibula transfer was carried out three flaps were lost while non-union occur in three patients. Three patients developed a stress fracture of transferred free fibula in the post-operative period. Few of the patients experienced some problems in the donor leg; however, all of them improved in subsequent follow-up. **Discussion:** It is clearly evident from this study that timing of surgery plays an important role in the micro-vascular reconstruction in trauma cases. All the complication like flap loss, non-union or delayed union occur in patients in whom reconstruction was delayed. **Conclusion:** The free vascularised fibula graft is a viable method for the reconstruction of skeletal defects of more than 6 cm, especially in cases of scarred and avascular recipient sites or in patients with combined bone and soft-tissue defects. Results are best when the reconstruction is done within 1 week of trauma.

### KEY WORDS

Long bone defect; post-traumatic; vascularised free fibula

### INTRODUCTION

Following high velocity limb trauma the defects in the long bone are usually associated with appreciable soft tissue losses. These open

long bone injuries always require multidisciplinary managements to reconstruct the composite defects of bone and soft-tissue.<sup>[1]</sup> There are various methods of reconstruction of post-traumatic long bone defects like by transferring tissues from a distant origin (pedicled or free flaps) or by inducing bone regeneration through callus distraction.<sup>[2]</sup> Vascularised bone graft appears to be most applicable to clinical situations involving large composite bony defects.<sup>[3,4]</sup> Their greatest advantage is in situations, where the soft-tissue beds are scarred or ischaemic, which might delay or prevent conventional bone graft incorporation and subsequent healing.

#### Access this article online

Quick Response Code:



Website:

[www.ijps.org](http://www.ijps.org)

DOI:

10.4103/0970-0358.122013

The structural characteristics of the fibula, namely, straight shape, sufficient length, mechanical strength and limited donor-site morbidity, make it more suitable for reconstructing long bone defects in the limbs.<sup>[5-7]</sup> In 1975, Taylor *et al.*<sup>[8]</sup> described two cases in which vascularised free fibula had been used to treat severe fractures of the tibia and fibula with bone defect. Gilbert (1979) and Tamai *et al.* (1980) refined the method of removing the fibula; reduction of the time of the operation to less than an hour made the technique much more applicable.<sup>[9,10]</sup> Since then, the free vascularised fibular graft has been widely indicated in the reconstruction of long bone defect after trauma, wide resection of the malignant tumour, chronic osteomyelitis, avascular necrosis of the femoral head or congenital pseudarthrosis of the tibia.<sup>[11]</sup>

Furthermore, the vascularised free fibula has been expanded to an osteocutaneous flap by including a cutaneous flap on the lateral part of the lower leg by Chen and Yan (1983).<sup>[12,13]</sup> The development of the free vascularised osteocutaneous fibular flap seems to lie in the feasibility of one-stage reconstruction for bone and soft-tissue defects in traumatic extremities.<sup>[14]</sup> The vascularised free fibula provides an anatomically suitable substrate for bridging large bone gaps in the upper extremity.

The purpose of this article is to present the clinic-radiological outcome, complications and treatment of post-traumatic long bone defect with vascularised fibula transfer.

## MATERIALS AND METHODS

### Study population

Retrospective records were retrieved from the Department of Burn and Plastic Surgery, SMS Medical College, of all those patients who presented with post-traumatic long bone defect from January 2009 to September 2012.

Demographic data of age, sex, mode of trauma, localisation of fracture, involvement of bone side and size and defect with timing of surgery were recorded.

A total of 40 patients data were retrieved, out of which 36 were fit to our criteria and among these eight lost to follow-up, so only 28 patients records were analysed for this study. In all of these patients, mode of injury was road traffic accident.

## Assessment

### Clinical assessment

All the flaps were monitored clinically in the post-operative period as per the standard protocol (Kruse *et al.*).<sup>[15]</sup> Methods of fixation were also analysed.

In regular follow-up free fibula donor site morbidity was checked in terms of weakness of foot evertors and great toe flexors, graft take if osteocutaneous fibula was taken and diffuse leg and ankle joint discomfort.

### Radiological assessment

Pre-operative biplanar radiographs were taken to know the status of the bone and assessment of the bone defect. Arteriography of the involved extremity was done in every patient for evaluation of the vascular status of that extremity.

Patients were examined regularly with plain radiograph to determine the post-operative reduction, evidence of bony union, hypertrophy of the transferred fibula and late complications as a stress fracture.

Bony union was said to have occurred when radiological bony union between the ends of the fibula and the recipient bone in two planes. Union of the bone proximally and distally was assessed according to Huso *et al.*<sup>[16]</sup> with bone union defined as uninterrupted external bony borders between the fibular graft and recipient bone in addition to obscured or absent osteotomy line at both junctions. Radiographic evaluation was done at regular periods after 3 week, 3 month and 6 month of operation.

### Operative technique

Those patients who presented with infected and extensive soft-tissue defect; cleaning of the wound was done with repeated dressings and the area was initially skin grafted. After all the wounds have healed and subsidence of inflammation, the free vascularised fibular osteocutaneous flap was done [Figure 1].

The contra lateral fibula was harvested with a lateral approach, with the patient in dorsal decubitus under pneumatic tourniquet as per the standard guidelines described by Taylor *et al.*<sup>[8]</sup> and Chen and Yan.<sup>[12]</sup> The transferred fibula was inlayed in the medullary canal after partial stripping of the periosteum in cases of defects of the femur and tibia. Trascortical screws or Kirschner (K)-wires at graft host junction were added along with the external fixator to provide additional strength. In upper extremity defects,

fibula was fixed with plates and screws or screws only. The skin flap was sutured to the wound edge in open injuries when osteocutaneous flap was used for reconstruction.

The peroneal artery and its venae comitantes were anastomosed to the donor vessels. The mean ischaemic time of the grafts was 1.5 h (range 1-2.5). The donor site of the fibular osteocutaneous flap was covered with a split thickness skin graft. In post-operative period intravenous antibiotics were used for 7 days. Thromboembolism prophylaxis included: dextran-40 with 5000 IU heparin for the first 2 days (dosage 0.8-1.0 ml/kg/h) and then tablet clopidogrel 2-3 mg/kg and tablet aspirin 2-3 mg/kg mg daily for 1 month.

Once all the wounds have healed usually at 3 weeks, external fixator was removed if present in cases of compound long bone defects and immobilisation cast was given for 3 months. After 3 months, patients were called for follow-up and check X-rays were done for evaluation of signs of healing. If signs of healing were present then walking cast was given in cases of lower limb defects and mobilisation was started.

## RESULTS

A total 28 vascularised free fibula flaps were performed in this time period. All the cases were performed by two experienced surgeons. All the patients were followed-up from 6 months to 2 years. In 24 patients, free osteocutaneous fibula flap was used for reconstruction while in four patients free vascularised fibula flap was done [Table 1].

Post-operative circulatory disturbances developed in 10 cases within 6 h. Out of these, two patients had arterial thrombosis while eight patients had venous thrombosis. Reanastomosis after thrombectomy was carried out in all of these cases and while doing so seven flaps could be salvaged. However, three flaps could not be salvaged as they developed repeated thrombosis after reanastomosis. Out of these 10 patients who developed circulatory disturbances, nine patients were operated between 1<sup>st</sup> and 6<sup>th</sup> weeks of trauma while one patient was operated after 6 weeks of trauma [Table 2]. All these three patients had large tibial defect (> 12 cm) with soft-tissue defect. In all these patients, below knee amputation was done as no other option was available for reconstruction.

Evaluation of the immediately post-operative radiographs for adequacy of reduction revealed good reduction in

24 cases and poor reduction in four cases, which was corrected subsequently [Table 3 and Figure 3]. Uneventful (Normal) healing occur in 17 cases with a mean healing

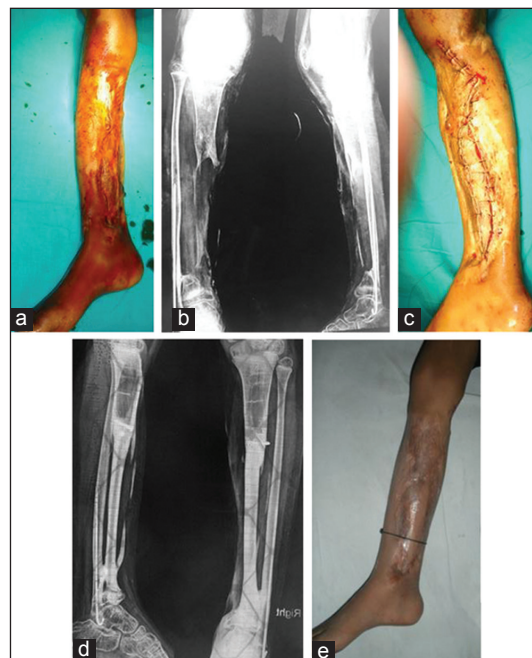


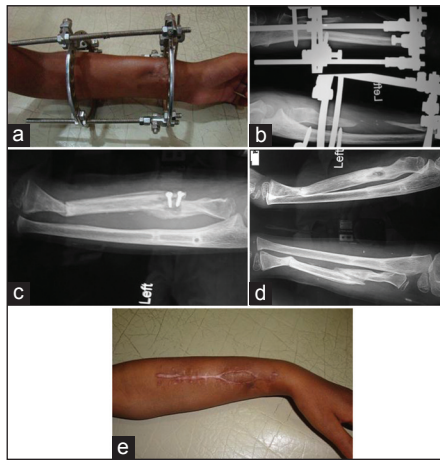
Figure 1: A 12-year-old boy with a compound fracture right leg. (a) Pre-operative photo, (b) Pre-operative X-ray, (c) Immediate post-operative, (d) 6 months post-operative, (e) 6 months post-operative X-ray showing hypertrophy of fibula

Table 1: Demographic data of all patients

Demographic data	Number/Range
Mean age	25 years (range 2-60 years)
Gender	
Male	24
Female	4
Localisation	
Humerus	2
Radius [Figure 2]	1
Femur	2
Tibia	23
Side	
Right	10
Left	18
Mean defect length	12 cm (range 6-18 cm)
Timing of surgery	
<1 week	2
1-6 week	20
>6 weeks	6

Table 2: Outcome of the flaps

Timing of surgery	No. of patients	Re-exploration (no.) (%)	Flap failed	Cause of failure
<1 week	2	—	—	—
1-6 weeks	20	9 (45)	2	Venous thrombosis
>6 weeks	6	1 (16)	1	Venous thrombosis



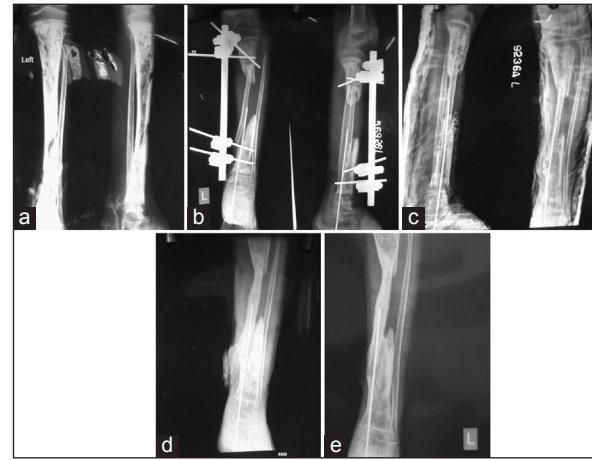**Figure 2:** (a) A 16-year-old girl with post-traumatic defect left radius, (b) pre-operative X-ray, (c) 4 months post-operative, patient developed infection at the screw site, which were subsequently removed, (d and e) 6 months post-operative photos

time of 6.76 months (range 4-8 months) while delayed healing occur in five cases with mean healing time 13.6 months (range 10-16 months). Non-union occur in three patients at one of the end of free fibula. Three patients develop stress fracture of fibula once the unprotected mobilisation was started. Out of these three patients, free vascularised fibula was done for defect of femur in one patient and for defect of the tibia in two patients [Table 4].

Regarding donor side morbidity six patients complained of transient weakness of foot evertors and great toe flexor muscles during early post-operative period. Diffuse leg and ankle joint discomfort after long walking was noted in five patients. Four patients had partial graft loss at the flap donor sites which were regrafted and complete healing of donor site was achieved. Paresthesia on the dorsum of the foot or calf area was noted in five patients during the first few post-operative months [Table 5].

## DISCUSSION

The aims of treatment for long bone defects are re-establishing pre-injury anatomy and function with lower complication rates. The main indication of vascularised bone transfer in post-traumatic bone defects has typically been the reconstruction of large long defects (>6 cm), especially when combined with soft-tissue defects. Other indications include infected or uninfected non-unions unresponsive to conventional treatment modalities, post-radical resection for osteomyelitis and congenital pseudoarthrosis of the tibia. The fibula and the ilium are the most commonly used vascularised grafts for extremity



**Figure 3:** (a) Pre-operative X-ray of 10-year-old boy with a compound fracture left leg with osteomyelitis, (b) post-operative X-ray after free fibula transfer showing improper reduction at the lower end, (c) after reduction (d and e) 6 and 9 months post-operative

**Table 3: Method of fixation**

Method of fixation	No. of patients (results)
Plate and screw	1 (good reduction in all patient)
External fixator with K-wires	8 (poor reduction in 4 patient)
External fixator with transcortical screws	15 (good reduction in all patient)
Transcortical screws	4 (good reduction in all patient)
Total	28 (good reduction in all patient)

**Table 4: Complication rates**

Complication	% of complication	No. of patients
Non union	10.7	3
Delayed union	17.85	5
Stress fracture	10.7	3
Flap loss	10.7	3

**Table 5: Donor site morbidity**

Morbidity	No. of patients (%)	Clinical course
Weakness of foot evertors and great toe flexors	6 (24)	Improved
Diffuse leg pain	5 (20)	Relieved
Paraesthesia on the dorsum of foot	5 (20)	Improved
Partial graft loss	4 (16)	Supplement grafting

reconstruction. The fibular graft is more popular because it is easier to align, has greater strength and can bridge larger gaps than can the iliac bone graft.<sup>[17]</sup>

Although the elevation of the vascularised fibula and osteocutaneous fibular flap is easy and fast, this graft and reconstruction always require high technical microvascular demands for the surgeon or close collaboration between orthopedic and plastic surgery teams. Unfortunately, in practice, this facility is often unavailable in many units.<sup>[18]</sup>

In our study, all the patients had long bone defect following road traffic accident. Out of the 28 patients, most of the patients (24 patients) were male reason being the male patients are more exposed to the external environment as supported by various studies.<sup>[19]</sup> Most of these patients are either using two-wheeler or walking on the road and hit by another speeding vehicle.

Majority of the patients in our study (23 patients) had a defect of tibia following road traffic accident. All these patients had severe crushing of leg with comminuted fracture of the tibia and soft-tissue defect as seen in various studies lower extremities are more commonly involved in comparison to upper extremities in road traffic accidents.<sup>[20,21]</sup>

The timing of surgery also plays an important role in microvascular reconstruction of post-traumatic long bone defects. As this study shows, most of the patients were operated between 1<sup>st</sup> and 6<sup>th</sup> weeks of trauma and rate of complication is also more in this time period as 9 out of 20 patients, which were operated in this time period, developed vascular complication while only 1 out of 6 patients, which were operated after 6 weeks of trauma, developed vascular complication. None of the patient, who was operated within a week of trauma, developed any complication. Byrd *et al.* described acute, sub-acute and chronic phases of open tibial fracture. He reported higher flap failure rate in the sub-acute phase between 1 and 6 weeks.<sup>[22]</sup> Godina reported 0.75% incidence of flap failure in a group reconstructed within 72 h in comparison to 12% flap failure in a group reconstructed between 72 h and 3 months of injury. Those reconstructed beyond 3 months had slightly better failure rate (9.5%).<sup>[23]</sup>

As per the method of fixation was concerned, fixation with K-wire is not very reliable method of fixation. As

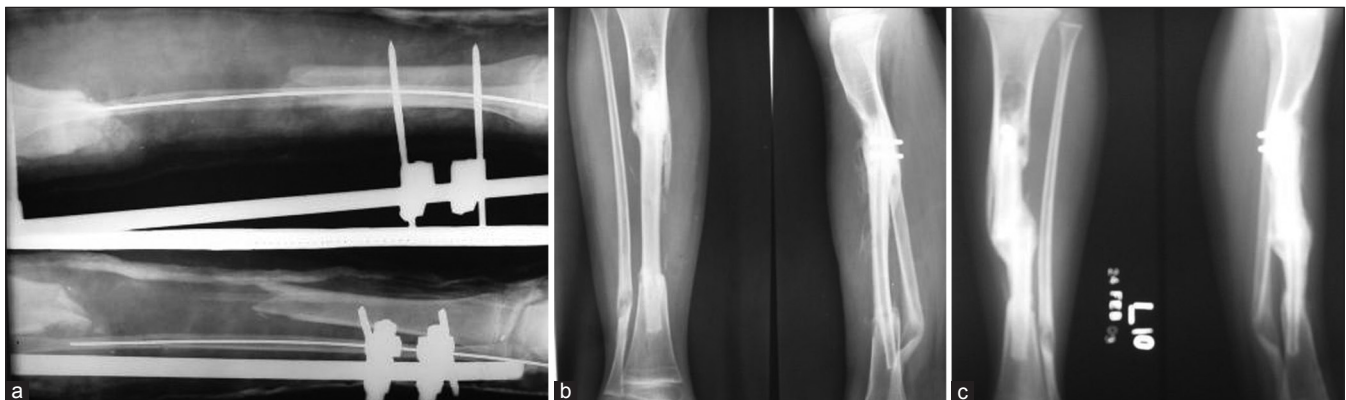
evident from the study, 4 out of 8 patients (50%) shows poor reduction in the post-operative period.

Out of the 25 free fibula flaps which survived, delayed union occurs in five cases. In three of the patients infection was present at the recipient site for which antibiotic coverage according to culture sensitivity was given for a prolonged period with regular dressings while two of the patients were of old age (>50 years).

Non-union occur in three of the patients. In these cases, inadequate stabilisation and osteoporotic bone could be the most probable cause of non-union. The cancellous bone grafting was done later on and satisfactory union was achieved.

Three patients developed a stress fracture of transferred vascularised fibula. All these patients started unprotected walking early without significant hypertrophy of the transferred fibula. After closed reduction, all these patients were put on immobilisation cast for an additional period of time and check X-rays were done for fracture healing during follow-up visits [Figure 4].

Concerning donor-site morbidity, the most common complication was weakness of the donor leg muscle in 6 (24%) cases. Skraba and Greenwald<sup>[24]</sup> and Youdas *et al.*<sup>[25]</sup> reported that many leg muscles originated from the fibula and the tibiofibular interosseous membrane and that muscle strength was significantly impaired after vascularised fibular grafts were harvested; there were also inverse relationships between the length of the resected fibula and ankle evtor muscle strength. Lee and Park reported weakness of donor leg muscles in 19.6% of patients.<sup>[11]</sup> However in our study, strength of leg evertors and great toe flexors improved with progressive weight bearing and physiotherapy. Ankle joint



**Figure 4:** (a) Pre-operative X-ray of 22-year-old boy with defect left tibia, (b) 6 months post-operative X-ray showing satisfactory healing with hypertrophy, (c) 10 months post-operative X-ray showing healed stress fracture in transferred free fibula

instability was not a problem in our study as we have left a minimum of 6 cm of fibula distally at the ankle joint. In our study, five patients complained of diffuse leg and ankle joint discomfort after long walking, but all of them improved in subsequent visits. Sensory paresthesia or hypoesthesia was noted in five patients during the first few post-operative months, which subsequently disappeared during follow-up visits. This could be because of inadvertent injury to the superficial peroneal nerve during flap harvest, which recovers progressively over a period of time. Four patients had partial skin graft loss from the flap donor site, in all these cases supplement grafting was done and complete healing was achieved.

## CONCLUSION

Large long bone defects are a challenging problem to both orthopedic and plastic surgeons. They are usually the result of high-energy trauma, tumour resection or osteomyelitis. The vascularised free fibula is a viable method for the reconstruction of skeletal defects of more than 6 cm, especially in cases of scarred and avascular recipient sites or in patients with combined bone and soft-tissue defects. Timing of surgery also plays an important role in microvascular reconstruction in trauma patients as proven by various studies. As the number of cases in our first group, i.e., those who were operated within 1 week are very less<sup>[2]</sup> and statistically it does not prove the hypothesis ( $P$  value is 0.245), but still most of the post-operative complications occurred in those patients who presented late to us. By improving the transportation facilities, making strict referral protocols and better collaboration of orthopaedic and plastic surgery team, these complications due to delayed treatment can be avoided.

## REFERENCES

1. Doi K, Kawakami F, Hiura Y, Oda T, Sakai K, Kawai S. One-stage treatment of infected bone defects of the tibia with skin loss by free vascularized osteocutaneous grafts. *Microsurgery* 1995;16:704-12.
2. Platz A, Werner CM, Künzi W, Trentz O, Meyer VE. Reconstruction of posttraumatic bony defects of the lower extremity: Callotaxis or free vascularized fibula graft? *Handchir Mikrochir Plast Chir* 2004;36:397-404.
3. Osterman AL, Bora FW. Free vascularized bone grafting for large-gap nonunion of long bones. *Orthop Clin North Am* 1984;15:131-42.
4. Weiland AJ, Moore JR, Daniel RK. Vascularized bone autografts. Experience with 41 cases. *Clin Orthop Relat Res* 1983;174:87-95.
5. Tu YK, Yen CY, Yeh WL, Wang IC, Wang KC, Ueng WN. Reconstruction of posttraumatic long bone defect with free

- vascularized bone graft: Good outcome in 48 patients with 6 years' follow-up. *Acta Orthop Scand* 2001;72:359-64.
6. Arai K, Toh S, Tsubo K, Nishikawa S, Narita S, Miura H. Complications of vascularized fibula graft for reconstruction of long bones. *Plast Reconstr Surg* 2002;109:2301-6.
7. Wei FC, Chen HC, Chuang CC, Noordhoff MS. Fibular osteoseptocutaneous flap: Anatomic study and clinical application. *Plast Reconstr Surg* 1986;78:191-200.
8. Taylor GI, Miller GD, Ham FJ. The free vascularized bone graft. A clinical extension of microvascular techniques. *Plast Reconstr Surg* 1975;55:533-44.
9. Gilbert A. Vascularised transfer of the fibula shaft. *Int J Microsurg* 1979;1:100-2.
10. Tamai S, Sakamoto H, Hori Y, Tatsumi Y, Nakamura Y, Shimizu T, Fukui A. Vascularised fibular transplantation: a report of 8 cases in the treatment of traumatic bony defect or pseudoarthrosis of long bones. *Int J Microsurg* 1980;2:205-12.
11. Lee KS, Park JW. Free vascularized osteocutaneous fibular graft to the tibia. *Microsurgery* 1999;19:141-7.
12. Chen ZW, Yan W. The study and clinical application of the osteocutaneous flap of fibula. *Microsurgery* 1983;4:11-6.
13. Yajima H, Tamai S, Kobata Y, Murata K, Fukui A, Takakura Y. Vascularized composite tissue transfers or open fractures with massive soft-tissue defects in the lower extremities. *Microsurgery* 2002;22:114-21.
14. Yazar S, Lin CH, Wei FC. One-stage reconstruction of composite bone and soft-tissue defects in traumatic lower extremities. *Plast Reconstr Surg* 2004;114:1457-66.
15. Kruse AL, Luebbbers HT, Grätz KW, Obwegeser JA. Free flap monitoring protocol. *J Craniofac Surg* 2010;21:1262-3.
16. Hsu RW, Wood MB, Sim FH, Chao EY. Free vascularised fibular grafting for reconstruction after tumour resection. *J Bone Joint Surg Br* 1997;79:36-42.
17. Wood MB, Cooney WP 3<sup>rd</sup>, Irons GB Jr. Skeletal reconstruction by vascularized bone transfer: Indications and results. *Mayo Clin Proc* 1985;60:729-34.
18. Francel TJ, Vander Kolk CA, Hoopes JE, Manson PN, Yaremchuk MJ. Microvascular soft-tissue transplantation for reconstruction of acute open tibial fractures: Timing of coverage and long-term functional results. *Plast Reconstr Surg* 1992;89:478-87.
19. Peden M, Scurfield R, Sleet D, Mohan D, Hyder Adnan A, Jarawan E, Mathers C. *World Report on Road Traffic Injury Prevention: summary*. Geneva: WHO; 2004. p. 13.
20. Singh A, Bhardwaj A, Pathak R, Ahluwalia SK. An epidemiological study of road traffic accident cases at a tertiary care hospital in rural Haryana. *Indian J Community Health* 2011;23:53-5.
21. Ganveer GB, Tiwari RR. Injury pattern among non-fatal road traffic accident cases: A cross-sectional study in Central India. *Indian J Med Sci* 2005;59:9-12.
22. Byrd HS, Cierny G 3<sup>rd</sup>, Tebbetts JB. The management of open tibial fractures with associated soft-tissue loss: External pin fixation with early flap coverage. *Plast Reconstr Surg* 1981;68:73-82.
23. Godina M. Early microsurgical reconstruction of complex trauma of the extremities. *Plast Reconstr Surg* 1986;78:285-92.
24. Skrabala JS, Greenwald AS. The role of the interosseous membrane on tibiofibular weightbearing. *Foot Ankle* 1984;4:301-4.
25. Youdas JW, Wood MB, Cahalan TD, Chao EY. A quantitative analysis of donor site morbidity after vascularized fibula transfer. *J Orthop Res* 1988;6:621-9.

**How to cite this article:** Kalra GS, Goel P, Singh PK. Reconstruction of post-traumatic long bone defect with vascularised free fibula: A series of 28 cases. *Indian J Plast Surg* 2013;46:543-8.

**Source of Support:** Nil. **Conflict of Interest:** None declared.