

Original Article

Gross anatomy of superficial fascia and future localised fat deposit areas of the abdomen in foetus

Pramod Kumar, Arvind Kumar Pandey¹, Brijesh Kumar¹, K. S. Aithal², Antony Sylvan Dsouza¹

Departments of Plastic Surgery and Burns, and ¹Anatomy, Kasturba Medical College, ²Department of Physics, Manipal Institute of Technology, Manipal University, Manipal, Karnataka, India

Address for correspondence: Dr. Pramod Kumar, Department of Plastic Surgery, King Abdul Aziz Hospital, Sakaka, Al-Jouf, Ministry of Health, Saudi Arabia E-mail: kumar.drpramod@hotmail.com

ABSTRACT

Background: The development and popularity of body contouring procedures such as liposuction and abdominoplasty has renewed interest in the anatomy of the superficial fascia and subcutaneous fat deposits of the abdomen. The study of anatomy of fascia and fetal adipose tissue was proposed as it may be of value in understanding the possible programming of prevention of obesity. **Objectives:** The present study was undertaken to understand the gross anatomy of superficial fascia of abdomen and to study the gross anatomy of future localized fat deposits (LFDs) area of abdomen in fetus. **Materials and Methods:** Four fetus (two male & two female) of four month of intrauterine life were dissected. Attachments & layers of superficial fascia and future subcutaneous fat deposit area of upper and lower abdomen were noted. **Results:** Superficial fascia of the abdomen was multi layered in mid line and number of layers reduced laterally as in adult. The future abdominal LFD (localized fat deposits) area in fetus shows brownish-white blubbary tissue without well-defined adult fat lobules. **Conclusion:** The attachment and gross anatomy of superficial fascia of the fetus was similar to that in adults. The future LFD areas showed brownish white blubbary tissue with ill-defined fat lobules.

KEY WORDS

Localised fat deposits; obesity; subcutaneous fat; superficial fascia

INTRODUCTION

Superficial fascia of the abdomen lies between the skin and muscles of the anterior abdominal wall and there is no deep fascia in this region.^[1-8] Since the development and popularity of body contouring procedures such as liposuction and abdominoplasty, a renewed interest in the superficial fascia has appeared in the plastic

surgical literature.^[9,10] Better knowledge of anatomy of fat and fascia is must for refined body contouring procedures. Furthermore, knowledge of embryology of fat is must for a plastic surgeon who is interested in research to prevent deposition and avoid surgery in selected cases.

The present study was undertaken to understand the gross anatomy of superficial fascia of the abdomen and areas of foetus abdomen corresponding to the areas of the adult where in future localised fat deposit (LFD) will occur.

MATERIALS AND METHODS

Cadaver dissection

Four foetuses (2 male and 2 female) of 4 months of intrauterine life were studied.

Access this article online

Quick Response Code:



Website:

www.ijps.org

DOI:

10.4103/0970-0358.122002

Three vertical and two horizontal lines were drawn over the front of the trunk and one vertical and one horizontal line on the back of the trunk as described by authors in 2011,^[11] then along these lines 2 cm wide skin strip along with fascia (up to the muscles) were removed to study the anatomy of the fascia and fat deposits area of the abdomen.

The attachments of fascia and gross anatomy of future LFDs' of the abdomen was recorded.

RESULTS

Attachments of superficial fascia

Upper attachment

Upper attachment was along the line extending from a point over costal margin (between anterior axillary and mid-clavicular line) to another point situated between the umbilicus and midpoint between pubic symphysis and umbilicus.

Lower attachment

After crossing pubic symphysis and inguinal ligament, it merged with superficial fascia of thigh and fascia-lata. Medially, it was multi layered and laterally bi-layered.

Medial attachment

Medially in midline, multi layered fascia (with its deeper relatively thicker layers) was found to fuse with contralateral corresponding fascia. In the midline, relatively thicker deeper layers of fascia was found to be merged to the abdominal wall (rectus sheath and linea alba).

Lateral attachment

On tracing the multi layered fascia of midline laterally, various fascial layers were found to fuse gradually with each other until it became three distinct layers near midaxillary line and then reduced to two layers just before merging with abdominal wall (external oblique fascia) between midaxillary and anterior axillary line.

Anatomy of future LFD's

The shapes of loin (flank) LFD's were spindle shape in all the foetuses. The abdominal LFD's showed multi layered fascia [Figure 1].

The tissue at corresponding area of the abdomen and loin (flank) LFD's in all four foetuses was like loose areolar tissue filled with whitish-brown blubbery tissue [Figure 2]. No fat lobule was seen.

DISCUSSION

A study of the anatomy of the superficial fascia in fresh and embalmed cadavers in adults has been conducted by various authors.^[9-11] In the present study on four foetuses' cadaver of 4 months gestational age, we found that superficial fascia of the abdomen was multi layered in mid line and number of layers gradually reduced laterally as these layers merged with each other. We didn't find any difference in attachment and layers of superficial fascia in the foetus as compared with that in adults [Table 1 and Figure 1].^[11]

Study of 50 computed tomography^[12] of the abdominal region of either sex the vertical and horizontal extent of membranous layer supports our findings of fascial attachments.

The shape of loin (flank) LFD in all the four foetuses were spindle shaped. The comparison of shape and gross anatomy of the future LFD's in the foetus with that in adults is presented in tabular form [Table 1].

Adipose tissue first appears at around mid-gestation. Total adipose mass then increases through late gestation, when it comprises a mixture of white and brown adipocytes. Brown adipose tissue possesses a unique uncoupling protein (UCP1), which is responsible for the rapid generation of large amounts of heat at birth. Then, during the postnatal life some, but not all depots are replaced by white fat.^[13] The dual characteristics of foetal fat reflect its critical role at birth in providing lipid that is mobilised rapidly following activation of UCP1 upon cold exposure to the extra uterine environment.^[14]

In the present study on four foetuses of four month of intrauterine life (prior to mid gestation) the area corresponding to adult abdominal LFD^[15] showed brownish-white blubbery tissue [Figure 2] without well-defined adult fat cells [Table 1]. Lipid-rich, collagen fibre-laced blubber can comprise up to 50% of the body mass of some marine mammals during some points in their lives and can range from two inches (5 cm) thick in dolphins and smaller whales, to more than 12 inches (30 cm) thick in some bigger whales, such as right and bowhead whales. However, this is not indicative of larger whales' ability to retain heat better as the thickness of a whale's blubber does not significantly affect heat loss. Water content in blubber of whale

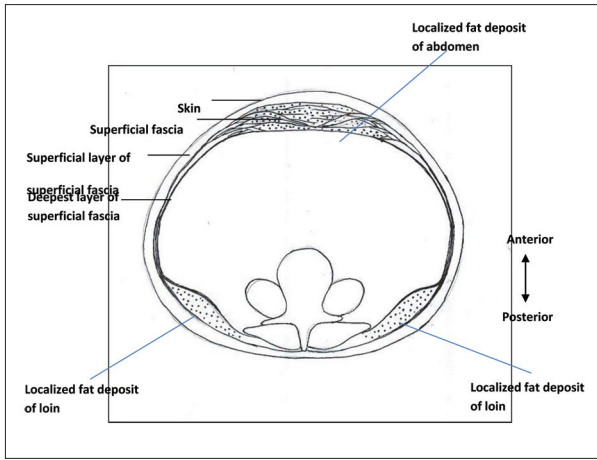


Figure 1: Cross-sectional anatomy at the level of umbilicus; line diagram showing details of the layers of superficial fascia of the abdomen and its relation to future subcutaneous fat lobule

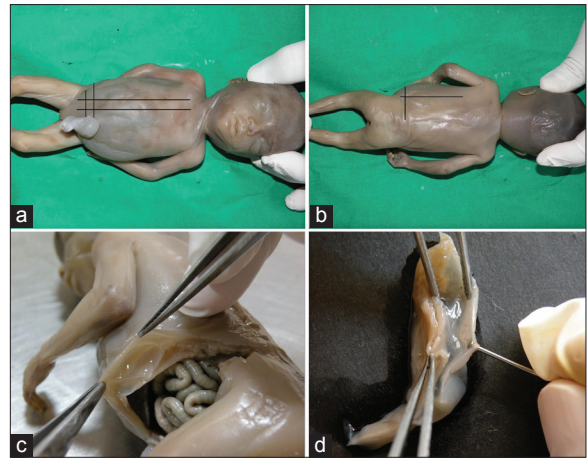


Figure 2: (a, b) Show lines^[11] on the trunk of foetus that were used to dissect fascia and localised fat deposits (LFDs) of abdomen; (c) Shows well developed fascia with poorly developed abdominal muscles at 4 months of intrauterine life of the foetus; (d) Shows blubbery tissue (in place of fat lobules of adult LFD's) at 4 months of intrauterine life of the foetus

Table 1: Comparison of LFD's of abdomen between adult and future LFD's of foetus

Region	Shape and arrangement in adult ^[11]	Shape and arrangement in the foetus
Upper abdomen	Superficial layer of subcutaneous fat lobules were elongated and arranged perpendicular to skin Deeper layer of lobules were rounded in shape	Tissue in corresponding area of fat lobules were like loose areolar tissue filled with whitish-brown blubbery tissue [Figure 2]
Lower abdomen	Fat lobules were elongated and arranged perpendicular to skin Most dependent lobules were larger in size	The tissue was same as described in the upper abdomen region of the foetus
Loin	Shape of loin LFD area was triangular with apex pointing medially Fat superficial to deep fascia: Flattened elongated fat lobules arranged parallel to skin posteriorly In posterior axillary line gradually fat lobules become rounded From posterior axillary line to anterior abdomen arrangement progressively becomes vertical perpendicular to skin	The shape of the corresponding loin area was spindle shaped The tissue at corresponding area was like loose areolar tissue with the multiple septae Gap between septae filled with whitish brown blubbery tissue [Figure 2]

LFD: Localised fat deposit

reduces heat-retaining capacities and lipid content in blubber increases them.^[16,17] Blubber may save energy and adds buoyancy for marine mammals such as dolphins.^[18] Blubber from whales and seals contains omega-3 fatty acids and vitamin D.^[19]

The present study adds the existing knowledge of embryology of fat related to abdominal LFD's in human beings, the area of interest for plastic surgeons and researchers.

CONCLUSION

The attachment and gross anatomy of superficial fascia of the foetuses of 4 months intrauterine life was similar to that in adults.^[11] The corresponding abdominal LFD areas in all four foetuses show brownish-white blubbery tissue in place of well-defined fat lobules of adult.

Limitations and further recommendations

Non-availability of enough foetuses within a reasonable time period was a limitation of the present study. Furthermore, lack of adequate information on our research area was a problem to some extent. Hence, further study with more number of foetuses including histological study is recommended.

REFERENCES

- Borley NR. Anterior abdominal wall. In: Standring S., Gray's Anatomy, the Anatomical Basis of Clinical Practice. 40th ed. London: Churchill Livingstone; 2008. p. 1060.
- Moore KL, Dalley AF, editors. Clinically Oriented Anatomy. 5th ed. Philadelphia: Lippincott Williams & Wilkins; 2006. p. 196-8.
- Romanes GJ, editor. Cunningham's Text Book of Anatomy. 12th ed. Oxford: Oxford University Press; 1981. p. 275.
- Basmajian JV, editor. Grant's Method of Anatomy. 10th ed. Baltimore: Williams & Wilkins; 1980. p. 123.
- Hall-Craggs EC, editor. Anatomy as a Basis for Clinical Medicine. 2nd ed. Baltimore-Munich: Urban & Schwarzenberg; 1990. p. 225.

6. Hollinshed WH, Rosse C, editors. Text Book of Anatomy. 4th ed. Philadelphia: Harper & Row; 1985. p. 581.
7. Snell RS, editor. Clinical Anatomy for Medical Students. 5th ed. Boston: Little, Brown & Co.; 1995. p. 136.
8. Sinnatamby CS, editor. Last's Anatomy, Regional and Applied. 11th ed. Edinburgh: Churchill Livingstone; 2006. p. 185.
9. Abu-Hijleh MF, Roshier AL, Al-Shboul Q, Dharap AS, Harris PF. The membranous layer of superficial fascia: Evidence for its widespread distribution in the body. *Surg Radiol Anat* 2006;28:606-19.
10. Lockwood TE. Superficial fascial system (SFS) of the trunk and extremities: A new concept. *Plast Reconstr Surg* 1991;87:1009-18.
11. Kumar P, Pandey AK, Kumar B, Aithal SK. Anatomical study of superficial fascia and localized fat deposits of abdomen. *Indian J Plast Surg* 2011;44:478-83.
12. Chopra J, Rani A, Rani A, Srivastava AK, Sharma PK. Re-evaluation of superficial fascia of anterior abdominal wall: A computed tomographic study. *Surg Radiol Anat* 2011;33:843-9.
13. Symonds ME, Pope M, Sharkey D, Budge H. Adipose tissue and fetal programming. *Diabetologia* 2012;55:1597-606.
14. Symonds ME, Mostyn A, Pearce S, Budge H, Stephenson T. Endocrine and nutritional regulation of fetal adipose tissue development. *J Endocrinol* 2003;179:293-9.
15. Illouz Y, editor. Body Sculpturing by Lipoplasty. Edinburgh: Churchill Livingstone; 1989.
16. Struntz DJ, McLellan WA, Dillaman RM, Blum JE, Kucklick JR, Pabst DA. Blubber development in bottlenose dolphins (*Tursiops truncatus*). *J Morphol* 2004;259:7-20.
17. Kvadsheim PH, Folkow LP, Blix AS. Thermal conductivity of minke whale blubber. *J Therm Biol* 1996;21:123-8.
18. Bouncy blubber. Science Update AAAS. Available from: http://www.sciencenetlinks.net/sci_update.php?DocID=10. (Quoted in blubber. Available from: <http://www.en.wikipedia.org/wiki/Blubber>). [Last accessed on 2013 May 31].
19. Kuhnlein HV, Barthelet V, Farren A, Falahi E, Leggee D, Receveur O, *et al.* Vitamins A, D, and E in Canadian Arctic traditional food and adult diets. *J Food Compos Anal* 2006;19:495-506.

How to cite this article: Kumar P, Pandey AK, Kumar B, Aithal KS, Dsouza AS. Gross anatomy of superficial fascia and future localised fat deposit areas of the abdomen in foetus. *Indian J Plast Surg* 2013;46:529-32.

Source of Support: Nil. **Conflict of Interest:** None declared.

Announcement

Android App



Download
**Android
application**

FREE

A free application to browse and search the journal's content is now available for Android based mobiles and devices. The application provides "Table of Contents" of the latest issues, which are stored on the device for future offline browsing. Internet connection is required to access the back issues and search facility. The application is compatible with all the versions of Android. The application can be downloaded from <https://market.android.com/details?id=comm.app.medknow>. For suggestions and comments do write back to us.