

## Original Article

# Aesthetical outcome after breast reconstruction using deep inferior epigastric perforator flap: Personal techniques

Chiara Gelati, Luca Negosanti, Erich Fabbri, Riccardo Cipriani

Department of Plastic Surgery, S. Orsola-Malpighi University Hospital, Bologna, Italy

**Address for correspondence:** Dr. Luca Negosanti, Department of Plastic Surgery, S. Orsola-Malpighi University Hospital, Via Massarenti-9, 40138, Bologna, Italy. E-mail: luca.negosanti81@gmail.com

### ABSTRACT

**Background:** Now-a-days, deep inferior epigastric perforator (DIEP) flap breast reconstruction is widespread throughout the world. The aesthetical result is very important in breast reconstruction and its improvement is mandatory for plastic surgeons. **Materials and Methods:** The most frequent problems, we have observed in breast reconstruction with DIEP flap are breast asymmetry in terms of volume and shape, the bulkiness of the inferior lateral quadrant of the new breast, the loss of volume of the upper pole and the lack of projection of the inferior pole. We proposed our personal techniques to improve the aesthetical result in DIEP flap breast reconstruction. Our experience consists of more than 220 DIEP flap breast reconstructions. Results: The methods mentioned for improving the aesthetics of the reconstructed breast reported good results in all cases. **Conclusion:** The aim of our work is to describe our personal techniques in order to correct the mentioned problems and improve the final aesthetical outcome in DIEP flap breast reconstruction.

### KEY WORDS

Aesthetic refinements; breast reconstruction; deep inferior epigastric perforator flap

### INTRODUCTION

Reconstruction of breast by deep inferior epigastric perforator (DIEP) flap<sup>[1]</sup> is popular throughout the world.<sup>[2,3]</sup> However, we are still concerned about how to improve the aesthetic results.<sup>[4-6]</sup> In this respect what we are still trying to improve is breast -symmetry in terms of volume and shape, bulkiness of the inferior lateral quadrant of the new breast (if anastomosis were

performed in axilla), loss of volume of the upper pole and lack of projection of the inferior pole.

The aim of our work is to describe our personal techniques in order to improve the final aesthetic outcome in DIEP flap breast reconstruction.

### MATERIALS AND METHODS

Since 1997, we have been performing 226 breast reconstructions with DIEP flap in the Department of Plastic and Reconstructive Surgery at S. Orsola-Malpighi Hospital. The mean average age of our patients was 49.6 years old (range: 29-73). The reconstruction was immediate in 96 cases (42, 48%) and delayed in 130 cases (57, 52%); in this last group 16 patients were previously reconstructed using other techniques (11 by prosthesis and 5 with lipofilling).

#### Access this article online

Quick Response Code:



Website:

www.ijps.org

DOI:

10.4103/0970-0358.121997

Nearly 92% of these patients underwent surgical refinements to improve the aesthetic outcome. Most of these refinements were performed intraoperatively, but when this is not possible, we perform secondary revisions a few months later, usually under local anaesthesia.

## SURGICAL TECHNIQUES

### Lateral bulkiness reduction and upper pole improvement

During the flap inseting, we usually leave the lateral part of the flap bulky in order not to have any risk with flap vascularisation.

During the flap modeling, we harvest a subcutaneous pocket superiorly, in order to fill the upper pole of the new breast with the flap, partially de-epithelialised and fixed to the pectoral major muscle with re-absorbable stitches. In order to reduce the risk of secondary liponecrosis, we usually try not to remove too much fat from the adipose layer of the superior edge of the flap. This can sometimes lead to a gap between the DIEP flap and the skin in the upper pole, particularly evident in obese patients where the abdominal fat layer is very thick.

When it is possible, we try to correct lateral bulkiness and the upper pole gap at the same time harvesting local flaps or using a combination of lipoaspiration and lipofilling.

Local flaps are our first choice. Under local anaesthesia, we harvest a vertical flap, based superiorly, from the new breast's lateral side, exactly where the bulkiness is. The length to breadth ratio is 2:1 or 3:1. The flap is then de-epithelialised and transposed to a subcutaneous pocket in the upper pole where the defect is. The flap is fixed with transcutaneous stitches and the donor site is closed primarily [Figure 1].

Our second choice is to make a lipoaspiration of the lateral bulky side and use this tissue, harvested following the principles described by Coleman,<sup>[7]</sup> to 'lipofill' the upper pole. In many cases, the amount of adipose tissue obtained from the bulky area is not sufficient, so we use other donor sites.

### Flap projection improvement

In young patients with a projected contralateral breast or after mastopexy, we often need to improve DIEP flap projection in order to obtain a better symmetry. We use different techniques to do this.

### Inframammary fold recreation

The lack of projection can easily be solved by recreating the inframammary fold in the reconstructed breast as we usually do with implants' breast reconstruction. We use a 2-0 polypropylene non-reabsorbable running suture. The position of the fold is decided after abdominal donor site closure to avoid tension effects induced by abdominoplasty.

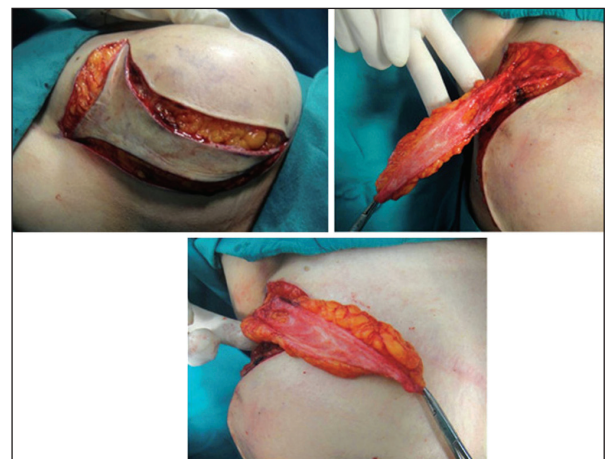### Local flaps in delayed reconstructions

In delayed reconstructions, flap projection improvement can be reached using local flaps. During DIEP flap modelling, the inferior margin of the flap slides at the level of the inframammary fold, so the skin paddle under the mastectomy scar needs to be removed. We started to use this skin paddle to harvest a small flap that is de-epithelialised and pedicled inferiorly at the level of the inframammary crease. The flap pedicle is exactly positioned at a sternal distance corresponding to the other breast major projection point. Then the flap is rolled on itself to reproduce a cone like shape [Figure 2]. The DIEP flap is laid on it and modeled as usual.

### Double DIEP flap in monolateral reconstruction

This is a challenging technique to obtain a good projection, especially in young patients with a projected contralateral breast that does not need mastopexy.

We performed this reconstruction in a 36-year-old female patient who affected by a recurrence of a mucinous carcinoma of the right breast. Our surgical plan was to harvest DIEP flap and contralateral breast reduction, but the patient was not prepared to accept any contralateral breast scar.



**Figure 1:** A vertical flap was harvested from the lateral bulkiness of the reconstructed breast. The flap was de-epithelialised and transposed to a subcutaneous pocket in the upper pole

As the patient was slightly overweight, the abdomen was sufficient to harvest a double DIEP flap to reconstruct one breast, in order to give it more volume and projection. During the flap harvesting, we found two good perforators, one on the right side of the abdomen and the other one on the left side, near the lateral border of the rectus abdominis muscle. We harvested two distinguished flaps: Areas 1-3 composed the left side flap and the right side flap was composed of Area 4. The smaller flap was 'V-shaped' and de-epithelialised obtaining a cone, similar in shape to a prosthesis; flap modeling was made before pedicle section. The two flaps were then transferred and immediately vascularised with end-to-end anastomosis to thoracodorsal vessels, for the bigger one and circumflex scapular vessels, for the buried flap. The smaller flap was buried under the other to obtain an increased volume and a better projection. The inframammary fold was fixed with a 2/0 polypropylene non-reabsorbable suture and the lower side of the bigger flap was sutured to the thorax at this level [Figure 3]. No major complications were observed.

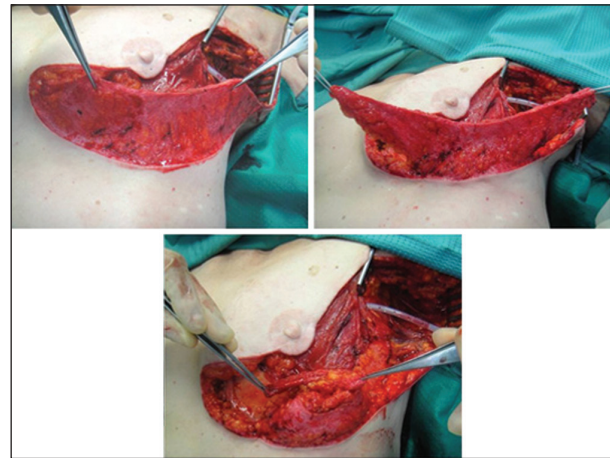
### Breast symmetry

Breast asymmetry is always observed in unilateral breast reconstruction. More frequently the contralateral breast is bigger and needs to be reduced. Rarely, especially in young patients, the contralateral breast can be hypoplastic and a second DIEP flap can be used like an auto-prosthesis for breast augmentation, thus avoiding the need of an implant.<sup>[8-10]</sup>

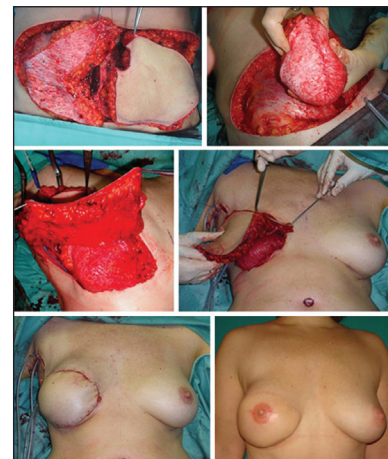The flap used for breast reconstruction included Areas 1-3 of DIEP flap and is transferred and modelled as usual. A smaller flap corresponding to Area 4, based on a different perforator, is de-epithelialised and sutured on itself medially to obtain a cone similar in shape to prosthesis. Flap modeling is made before pedicle section. Through an inframammary fold access, a sub-glandular pocket is harvested on the side of breast augmentation and the flap is inserted in it and fixed to the major pectoralis muscle with reabsorbable stitches. The anastomoses are performed in the axilla, leading the pedicle through a subcutaneous tunnel, to the thoracodorsal or circumflex scapular vessels [Figure 4].

### RESULTS

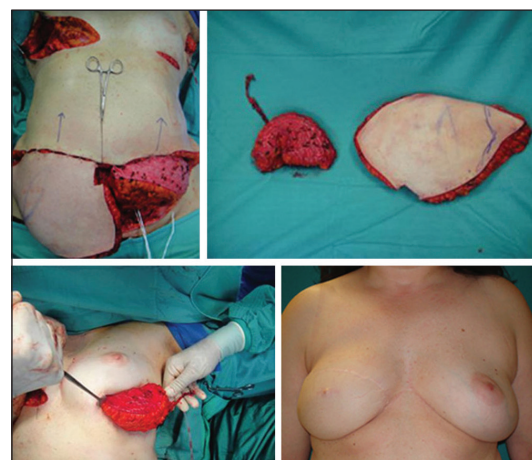
The average time of surgery is about 7 h. Only in double DIEP flap the time is slightly longer (average time: 9 h). Hospitalisation was the same in all cases (average 8 days, range: 7-9).



**Figure 2:** An inferiorly based skin flap, under the mastectomy scar, was harvested. The pedicle was centred on the major projection point and the flap was sutured on itself to obtain a cone shape



**Figure 3:** Monilateral double deep inferior epigastric perforator flap: The small one was V-shaped and sutured on itself on the medial edge obtaining a shape similar to prosthesis. The small flap was buried under the bigger one. The bigger flap was modeled as usual. The final effect was the increase of volume and projection of the reconstructed breast



**Figure 4:** Double deep inferior epigastric perforator flap for contralateral breast augmentation: The two flaps were harvested based on the two deep inferior epigastric pedicles. The small flap was inserted in a subglandular pocket through an inframammary access

With regard to major complications, in this series, we observed 9 cases of total necrosis of the flap and 15 cases of partial necrosis. No cases of infection or hematoma were recorded. Secondary revisions were always made under local anaesthesia and no hospitalisation. The average time of surgery was 40 min. We never perform the local flaps and nipple reconstruction together. No complications, such as necrosis or loss of volume, were observed in patients treated by local lateral flaps.

Local flaps in the inferior pole underwent some liponecrosis. This means lack of softness of the new breast. In the early treated cases, we observed liponecrosis in 20% of flaps while in the last ones we observed a failure rate decreasing (<5%) due to a better planning and particularly to a reduction of the height/length ratio of the lateral flaps.

The results were obtained in patients treated with the presented techniques were good in terms of symmetry and shape of the breasts with a high level of satisfaction reported by patients. This last consideration may not be indicative because also patients treated using a traditional method usually reported a similar level of satisfaction.

## DISCUSSION

Improvement of lateral bulkiness and upper pole deficiency could be easily achieved using local flaps or lipo-sculpture.<sup>[11]</sup> These two methods allow correction of both defects at the same time, with a simple surgery under local anaesthesia. We usually plan these corrections at an average time of 6 months after primary reconstruction, when the result can be considered as quite stable. We performed these techniques in almost 40% of our patients and very often we combined the two techniques together. We usually harvest the local lateral flap even if it's almost always not sufficient to bridge the gap because it's a simple procedure under local anaesthesia, which use tissues that other ways will be thrown away. On the other hand, in our experience, the lateral bulkiness can be better corrected with tissue excision than liposuction; this is due to a certain degree of fibrosis developed in this region after surgery.

Improvement of lower pole projection has two main goals: Better shape of the new breast and better symmetry with contralateral breast. Applying both inframammary suture and local flaps we noticed no significant increase in surgical

time. With a better planning of the base/high ratio of the flap we were able to reduce the incidence of partial liponecrosis from 20% to 5% of cases. Incidentally, no major complications like infection or fistulae due to liponecrosis were observed, but only a lack of softness of the inferior pole. The results obtained with the use of local flaps alone are not satisfactory, but this is a very simple technique, with no adjunctive costs for the patients, which can be associated to the inframammary fold recreation improving the results. We have used this technique in all cases of delayed reconstruction since 2010.

In our experience, unilateral reconstruction and contralateral breast augmentation with double DIEP flap could be useful and innovative.

Area 4 could be harvested as a free flap on its pedicle, modelled and used as autoprosthesis for contralateral augmentation. We used this technique in five cases: Two immediate and three delayed reconstructions after failure of reconstruction with prosthesis. Addictive mammoplasty with DIEP flap is indicated in all cases of young patients with hypoplastic contralateral breast or in patients that required breast augmentation with no implants. An increase in surgery time is still acceptable. No major complications are reported. The inframammary access used for flap in setting is not evident as in a common augmentation mammoplasty and the same is for the scar made in the axilla for anastomosis.

Unilateral double DIEP flap was used in one case with good results. Using "Area 4" based on its pedicle, we obtained a flap that could be easily modelled as an auto-prosthesis and buried under the other flap. No complications in the donor site were reported. We think that this method could be indicated in patients with a large contralateral breast when it is not possible to re-shape it for oncological reasons or to respect the wishes of the patient.

## CONCLUSION

Based on the above study it can be concluded that microsurgical breast reconstruction has almost reached optimum standards both in terms of surgical techniques and aesthetic results.

The aim of autologous tissue breast reconstruction is to achieve a good aesthetic result without implants. In our

work, we describe our personal techniques in order to improve the final aesthetic outcome in DIEP flap breast reconstruction.

Our experience with refinements like the use of local flaps in delayed reconstructions or the inframammary fold recreation to increase projection is an example of how you can save surgery time and costs, achieving increasingly better aesthetical results in the very first breast reconstruction.

Lateral bulkiness and upper pole deficiency can easily be corrected at the same time, under local anaesthesia and with a very little additional sacrifice for the patient.

Unilateral or bilateral breast reconstruction with double DIEP flap could be a valuable option to consider when indicated. No major complications were reported and post-operative recovery was not affected by the procedure. The only disadvantage of double DIEP flap was the longer time for flap harvesting. Any increase in surgery time is related to additional complete pedicle dissection and anastomosis. In our opinion, this disadvantage is not sufficient to avoid using this procedure that must be considered as a valuable option in selected cases.

## REFERENCES

1. Allen RJ, Treece P. Deep inferior epigastric perforator flap for breast reconstruction. *Ann Plast Surg* 1994;32:32-8.
2. Alderman AK, Wilkins EG, Lowery JC, Kim M, Davis JA.

- Determinants of patient satisfaction in postmastectomy breast reconstruction. *Plast Reconstr Surg* 2000;106:769-76.
3. Atisha D, Alderman AK, Lowery JC, Kuhn LE, Davis J, Wilkins EG. Prospective analysis of long-term psychosocial outcomes in breast reconstruction: Two-year postoperative results from the michigan breast reconstruction outcomes study. *Ann Surg* 2008;247:1019-28.
4. Blondeel PN, Hijjawi J, Depypere H, Roche N, Van Landuyt K. Shaping the breast in aesthetic and reconstructive breast surgery: An easy three-step principle. *Plast Reconstr Surg* 2009;123:455-62.
5. Enajat M, Smit JM, Rozen WM, Hartman EH, Liss A, Kildal M, *et al.* Aesthetic refinements and reoperative procedures following 370 consecutive DIEP and SIEA flap breast reconstructions: Important considerations for patient consent. *Aesthetic Plast Surg* 2010;34:306-12.
6. Munhoz AM, Ishida LH, Duarte GG, Cunha MS, Montag E, Sturtz G, *et al.* Aesthetic refinements in breast augmentation with deep inferior epigastric perforator flap: A case report. *Aesthetic Plast Surg* 2003;27:107-11.
7. Coleman SR. Structural fat grafting. *Aesthet Surg J* 1998;18:386, 388.
8. Allen RJ, Heitland AS. Autogenous augmentation mammoplasty with microsurgical tissue transfer. *Plast Reconstr Surg* 2003;112:91-100.
9. Huang JJ, Chao LF, Wu CW, Nguyen DH, Valerio IL, Cheng MH. Simultaneous scarless contralateral breast augmentation during unilateral breast reconstruction using bilateral differentially split DIEP flaps. *Plast Reconstr Surg* 2011;128:593e-604.
10. Drazan L, Vesely J, Hyza P, Castagnetti F, Stupka I, Justan I, *et al.* Bilateral breast reconstruction with DIEP flaps: 4 years experience. *J Plast Reconstr Aesthet Surg* 2008;61:1309-15.
11. Delay E, Garson S, Tousson G, Sinna R. Fat injection to the breast: Technique, results, and indications based on 880 procedures over 10 years. *Aesthet Surg J* 2009;29:360-76.

**How to cite this article:** Gelati C, Negosanti L, Fabbri E, Cipriani R. Aesthetical outcome after breast reconstruction using deep inferior epigastric perforator flap: Personal techniques. *Indian J Plast Surg* 2013;46:513-7.

**Source of Support:** Nil, **Conflict of Interest:** None declared.

## Announcement

### Android App



Download  
**Android  
application**

FREE

A free application to browse and search the journal's content is now available for Android based mobiles and devices. The application provides "Table of Contents" of the latest issues, which are stored on the device for future offline browsing. Internet connection is required to access the back issues and search facility. The application is compatible with all the versions of Android. The application can be downloaded from <https://market.android.com/details?id=comm.app.medknow>. For suggestions and comments do write back to us.