

Case Report

Management of bi-canalicular block: A novel technique

Manju Meena, Milind Naik¹, Santosh G. Honavar¹

Departments of Ophthalmic Plastics and Ocular Oncology, L. V. Prasad Eye Institute, Visakhapatnam,
¹L. V. Prasad Eye Institute, Hyderabad, Andhra Pradesh, India

Address for correspondence: Dr. Manju Meena, Department of Ophthalmic and Facial Plastics, Orbit and Ocular Oncology,
 L. V. Prasad Eye Institute, GMRV Campus, Visakhapatnam - 530 040, Andhra Pradesh, India. E-mail: mina_manju@yahoo.co.in

ABSTRACT

Medial canthal dystopia with canalicular obstruction is a common presentation following injury to the medial canthal region. Conjunctivodacryocystorhinostomy with Lester's Jones tube is considered as the standard treatment in such cases. Alternatively, these patients can be managed by retrograde intubation dacryocystorhinostomy with medial canthoplasty. We herein describe the modification of retrograde bicanalicular intubation, combined with medial canthoplasty (monopodicle flap) which gives good cosmetic results.

KEY WORDS

Bicanalicular intubation; dacryocystorhinostomy; retrograde canalicular intubation

INTRODUCTION

Conjunctivodacryocystorhinostomy with the Lester's Jones tube is the standard treatment option in cases of canalicular malformation.^[1] Although the functional results of this procedure are usually good, occasionally post-operative complications can lead to patient dissatisfaction (tube extrusion, tube maintenance).^[2]

Alternatively, these patients can be managed by dacryocystorhinostomy (DCR) with retrograde canalicular intubation. Herein, we shall discuss the management of proximal canalicular block with medial canthal dystopia by retrograde canalicular intubation and medial canthoplasty.

CASE REPORT

A 45-year-old male presented to us with complaint of epiphora in the left eye and a scar at medial canthus following a road traffic accident 1 year ago, with injury to the left upper and lower eyelid involving both the canaliculi. Primary repair of laceration was performed elsewhere, with no canalicular repair. On examination, left medial canthal dystopia of 4 mm and a scar near the canalicular region was noted. Syringing was performed, which revealed proximal lower canalicular obstruction 3 mm from the punctum and 2 mm obstruction from the upper punctum. The rest of ophthalmic examination was normal.

During the surgical procedure, skin incision site was marked for medial canthoplasty in the form of Z. External DCR through subciliary incision was performed. Lacrimal sac was opened and the common ostium was visualised. The stent of silicon tube, ends of which were bent at right angle, were passed retrogradely into the common internal opening and through the lower canaliculus. The tip of probe was palpable near the eyelid margin, distal to the obstruction, and a no. 15 Bard Parker's blade was

Access this article online

Quick Response Code:



Website:

www.ijps.org

DOI:

10.4103/0970-0358.113734

used to cut down onto the probe tip, thereby creating pseudopunctum [Figure 1a]. Similar procedure was performed for the upper eyelid. Silicone intubation was performed through common ostium, out through the lower pseudopunctum and returned through the upper pseudopunctum down through common ostium into the nose [Figure 1b]. DCR was then completed in usual way. Monopodicle flap from the upper eyelid containing skin and orbicularis was created. The medial canthal tendon was sutured to periostium of medial orbital rim at the desired location. Upper eyelid monopodicle flap was transposed to the lower eyelid defect, created after suturing the medial canthal tendon.

Tube was removed 3 months post-operatively and on last follow-up (6 months); patient was symptom free with a patent canaliculus on syringing and good cosmesis.

DISCUSSION

Retrograde intubation DCR technique was initially described by Wearne *et al.*, for the treatment of proximal and mid canalicular obstruction.^[3] Modification of this technique was described by Trakos *et al.*,^[4] key steps of this modified procedure are DCR, retrograde probing of canalicular system, creation of a pseudopunctum, and silicone intubation. In our case report we describe a further modification of this technique. Our technique differs from the one described by Trakos, in that the external approach was through subciliary incision, and both the canaliculi were intubated after creation of pseudopunctum. However, the initial intubation technique was similar to as described by Trakos; the stent was passed through the common internal opening to the lower canaliculi and through the lower pseudopunctum. But then the stent was inserted through upper pseudopunctum, upper canaliculi, common internal opening, then into the nose. Medial canthoplasty was an additional procedure which was done for the proper alignment of medial canthus.

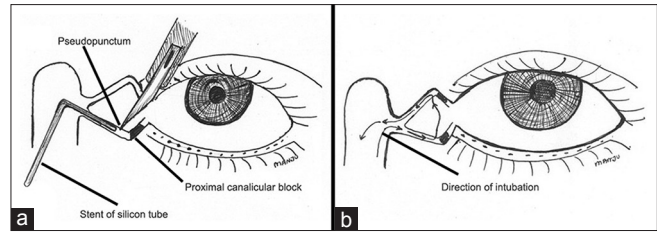


Figure 1: (a) Diagrammatic representation of the bicanalicular retrograde intubation dacryocystorhinostomy technique. (b) The direction of the silicon tube through the common internal opening into the canaliculi

To the best of our knowledge, this is a first case report of retrograde bicanalicular intubation DCR with medial canthoplasty. This is an effective technique in cases of post-traumatic proximal canalicular obstruction with medial canthal dystopia, yielding good cosmetic as well as functional results in such patients.

Large studies with longer follow-up are required to ascertain the surgical result. However, this is very difficult to do so as such modifications cannot be generalised. Therefore, we recommend this approach should be based on individual case selection.

REFERENCES

1. Jones LT. Conjunctivodacryocystorhinostomy. *Am J Ophthalmol* 1965;59:773-83.
2. Sekhar GC, Dortzbach RK, Gonnering RS, Lemke BN. Problems associated with conjunctivodacryocystorhinostomy. *Am J Ophthalmol* 1991;112:502-6.
3. Wearne MJ, Beigi B, Davis G, Rose GE. Retrograde intubation dacryocystorhinostomy for proximal and midcanalicular obstruction. *Ophthalmology* 1999;106:2325-8.
4. Trakos N, Mavrikakis E, Boboridis KG, Ralidis M, Dimitriadis G, Mavrikakis I. A modified technique of retrograde intubation dacryocystorhinostomy for proximal canalicular obstruction. *Clin Ophthalmol* 2009;3:681-4.

How to cite this article: Meena M, Naik M, Honavar SG. Management of bi-canalicular block: A novel technique. *Indian J Plast Surg* 2013;46:138-9.

Source of Support: Nil, **Conflict of Interest:** None declared.