

Case Report

Gluteal flap for omphalocele repair in a case of epigastric heteropagus: A novel approach for surgical management

Krushnakumar Kesan, Abhaya Gupta, Rahul Kumar Gupta, Paras Kothari, Ritesh Ranjan, Parag Karkera, Kedar Mudkhedkar

Department of Pediatric Surgery, LTMMC and LTMGH, Sion, Mumbai, Maharashtra, India

Address for correspondence: Dr. Krushnakumar Kesan, Department of Pediatric Surgery, LTMMC and LTMC Hospital, Sion, Mumbai, Maharashtra, India. E-mail: krishnakesan@rediffmail.com

ABSTRACT

Epigastric heteropagus is an extremely rare congenital anomaly, in which there is asymmetrical conjoined twinning, with the parasitic twin attached to the epigastrium. A 2-day-old male, with epigastric heteropagus and omphalocele, was operated in our institution. After excision of the parasitic twin, omphalocele was covered with a gluteal skin flap available from the parasitic twin. Post-operative course was uneventful, except for infection along the edges of the skin flaps, which was managed conservatively. Only 44 cases of epigastric heteropagus twins have been reported previously in world literature. We present a novel surgical approach for the repair of the omphalocele in a case of epigastric heteropagus twins, probably the 45th case to be reported in the world literature.

KEY WORDS

Conjoined twins; epigastric heteropagus; gluteal skin flap

INTRODUCTION

Conjoined twinning, a rare anomaly, is classified as symmetrical or asymmetrical. Asymmetrical conjoined twin has a member, the host (auto-site), which is near normal. The host bears the parasite, which is incomplete, smaller, and fully dependent on it for growth. This form of conjoined twins is referred to as heteropagus and when attached to the epigastrium of the auto-site, is called epigastric heteropagus. Epigastric heteropagus and omphalocele of auto-site is a common association.^[1,2] Various approaches for the management

of omphalocele and epigastric heteropagus have been described.^[3,4] We report a novel approach for the repair of omphalocele using the gluteal skin flap available from the parasite.

CASE REPORT

A 2-day-old male was referred to us as a case of conjoined twins. The baby was a full-term normal vaginal delivery, first in birth order, born out of non-consanguineous marriage. The mother was 25 years old, not registered for antenatal care and with no antenatal ultrasound scans done.

On examination, there was an incomplete parasitic twin attached to the epigastrium of the auto-site with an omphalocele above. The parasitic twin had well-developed lower limbs, a penis with urethra, which was blind beyond its root, a poorly developed scrotum without testes and an anal dimple without an anal

Access this article online

Quick Response Code:



Website:

www.ijps.org

DOI:

10.4103/0970-0358.113731

opening [Figure 1]. The auto-site had an omphalocele, the contents of which were liver and intestine. No other obvious congenital anomalies were noticed. On auscultation, a pan systolic murmur was audible, and the second heart sound was loud.

On investigating, the haematological profile was normal. Radiographs showed normally developed bones in both lower limbs and pelvis of the parasite. 2D-echocardiography (2D-ECHO) revealed multiple cardiac anomalies (atrial septum defect [ASD], ventricular septum defect [VSD], patent ductus arteriosus [PDA], overriding of aorta, and peripheral pulmonic stenosis). Ultrasonography with Doppler showed the parasitic twin being supplied by a single vascular pedicle arising from the epigastric region. The omphalocele contained right lobe of liver and bowel loops. The patient was taken up for surgery after the complete work-up.

Operative management consisted of the removal of the parasitic twin and covering the omphalocele with the gluteal skin flap secured from the parasitic twin. The gluteal skin flap was based on the cutaneous branches of the superficial epigastric vessels of the auto-site and superior gluteal perforating artery of the parasite. During removal of the parasitic twin, a large section of skin and fat (flap) was raised by making an incision parallel to the iliac crest [Figures 2a and b]. The fat on the superolateral aspect of the flap was dissected down to the level of the deep fascia covering the gluteus maximus muscle. This flap was then used to cover the omphalocele of auto-site [Figure 3].

Post-operative course was uneventful, except for infection along the edges of the skin flaps, which was managed conservatively. Patient is asymptomatic after 6 months of follow-up.

DISCUSSION

Conjoined twins, is a rare congenital anomaly, seen in 1 in 50,000-100,000 live births.^[1] Asymmetrical conjoined twins refers to unequal and asymmetrical twinning, in which the dependent component (parasite) is smaller and attached to any portion of body of the dominant component (auto-site) or even within the body as a fetus-in-fetu. Epigastric heteropagus conjoined twins, a condition in which a parasitic twin is attached to the epigastrium of the auto-site, is extremely rare^[1-5] and only 44 cases have been previously reported in the world

literature.^[4]

Embryologically, epigastric heteropagus results from ischemic atrophy of one fetus at an early stage of gestation and selective atrophy of the cranial part of the parasite.^[3]

Epigastric conjoined twins are predominantly males. In epigastric heteropagus; the parasite has duplication of the pelvis and pelvic organs, such as the complete urinary

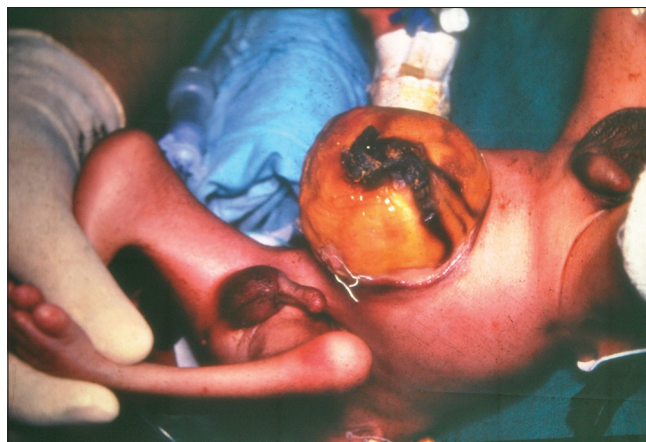

Figure 1: Epigastric heteropagus

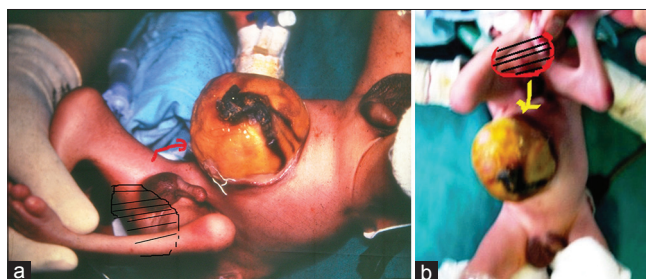


Figure 2: (a) Gluteal flap marked from the parasitic twin, (b) Gluteal flap marked from the parasitic twin

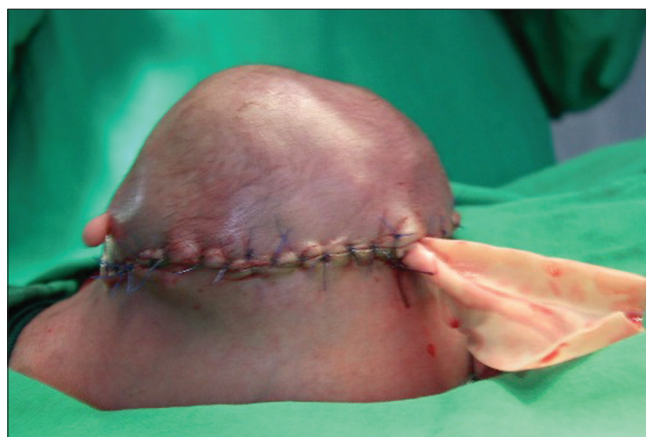

Figure 3: Post-operative outcome

tract, external and internal genitalia. Omphalocele is present in most of the cases.

Investigative work-up, apart from routine, consists of contrast enhanced computerized tomography (CECT), barium meal follow through, 2D-ECHO, and angiography. CECT is helpful to delineate the anatomy of the auto-site and parasite. Barium meal follow through is useful to evaluate any connection between the auto-site and the parasitic intestine. 2D-ECHO is performed to evaluate associated congenital heart disease. Common cardiac anomalies are PDA, VSD, and ASD.

In the literature, management of asymmetrical conjoined twins with omphalocele consists of primarily operative procedure or initial conservative management followed by operative procedure.^[1] The various surgical procedures described in the literature for management of Epigastric heteropagus with omphalocele are:

1. Excision of the parasite in the neonatal period and conservative management of the omphalocele (Using local applicants such as tincture benzoin, mercurochrome).^[6,7]
2. Surgical excision of the parasite and primary omphalocele repair that is a reduction of omphalocele contents and repair of the abdominal wall defect.^[8,9]
3. Surgical excision of the parasite in the neonatal period and delayed omphalocele repair using mesh (Ethicon VYPRO II).^[3] After extensive search in the literature, we have not found any report in which use of a flap has been made for repair of omphalocele, in case of epigastric heteropagus.

CONCLUSION

We report the 45th case of epigastric heteropagus twins and a novel surgical approach for the repair of omphalocele of the host by covering the omphalocele with gluteal skin flap secured from the parasitic twin.

REFERENCES

1. O'Neill JA Jr, Holcomb GW 3rd, Schnauffer L, Templeton JM Jr, Bishop HC, Ross AJ 3rd, *et al.* Surgical experience with thirteen conjoined twins. *Ann Surg* 1988;208:299-312.
2. Biswas SK, Gangopadhyay AN, Bhatia BD, Bandopadhyay D, Khanna S. An unusual case of heteropagus twinning. *J Pediatr Surg* 1992;27:96-7.
3. Xie JT, Zhou L, Yang ZL, Sun HY. Epigastric heteropagus conjoined twins: Two case studies and associated DNA analysis. *Clinics (Sao Paulo)* 2012;67:527-9.
4. Abubakar AM, Ahidjo A, Chinda JY, Tahir C, Abubakar S, Adamu SA, *et al.* The epigastric heteropagus conjoined twins. *J Pediatr Surg* 2011;46:417-20.
5. Bhansali M, Sharma DB, Raina VK. Epigastric heteropagus twins: 3 case reports with review of literature. *J Pediatr Surg* 2005;40:1204-8.
6. Chadha R, Bagga D, Dhar A, Mohta A, Malhotra CJ, Taneja SB. Epigastric heteropagus. *J Pediatr Surg* 1993;28:723-7.
7. Wadhera S, Singh S., Lahoti B.K., Rajkumar M.: Epigastric Heteropagus Twin: Our Experiences of two cases with review of literature. *The Internet J Surgery*. 2008;14. DOI: 10.5580/28c6.
8. Tongsin A, Niramis R, Rattanasuwan T. Epigastric heteropagus twins: A report of four cases. *J Med Assoc Thai* 2003;86:S605-9.
9. Raynal P, Petit T, Ravasse P, Herlicoviez M. A rare case of epigastric heteropagus twinning. *J Gynecol Obstet Biol Reprod (Paris)* 2001;30:65-9.

How to cite this article: Kesan K, Gupta A, Gupta RK, Kothari P, Ranjan R, Karkera P, *et al.* Gluteal flap for omphalocele repair in a case of epigastric heteropagus: A novel approach for surgical management. *Indian J Plast Surg* 2013;46:127-9.

Source of Support: Nil, **Conflict of Interest:** None declared.