

## Original Article

# Microvascular free flap reconstruction for head and neck cancer in a resource-constrained environment in rural India

Nirav P. Trivedi<sup>1,2</sup>, Pravin Trivedi<sup>1</sup>, Harish Trivedi<sup>1</sup>, Saroj Trivedi<sup>1</sup>, Nirali Trivedi<sup>1,2</sup>

Department of Plastic Surgery <sup>1</sup>Trivedi Polyclinic and Nursing Home, Mehsana, Gujarat, <sup>2</sup>Mazumdar Shaw Cancer Center and NH, Bangalore, India

### Address for correspondence:

Dr. Nirav P. Trivedi, Trivedi Polyclinic and Nursing Home, 1-A, Alka Society, Dairy Road, Mehsana - 384 002, Gujarat, India.  
E-mail: dr\_niravtrivedi@yahoo.com

## ABSTRACT

**Introduction:** Reconstruction with free flaps has significantly changed the outcome of patients with head and neck cancer. Microsurgery is still considered a specialised procedure and is not routinely performed in the resource-constrained environment of certain developing parts of India.

**Materials and Methods:** This article focuses on the practice environment in a cancer clinic in rural India. Availability of infrastructure, selection of the case, choice of flap, estimation of cost and complications associated with treatment are evaluated and the merits and demerits of such an approach are discussed. **Results:** We performed 22 cases of free flaps in a six-month period (2008-2009). Majority (17) of the patients had oral cancer. Seven were related to the tongue and eight to the buccal mucosa. Radial forearm free flap (RFF: 9) and anterolateral thigh flap (ALT: 9) were the most commonly used flaps. A fibula flap (1) was done for an anterior mandible defect, whereas a jejunum free flap (1) was done for a laryngopharyngectomy defect. There were six complications with two re-explorations but no loss of flaps. **Conclusion:** Reconstruction with microvascular free flaps is feasible in a resource-constrained setup with motivation and careful planning.

## KEY WORDS

Free flap; head and neck cancer; microvascular surgery; reconstruction; resource constrained; reconstruction of head and neck

## INTRODUCTION

Delivering optimum care for cancer in the community is a major challenge and outcomes can be variable.<sup>[1-3]</sup> Head and neck cancer is more

prevalent in developing countries and accounts for about one-third of all cancer cases.<sup>[4,5]</sup> It is more prevalent in rural India due to the use of known etiological factors like tobacco and alcohol.<sup>[6-11]</sup> In a large developing country like India, it may not be feasible to centralize treatment of cancer due to large numbers, logistics and associated costs.<sup>[1]</sup> Providing optimal care is difficult in the rural setting with limited resources, and hence many patients either may not receive treatment or receive suboptimal treatment, compromising the outcome.<sup>[12,13]</sup> Patients largely present at an advanced stage in rural India. Adequate resection would result in large complex defects that are difficult to reconstruct with conventional locoregional flaps. Inability

Access this article online	
Quick Response Code: 	Website: <a href="http://www.ijps.org">www.ijps.org</a>
	DOI: 10.4103/0970-0358.113715

to reconstruct such large defects is a limiting factor in offering these patients curative treatment.

Reconstruction with free flap provides an opportunity to treat these patients and improve their functional and cosmetic outcome. Microvascular reconstruction is still considered a specialised procedure that needs infrastructure, support services and a team approach in addition to surgical skills. It is difficult to have all these components in a centre in the resource-constrained environment of rural India. In this article, we share our experience of establishing a microvascular reconstruction unit in a clinic in rural India and demonstrate the feasibility of reconstruction with free flaps for head and neck cancer.

## MATERIALS AND METHODS

This article focuses on the practice environment in a cancer clinic in rural India. The authors are experienced in treating patients of head and neck cancer in a rural clinic since 1981. All patients with free flap reconstruction for head and neck cancer at the Trivedi Polyclinic and Nursing Home in Mehsana, Gujarat, India from September 2008 to February 2009 were included in this study. A retrospective chart review was done to evaluate relevant outcomes to demonstrate feasibility of this procedure in our setup. The main focus of this article is to concentrate on issues relating to:

- Availability of infrastructure
- Establishing a team
- Establishing a protocol
- Finances and logistics

that form the basis for establishing a microvascular unit in a resource-constrained setup.

## RESULTS

We performed 22 free flaps for reconstruction of the head and neck in a six-month period from September 2008 to February 2009. Details of these cases are shown in Table 1. Majority (17) of the patients had defects of the oral cavity. Seven patients had defects of the tongue, whereas eight patients had buccal mucosa defects. Radial forearm free flaps (RFF, 9) and anterolateral thigh (ALT, 9) flaps were the most commonly used free flaps.

RFF was the most common flap in the initial phase (first three months) of our practice [Figures 1 and 2]. Partial glossectomy defects were reconstructed in three cases

with RFF [Figure 2]. RFF is a very pliable flap and ideal for reconstruction of partial glossectomy with defects in the floor of the mouth. Total glossectomy defects are larger and requires larger skin island and more bulk; hence, ALT

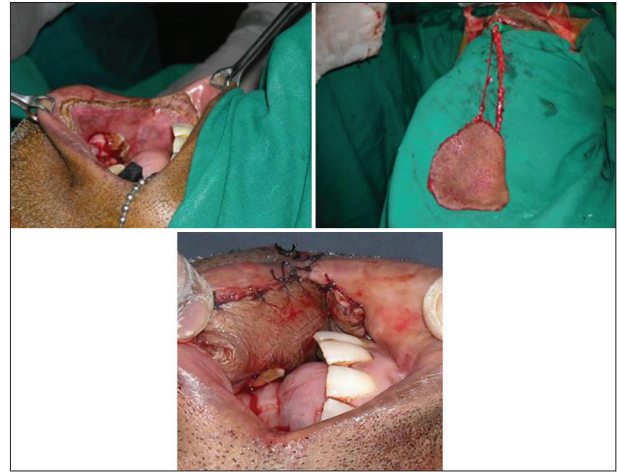


Figure 1: Reconstruction of myomucosal defect of the buccal mucosa with radial forearm free flap

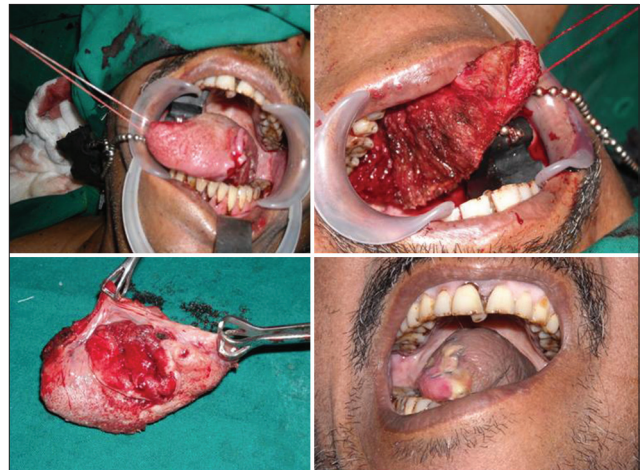


Figure 2: Partial glossectomy with radial forearm flap

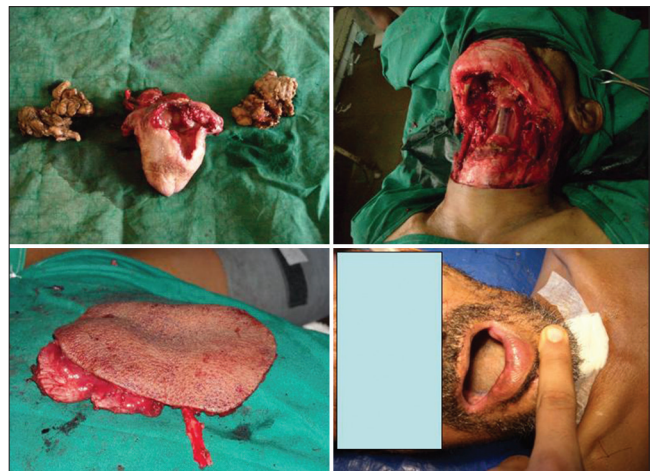

Figure 3: Total glossectomy with anterolateral thigh free flap

flap was preferred [Figure 3]. Myomucosal defects of the buccal mucosa were reconstructed by RFF flaps [Figure 1]. Small full-thickness defects of the buccal mucosa were reconstructed by RFF and larger defects required ALT flaps. Complex defects of the buccal mucosa with mandible and maxilla have a large soft tissue component. These defects were reconstructed only with soft tissue flaps if the anterior mandibular arch was preserved. ALT flaps were used in three such cases. One case of the anterior segment of the mandible was reconstructed using free fibula bone flap. Total maxillectomy defects were reconstructed by free rectus abdominis muscle flap. Partial maxillectomy defects were reconstructed by using RFF [Figure 4]. Jejunum free flap was used in one case of post-cricoid carcinoma where total laryngopharyngectomy (TLP) was performed [Figure 5].

Complications were seen in 6 (27%) cases [Table 1]. Re-exploration was done in two cases, one for haematoma evacuation and the other for venous thrombosis. The flap was salvaged without any further complications in both the instances. Two patients had wound infection. One patient with fibula flap reconstruction had exposure of the

plate after six months of completion of radiotherapy. The plate was removed through a small incision and his bone was viable at that time. In two cases of total glossectomy with ALT flap, the flap dehiscd at the soft palate area due to weight and the patient developed a salivary fistula which healed with conservative management. There was no loss of free flap in this series and none had any long-term morbidity.

Financial aspect of reconstruction with free flaps was also evaluated. The average operating time was approximately 11 hours (range: 9 to 15 hours). This was about five hours more than the time for the conventional procedure (reconstruction with locoregional flaps). The necessary medicines, sutures, instruments and other costs to perform reconstruction with free flaps added up to about an extra 10,000 Indian rupees (INR) [200 US dollars (USD)]. Hospital stay was increased by about 1-2 days compared to regional free flaps. In our experience, all the patients agreed to the extra charge of approximately 20,000 INR (400 USD).

## DISCUSSION

Clinicians working in this centre are experienced in treating head and neck cancer patients since 1981. For

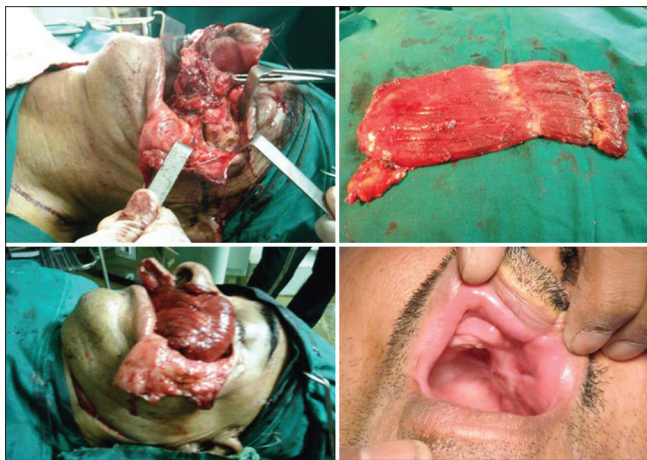

Figure 4: Total maxillectomy with rectus abdominis flap

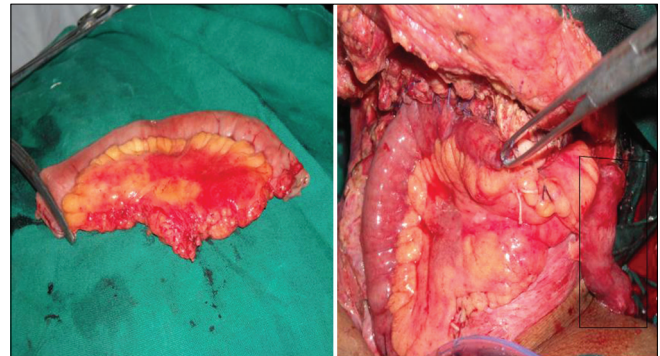


Figure 5: Total laryngopharyngectomy with jejunum free flap

Table 1: Subsite-wise distribution of cases, defect classification and choice of free flaps

Subsite	Defect (no.)	Free flap (no.)	Complication
Tongue	Partial glossectomy (3)	RFF (3)	-
Tongue	Total glossectomy (4)	ALT (4)	Flap dehiscence from soft palate (2)
Buccal mucosa	Myomucosal (2)	RFF (2)	-
Buccal mucosa	Full thickness (3)	ALT (2), RFF (1)	Haematoma (1)
Buccal mucosa	Complex mandible and maxilla (3)	ALT (3)	Re-exploration for venous thrombosis (1)
Mandible	Segment (1)	Fibula (1)	Plate exposure (1)
Mandible	Marginal (1)	RFF (1)	-
Maxilla	Partial (2)	RFF (2)	-
Maxilla	Total (2)	Rectus (2)	-
Larynx-pharynx	TLP (1)	Jejunum (1)	Wound infection (1)

TLP: Total laryngopharyngectomy, RFF: Radial forearm free flap, ALT: Anterolateral thigh

long, reconstruction options were limited to mainly local and regional flaps. This had been adequate in correcting the defect in many cases but inadequate in achieving satisfactory form and function. Pectoralis major myocutaneous flap and deltopectoral flap have been the workhorses for long but their limited reach and inability to reconstruct bone were the main limiting factors. The technique of reconstruction with microvascular free flaps increased the options for the reconstructive surgeon. Not only could larger defects be reconstructed, but improved functional and cosmetic outcomes were also achieved thus. Though these technique has been in practice for quite some time, it is being practised only in select centres across India. One needs special training, proper operating room setup, good postoperative support, surgical nursing and rehabilitative team to perform reconstruction with free flaps for an extended period of time.

We share our experience of establishing a microvascular reconstructive unit to explode the myth that reconstruction with free flaps cannot be performed in a rural area. The main focus of the discussion would be to demonstrate how we modified our practice approach to utilise the existing infrastructure to establish a microsurgery unit.

### **Availability of infrastructure**

It is perceived that microvascular reconstructive technique is a complex procedure and requires state-of-the-art facilities. We believe that it is definitely a procedure that demands technical precision but the infrastructure needed to carry out these procedures can be arranged even in a regular operative theatre. A proper cautery machine with monopolar and bipolar facility, a microscope that is used by otolaryngology [ear, nose and throat (ENT)] clinicians, a microinstrument set with a ligaclip applicator, a tourniquet and a drill machine are the basic requirements of any microsurgery unit. This is essentially a combination of a general surgery and ENT operation theatre that is available in most parts of our country. Anaesthesia facility should be organised for a long duration of ventilation (12-14 hours). We have a mechanical ventilator attached to our anaesthesia trolley that costs approximately 2,00,000 INR. The same machine can be used to provide basic ventilatory support in the postoperative ward in case of need. We have a policy to try and extubate the patient at the end of surgery. We perform elective tracheostomy for every case of reconstruction using free flaps. This approach helps in avoiding overnight ventilatory support and makes

reinduction simple in case re-exploration is needed.

It is also important to arrange for consumables and drugs that are necessary for these procedures. We have made arrangements with a couple of pharmacies in town that keep all necessary surgical consumables and drugs required for these procedures. It is also advisable to arrange adequate blood replacement prior to surgery.

### **Establishing a team and protocol**

It is probably the most important component of the microvascular unit. This procedure demands dedication, patience, sincerity and hard work. This is limited not only to the surgeon but also involves the anaesthetist and nursing staff. The operating procedure runs for long hours and possibility of re-exploration cannot be ruled out for up to 4-5 days. It is essential to ensure availability of all the team members for a few days before scheduling the operation. As a policy, we do not post any operative case on the day after the microsurgery. This enables us to recover from long operative hours and also provides an opportunity for timely re-exploration. It is advisable to have two surgeons with the ability to perform microanastomosis, but currently only one surgeon can perform this procedure in our group. We also have a microinstrument set reserved for re-exploration.

It is essential to establish protocols for every minute thing from the operative setup to postoperative care from the initial phase itself. This helps in training the staff as well ensures consistency in clinical care. This is also very helpful in case of re-exploration where everyone is tired and resources are stretched in a small setup. It is advisable to select relatively simpler cases to start with and then move on to more complex cases when you become more confident about your setup and team.

The anaesthetist serves as the captain in our team. She schedules cases after evaluating availability of the staff for the case and for the postoperative period. She does the postoperative monitoring of patient on the night of the surgery. All our patients have tracheostomy, and airway management is essentially tracheal suction and oxygenation which is taken care of by trained staff. Monitoring of flaps is an essential part of postoperative care and the nursing staff is trained to monitor flaps every hourly with needle scratch. The operating surgeon also stays back in the hospital to evaluate the flaps once every 2-3 hours. The majority of problems with flaps is observed in the initial few hours of the surgery

and further monitoring of flaps is done by trained staff every two hours for 4-5 days. It is essential to watch for postoperative haematoma and flap oedema and its effect on venous drainage. We have developed protocols for re-exploration and routine postoperative care which are pasted in the ward and in the theatre. Every staff in the theatre is trained to follow the protocol in case of re-exploration (from instrument trolley and requirement of anaesthesia to preparation of the theatre). The ward staff is trained for postoperative care (avoiding neck strap for tracheostomy, ensuring a relatively stable neck position to avoid kinking of vessel and aggressive chest physiotherapy to avoid pneumonia). The anaesthetist observes the entire process till the patient is stable in the ward. We have a full-time anaesthetist working at our place but a team of anaesthetists performing alternative duties can also solve the problem. Special efforts were required in the initial few cases but now the team is well trained and feels comfortable with the entire process. The commitment and dedication of the entire unit is the single most important factor for the success of a microsurgical unit especially in remote setups.

### Finance

The approximate additional costs for performing a microvascular procedure are INR 10,000 in our setup. This includes the charge of the operation theatre and cost of consumables and drugs. Essentially, we use microsuture materials and a few extra hours of operative time. None of the patients in our setup has refused the procedure due to financial reasons.

### Social and logistical factors

The treatment for head and neck cancer is a complex and lengthy one. It is difficult for patients from smaller towns and villages to identify the optimum setup for their treatment in metros. They have financial, logistical and social issues that make treatment compliance poor. This problem can be solved by providing optimum treatment in smaller towns. The majority of our patient in this series would not have received reconstruction using free flaps in major cities due to various reasons. It is essential to take this specialty to the larger population in our country as it has the potential to influence many lives in all surgical branches. Our experience suggests that it is just a myth that reconstruction with microvascular free flaps requires a special setup and is difficult in routine clinical practice.

## CONCLUSION

It is feasible to perform reconstruction with microvascular free flaps in resource-constrained rural India. It is essential to establish a team that is dedicated and motivated to provide the necessary efforts. The infrastructure required to perform microsurgery can be easily arranged anywhere and careful planning is essential to carry out these procedures in a satisfactory way. Our results demonstrate that it is a misleading fact that microsurgery cannot be performed in a rural setup. This procedure has the potential to help many patients in our country.

## REFERENCES

1. Sanabria A, Domenge C, D'cruz A, Kowalski LP. Organ preservation protocols in developing countries. *Curr Opin Otolaryngol Head Neck Surg* 2010;18:83-8.
2. Rothwell PM. Factors that can affect the external validity of randomized controlled trials. *PLoS Clin Trials* 2006;1:e9.
3. Rothwell PM. External validity of randomised controlled trials: 'To whom do the results of this trial apply?'. *Lancet* 2005;365:82-93.
4. Sankaranarayanan R, Masuyer E, Swaminathan R, Ferlay J, Whelan S. Head and neck cancer: A global perspective on epidemiology and prognosis. *Anticancer Res* 1998;18:4779-86.
5. Sanghvi LD, Rao DN, Joshi S. Epidemiology of head and neck cancer. *Semin Surg Oncol* 1989;5:305-9.
6. Jayalekshmi PA, Gangadharan P, Akiba S, Nair RR, Tsuji M, Rajan B. Tobacco chewing and female oral cavity cancer risk in Karunagappally cohort, India. *Br J Cancer* 2009;100:848-52.
7. Hashibe M, Jacob BJ, Thomas G, Ramadas K, Mathew B, Sankaranarayanan R, *et al.* Socioeconomic status, lifestyle factors and oral premalignant lesions. *Oral Oncol* 2003;9:664-71.
8. Reddy SK, Gupta PC. Report on tobacco Control in India. Ministry of Health and Family Welfare, Government of India: New Delhi; 2004.
9. Chen WQ. Estimation of cancer incidence and mortality in China in 2004-2005. *Zhonghua Zhong Liu Za Zhi* 2009;31:664-8.
10. Arsenijevic S, Pantovic V, Gledovic Z, Stojanovic J, Belic B. Demographic characteristics of patients with laryngeal cancer and their socioeconomic status. *J BUON* 2010;15:131-5.
11. Elango JK, Gangadharan P, Sumithra S, Kuriakose MA. Trends of head and neck cancers in urban and rural India. *Asian Pac J Cancer Prev* 2006;7:108-12.
12. Allareddy V, Konety BR. Characteristics of patients and predictors of in-hospital mortality after hospitalization for head and neck cancers. *Cancer* 2006;106:2382-8.
13. Hillner BE, Smith TJ, Desch CE. Hospital and physician volume or specialization and outcomes in cancer treatment: Importance in quality of cancer care. *J Clin Oncol* 2000;18:2327-40.

**How to cite this article:** Trivedi NP, Trivedi P, Trivedi H, Trivedi S, Trivedi N. Microvascular free flap reconstruction for head and neck cancer in a resource-constrained environment in rural India. *Indian J Plast Surg* 2013;46:82-6.

**Source of Support:** Nil, **Conflict of Interest:** None declared.