

Review Article

Abnormal pigmentation within cutaneous scars: A complication of wound healing

Sarah Chadwick^{1,2}, Rebecca Heath¹, Mamta Shah^{1,2}

¹Faculty of Life Sciences, University of Manchester, ²Department of Burns and Plastic Surgery, Royal Manchester Children's Hospital, Central Manchester University Hospitals NHS Foundation Trust, UK

Address for correspondence: Dr. Mamta Shah, Burns Service, Royal Manchester Children's Hospital, Oxford Road, Manchester - M13 9PT. UK. E-mail: mamta.shah@cmft.nhs.uk

ABSTRACT

Abnormally pigmented scars are an undesirable consequence of cutaneous wound healing and are a complication every single individual worldwide is at risk of. They present a challenge for clinicians, as there are currently no definitive treatment options available, and render scars much more noticeable making them highly distressing for patients. Despite extensive research into both wound healing and the pigment cell, there remains a scarcity of knowledge surrounding the repigmentation of cutaneous scars. Pigment production is complex and under the control of many extrinsic and intrinsic factors and patterns of scar repigmentation are unpredictable. This article gives an overview of human skin pigmentation, repigmentation following wounding and current treatment options.

KEY WORDS

Melanin; melanogenesis; pigmentation; scar(s); wound

INTRODUCTION

The management of cutaneous injury and scarring has long been a problem for plastic surgeons.^[1] Disruption to normal melanogenesis within wounded skin will result in dyspigmentation in the resulting scars^[2] rendering even flat, matt and supple scars more noticeable. This can have devastating consequences for those affected, leading to social embarrassment and even isolation for some.^[3,4] The scale of the problem is huge; every single individual worldwide is at risk of cutaneous injury and abnormal pigmentation within the resulting scars.

Human skin pigmentation

It is readily apparent there is a vast spectrum of skin colour within the human race, borne from years of population migration and evolutionary change.^[5] Multiple factors influence skin pigmentation including environment, weather, clothing choice and trends such as skin tanning or bleaching. Even today humans modulate their skin colour to fit in with society's perceived demands.

Although local blood supply and pigments such as bile and carotene can contribute to skin tone, the main determinant of human skin colour is melanin. This pigmented biopolymer is produced through a process called melanogenesis, by melanocytes. Melanocytes are dendritic cells which migrate from the neural crest during embryogenesis to become resident, in the skin, in the basal layer of the epidermis.

Melanin is produced within specialised intra-melanocytic organelles called melanosomes, which exist in four

Access this article online

Quick Response Code:



Website:

www.ijps.org

DOI:

10.4103/0970-0358.101328

distinct stages within the melanocyte cytoplasm [Figure 1]. Pigment is transferred within melanosomes to neighbouring keratinocytes which distribute melanin into the upper layers of the skin. Within keratinocytes, melanin localises to the sun-bearing side of the keratinocyte nucleus and acts as a physical barrier, protecting the nuclear tissue from harmful solar ultraviolet radiation (UVR) before itself being degraded.^[6]

'Normal' melanogenesis results in the production of two types of melanin; eumelanin, a brown-black pigment found in higher ratios in darker skin types and those chronically exposed to UVR, and phaeomelanin a red-brown pigment found in people with fair skin types.

Melanogenesis is dependent on an amino-acid substrate, tyrosine, which is hydroxylated to L-3,4-dihydroxyphenylalanine (DOPA) by a key enzyme, tyrosinase [Figure 2]. DOPA is oxidised to DOPAquinone and, in the presence of a cysteine group, phaeomelanin is produced. Eumelanin production requires the actions of two further enzymes: tyrosinase-related protein 1 (TRP1) and 2 (TRP2/Dct) which rearrange DOPAchrome (produced from the spontaneous cyclic oxidation of DOPAquinone) to form DHI-2-carboxylic acid (DHICA).^[7] The two pigments differ not only in their colour. Phaeomelanin produces higher levels of free radicals in response to UVR, potentially leading to increased DNA damage, skin malignancy and other skin diseases including sunburn.^[8]

Interestingly, it is not the number of melanocytes within the epidermis that influences skin pigmentation, but

rather the cells' activity. In the 1950's qualitative and quantitative human pigment cell studies revealed little difference in melanocyte number between black and white skinned individuals. There were differences, however, *within* the same individual with highest numbers of melanocytes in the head, neck, limbs and genitalia and lowest numbers on the chest and abdomen.^[9] Later studies noted that despite white skin having equal (and sometimes higher) tyrosinase levels than black skin, the pigmentation was obviously very different.^[10] It was hypothesised that pigment cells in the white skin were less active than those in black skin, despite both skin types having adequate tyrosinase levels for melanogenesis. The key seemed to be melanosomal pH as for successful melanogenesis, tyrosinase activity is required to oxidise tyrosine to DOPA. In black skin, melanosomal pH is near neutral and so optimal for this reaction. By contrast, melanosomal pH in white skin is lower, inadequate for enzymatic activity, and therefore preventing downstream melanogenesis and melanin production.

Control of melanogenesis

The regulation of all stages of melanocyte development through to pigment production is highly complex, and under the control of at least 250 genes^[7] and a number of cell types. In 1963 the term 'epidermal-melanin unit' was introduced to group melanocytes and keratinocytes together in terms of their function, due to their co-dependent relationship in pigment production and distribution.^[11] Later, this relationship was extended to include fibroblasts, as their role in production of factors regulating melanogenesis became more apparent.^[12]

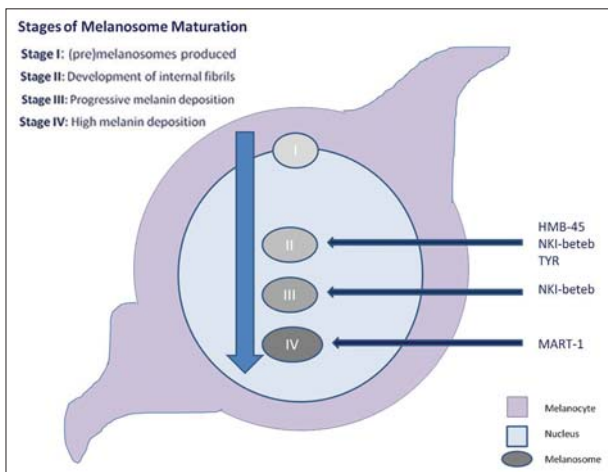


Figure 1: Stages of melanosomal maturation. Melanosomes exist in four distinct stages as they become increasingly laden with melanin pigment prior to transport out of the cell into neighbouring keratinocytes via melanocyte dendrites. Histochemical markers which identify melanosomes at varying stages of development are useful in the diagnosis of melanocytic lesions

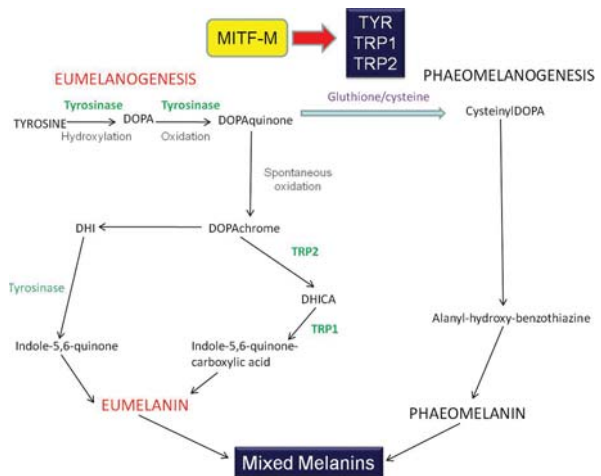


Figure 2: Melanogenesis is a complex process under the control of many genes. Key steps are activation of MITF-M, which leads to downstream activation of essential enzymes Tyrosinase, TRP1 and TRP2

The most well known extrinsic factor regulating melanogenesis is ultraviolet radiation (UVR). UVR upregulates the pro-opiomelanocortins alpha-melanocyte stimulating hormone (α -MSH) and Adrenocorticotrophic hormone (ACTH), which in turn activate transcription of the melanogenic master regulator Melanocortin-1 receptor (MC1R).^[13] This activates the melanogenesis pathway, with the net effect of melanin pigment production...and a suntan!

UVR causes DNA damage, which is recognised by a family of DNA repair proteins that excise the damaged segment of DNA and using DNA polymerases repair the strand using the complementary base pairs as a template.^[14]

Other extrinsic factors, such as drugs, tanning lotions and bleaching creams can all affect pigmentation, the effects of which can be exacerbated following exposure to UVR [Table 1].

Lasers have become more widely used in surgical practice as their safety and efficacy have improved. However, an unfortunate side effect of laser therapy is dyspigmentation in the target area. An expert

Table 1 : Iatrogenic causes of abnormal skin pigmentation (adapted from^[15])

Agent	Clinical features	Affected by sunlight?
Psychotropics e.g., Phenothiazines (Chlorpromazine)	Purple discolouration of face, nailbed and exposed areas of eye with skin creases spared	Yes
Tricyclic antidepressants (Imipramine)	Blue or slate-grey skin	Yes
Antimalarials e.g. chloroquine	Blue-purple macules on lower legs and facial skin and oral mucosa	Yes
Chemotherapeutics e.g. Bleomycin	Photosensitivity Diffuse hyperpigmentation	Varies
Amiodarone	Blue-grey discolouration sun-exposed skin Yellow discolouration of cornea	Yes
Silver	Grey-blue discolouration localized to areas of contact	Yes
Gold	Blue-grey increased pigmentation of sun-exposed areas	Yes
Mercury	Slate grey discolouration to areas of skin which have received contact with mercury	No

review of the complications of laser skin surgery highlighted the problem of dermal and epidermal injury, secondary to the dissemination of heat from the laser, which may lead to burn injuries especially when deeper cutaneous lesions are targeted.^[16] Advances in cooling techniques have improved this, but caution must be undertaken and any instant skin whitening must be avoided as this is a sign of thermal injury which may lead to hypopigmentation.^[16] Caution must also be exercised when using laser therapy on darker skin types as increased levels of melanin within the epidermis reduces the laser dosage reaching the target lesion. Higher fluences are therefore needed, which can inadvertently cause thermal injury and activation or destruction of melanocytes, leading to dyspigmentation.^[17]

Intrinsically there are a multitude of factors which regulate melanocyte growth and differentiation and the process of melanogenesis [Figure 3].

Although black and white skin contains almost equal numbers of melanocytes and melanosomes the cells do differ in terms of structure and function. As melanosomes mature, they develop a more complex internal fibrillar scaffold upon which melanin pigment deposits. Stage I and II lightly pigmented melanosomes are found in higher ratios in people with paler skin types and more densely laden, pigmented stage III and IV melanosomes in higher ratios in people with darker skin types. Melanocytes within black skin are also larger and more dendritic than those of white skin.^[9]

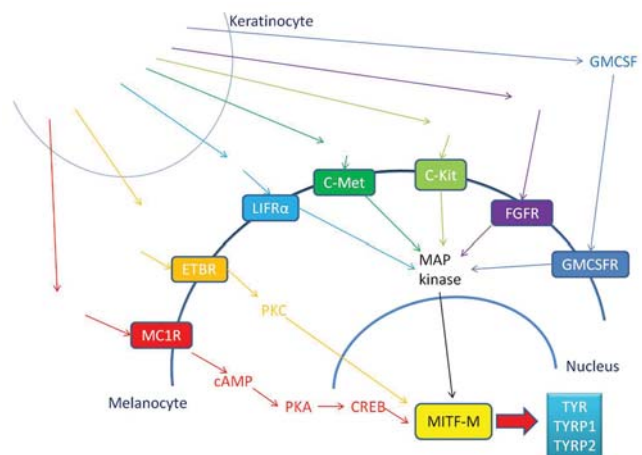


Figure 3: Intrinsic regulation of melanogenesis. Melanogenesis is under the control of multiple extrinsic factors, from a variety of cell types. Communication between these cell types is essential for successful melanin production (Adapted from^[9])

Other roles of melanocytes

Melanocytes are derived from the neural crest and migrate during embryogenesis, crossing the basement membrane to reside, in the skin, in the basal epidermis. Their origin as neural crest cells opens the possibility they may possess other roles in addition to merely producing melanin as protection from UVR. Plonka *et al.*'s 2009 review raises multiple questions about the true function of melanocytes^[12] from immune-modulatory cells, to endocrine and antimicrobial effectors. The melanocyte as an anti-inflammatory cell has also been investigated and recent work has shown melanocytes to act as free radical scavengers, possibly acting as anti-inflammatory cells to reduce oxidative damage.^[18] Within a wound, it may be expected that melanocytes would be one of the first cells to repopulate the damaged area, to reduce oxidative damage as part of the initial wound healing response. By contrast, melanocytes seem to enter the wound later, once it has re-epithelialised and the reason for this delay is currently unclear (Own observations^[19]).

Dyspigmentation after wound healing: The problem

Abnormal pigmentation renders scars more noticeable [Figures 4a and b] and this can cause serious adverse sequelae for those affected. People can find their scars aesthetically displeasing leading to profound psychological implications for some.^[3,4] Within certain cultures where abnormally pigmented scars are socially unacceptable, those affected may be forced into social exclusion and isolation.

As well as being aesthetically undesirable, hypopigmented scars lack melanin leaving them without protection against ultraviolet radiation (UVR). This potentially puts the individual at increased risk of UVR-related skin damage including skin malignancy and sunburn. Importantly for

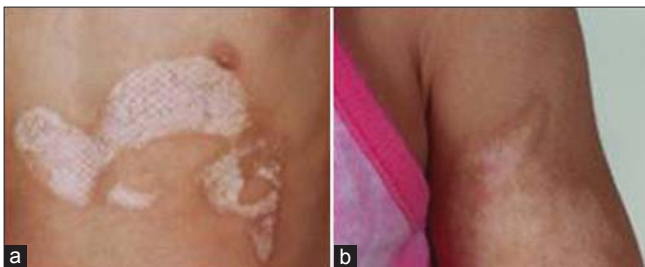

Figure 4: (a) Abnormal pigmentation within scars renders even flat, matt and supple scars more noticeable. The central hypopigmentation and peripheral hyperpigmentation can be clearly seen in this child's postburn scar (b) Abnormalities in pigmentation following injury are more pronounced in people with darker skin types. This child's postburn scar is centrally hypopigmented and peripherally hyperpigmented, making the scar highly noticeable against the surrounding unwounded skin

clinicians, a huge problem with scar dyspigmentation is the current lack of proven treatment options which permanently and completely abolish this complication of wound healing.

Wound healing and abnormal pigmentation

Despite extensive research into both pigment cells and wound healing, there remains a scarcity of knowledge around the repigmentation of scars following cutaneous injury. One of the earliest studies into wound repigmentation investigated the epithelial repair of partial thickness wounds in guinea pigs.^[20] This study demonstrated wound healing by advancement of neoepithelium from the wound edges and residual hair follicles in the wound bed. Snell, in 1960, had similar findings although his study into repigmentation of deep wounds (also in guinea pigs), observed re-epithelialisation from the wound edges alone.^[21] Until this point, both authors demonstrated melanocytes travelling with the neoepithelium across the wound. However, in 1963, Breathnach was unable to identify any melanocytes in the centre of healed mid-dermal human wounds, contrasting with the findings of the previous authors and leading him to believe that melanocytes migrated into a wound after it had fully re-epithelialised.^[19] More recent studies have also had contrasting views; Hirobe in 1983 was unable to demonstrate melanocytes at the centre of a healing wound in a murine model,^[22] but most recent work from our laboratory identified melanocytes in human burn wounds travelling with the neoepithelium only lagging behind the leading edge by 2-3 mm.^[23] Currently unpublished work from our laboratory has also identified differences in the repigmentation of scars depending on the depth and width of the wound (Chadwick *et al.*, under review). It is likely the repigmentation of scars will depend on the availability of melanocytes and this will depend on the mechanism of injury; in partial thickness injuries the wound bed will contain residual adnexal elements which will be able to provide melanocytes and epithelial cells to the neoepithelium. However, in deep injuries in which all adnexal elements have been removed or destroyed by the wounding process, the only available source for melanocytes will be the wound edges. These wounds will take longer to heal and will heal with a hypopigmented centre in contrast to the surrounding unwounded skin (own observations).

The presence of hair follicles in the wound bed is also potentially important to the successful repigmentation of a scar. Human hair follicles contain 5-6 separate areas with the capacity to provide pigment cells and, most

importantly, a melanocyte stem cell reservoir in the bulge region of the hair follicle [Figure 5].^[24] Melanocyte stem cells have been observed in healing wounds for a number of years. In early work ‘amelanotic melanocytes’ were noted migrating into wounds as they healed, but the true identity of these cells was unknown, believed to be ‘exhausted’ or ‘dead’ melanocytes.^[19,25] It is now known these cells are melanocyte stem cells which possess the ability to contribute both to epidermal homeostasis and cutaneous wound healing.^[26] The ‘bulge cells’ rapidly migrate following injury to re-epithelialise the defect and repopulate the damaged epidermis.

Repigmentation of a scar from hair follicle melanocytes is dependent on the stage of the hair follicle cycle at the time of wounding. Hair follicle melanocytes actively undergo melanogenesis during the Anagen phase of the hair cycle, but by contrast epidermal melanocytes continuously undergo melanogenesis whilst adapting to fluctuations in intrinsic or extrinsic influences, such as UVR.^[24] Injuries within hair-bearing skin, which retain the melanocyte stem cell reservoir, are more likely to repigment than those wounds in which this important source of melanocytes is destroyed by the wounding process. Most recently, dermis-derived stem cells have also been shown to migrate to the basal epidermis and differentiate into functioning melanocytes.^[27] This could also have implications on repigmentation after injury, as successful repigmentation may not only depend on the survival of melanocyte stem cells within the hair follicle, but also survival of dermal stem cells with the ability to migrate and differentiate into basal melanocytes.

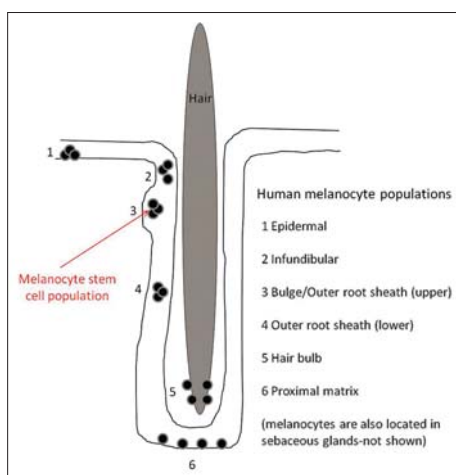


Figure 5: Melanocyte populations within the human hair follicle. There are multiple sites within the human hair follicle capable of producing melanocytes. The most important of these, the æbulgeæ region, houses the melanocyte stem cell reservoir

Both hypo and hyperpigmentation can pose difficult and persistent problems. Hyperpigmentation as a complication of skin grafting has been encountered by many surgeons and is a further area in which research is scarce. Histological studies investigating pigmentation of meshed human skin grafted onto athymic nude mice, noted hyperpigmentation in the grafts shortly after the appearance of melanocytes within the wound, and after melanocytes began to actively undergo melanogenesis.^[28] However, hyperpigmentation has commonly been attributed to effects of the inflammatory response.

INFLAMMATION AND PIGMENTATION

Cutaneous injuries invoke an inflammatory response and many important cellular mediators in this response influence melanocytes and melanogenesis in a variety of ways. Nitric oxide (NO), released by cells immediately following wounding, is required for recruitment of leucocytes to the site of injury. It is an important intra and intercellular messenger and upregulated in the presence of UVR^[8] leading to stimulation of melanogenesis in human melanocytes. UV-induced melanogenesis can also be inhibited by NO synthetase inhibitors.^[29] Histamine is released by mast cells at the site of injury, and along with NO enhances eumelanogenesis when upregulated by UVR. When histamine is antagonized by application of a H₂-receptor antagonist, there is downregulation of UVR-mediated pigmentation.^[8] Another protein vital to the cellular response to injury is p53 and this has also been shown to have a role in the UV-mediated tanning response, directly controlling UV induction of the POMC/αMSH pathway in skin.^[30] Through similar mechanisms p53 may also have a role in non-UV-mediated skin damage, for example following chemically induced DNA damage or in oncological processes.

Transforming growth factor β1 (TGF-β1) is released by platelets and is imperative in wound healing.^[31] It inhibits melanocyte growth through suppression of PAX3, a gene which synergistically with SOX10 increases MITF-M expression, in turn inducing pigment gene expression.^[32] Interestingly, however, UVR can downregulate TGF-β1, lifting its inhibitory effects on PAX3 and allowing MITF-M transcription and pigment gene expression.

The phenomenon of postinflammatory hyperpigmentation can be seen readily in clinical practice, observed as wounds darken as they are healing, and this can be a problem which

Table 2: Options for treatment of dyspigmented scars

Method	Mechanism	Advantages	Disadvantages	References
Conservative Tanning lotions	Contain dihydroxyacetone which produces brown discolouration on contact with skin	Short-term Nontoxic Inexpensive, Widely available Self-application	Nonpermanent Difficult to achieve good colour match Allergic reaction	[44]
Bleaching creams	Variety of active ingredients including: hydroquinone, mercury, glucocorticoids Exact mechanism unknown. Potentially: 1. Alter melanosomal formation and melanin loading 2. Alter coppers at tyrosinase's active site preventing melanogenesis 3. Inhibit cellular DNA and RNA synthesis	Noninvasive Inexpensive, Widely available Self-application	Nonpermanent Allergic reactions and dermatitis Infectious skin diseases	[45] [37]
Cosmetic camouflage	Often available through Occupational Therapy departments, involves application of make-up to correct colour mismatch and contour deformities	Widely available Inexpensive Noninvasive	Nonpermanent Allergic reactions Technician dependent	(Own observations)
Invasive Tattooing	Insertion of indelible inks or dyes into the dermis of the skin using a needle	Widely available Safe (when through reputable operator)	Invasive, painful May require multiple treatments Skin infections Nonpermanent; may fade over time, pigment may be engulfed by macrophages	[36] [46]
Laser therapy	<i>Hyperpigmentation</i> : Laser targets melanosomes within melanocytes and destroys the organelles through heat or shock wave effect <i>Hypopigmentation</i> : Laser activates dormant melanocytes within the hair follicles	1 year follow-up shows good results in some cases May be used for hypo and hyperpigmentation Can target treatment area	Painful and invasive; may require general anaesthesia in paediatric patients Multiple treatments over several months may be needed	[47]
Cultured melanocyte transplantation	Cultured melanocytes transplanted onto wound beds (prepared by excision / dermabrasion) and proliferate alongside keratinocytes in the neoepithelium	Success using <i>in vitro</i> models and in vitiligo lesions	Little data currently for nonvitiligo use Time lag due to melanocyte culture	[41]
Noncultured melanocyte transplantation	Application of noncultured melanocytes (and keratinocytes) to wound bed from an adjacent area of normally pigmented skin	More rapid availability of melanocytes and keratinocytes	Severe hypo and hyperpigmentation at donor sites May be dependent upon skin types (Less effective in Fitzpatrick skin types I and II) Successful repigmentation inconsistent at 1 year follow-up Little data for non stable vitiligo use	[48]
Surgical excision ± split skin grafting	Affected area surgically excised and closed directly (gold standard) or with a split thickness skin graft	Removes all affected skin	May encounter further dyspigmentation in 'new' scars and skin graft donor sites Colour mismatch in split skin graft	[49]

persists for some time after injury. Postinflammatory hyperpigmentation may occur after a variety of cutaneous insults such as infection, acne and cutaneous trauma, and

leaves the affected individual with a scar which is darker than the surrounding unaffected skin. The mechanisms behind this are not fully understood but may involve

activation of melanocytes by inflammatory mediators or reactive oxidative species released by damaged skin.^[33] Additional melanin is produced in the response to injury and this is engulfed by macrophages also involved in the inflammatory response. The macrophages then retain the melanin in the dermis until the cells and melanin are degraded, enabling the pigment to persist within the dermis for some time postinjury. Although this may offer some additional protection from UVR, increased and prolonged activation of melanogenesis within these lesions may lead to uncontrolled proliferation and melanoma.^[34]

Management of dyspigmentation

As with any complication, prevention is better than cure. It is known that complications such as increased time to healing and wound infection increase the risk of poor quality scarring, so efforts should be made to rapidly treat these problems as they arise.^[35] Identifying at risk individuals and moderating treatment accordingly may minimize the extent to which these people scar badly. For those who require treatment for their dyspigmented scars, there are a range of management options available, but none which completely and permanently abolish the problem [Table 2].

Noninvasive treatments

Camouflage make-up is a simple treatment which carries minimal risks for the patient. Make-up is blended with the person's normal skin colour and applied to the scarred areas to conceal them.^[1,36] Results are operator dependent and nonpermanent but may offer an acceptable solution for some individuals.

More readily available are skin tanning and bleaching lotions. These offer a quick, cheap method of altering skin tone but are not without complications. Skin tanning lotions contain dihydroxyacetone (DCA), a compound incidentally discovered to cause skin discolouration when children treated with it for glycogen storage disorders developed brown patches on their skin. Bleaching creams usually contain compounds such as mercury, hydroquinone or glucocorticoids. The exact mechanism through which these have a depigmenting effect is unknown, but thought to act either by inactivating tyrosinase by altering copper at its active site, or through inhibition of cellular DNA or RNA synthesis.^[37,38] Both mechanisms ultimately prevent melanogenesis. Topical treatments which either darken or lighten skin pigmentation both carry risks of allergic reaction and minor skin irritation, but in addition,

bleaching creams can cause extensive dermatitis, infectious skin diseases and acne.^[39]

Invasive treatments

Laser therapy has been proven to be effective in hypo and hyperpigmented lesions and allows a specific and targeted approach to problem areas. In hypopigmented lesions the laser activates melanosomes within the affected site and stimulates them to increase pigment production. In hyperpigmented lesions, melanosomes are destroyed by the laser, preventing further melanogenesis and melanin transfer.^[38] This does carry the unfortunate potential side effect of stimulating melanin production, worsening the problem. Laser therapy can achieve good results, but may require multiple treatments, particularly if large surface areas are affected. It can also be a painful procedure, possibly requiring general anaesthesia in paediatric patients.

Tattooing is an ancient practice and involves inserting permanent dyes or inks into the dermis of the skin to alter skin colour.^[40] This is an option which is readily available on the high street but is highly operator dependant. People can choose to have skin matching tattooing done in which the dyes are matched to their skin tone to conceal their scars, but some opt to cover their scars with decorative tattoos. With safe and aseptic technique by skilled artists, tattooing carries minimal risks; local skin irritation and superficial infection or allergic reactions are the most likely complications. Over time, dyes may fade and repeated treatments may be required. Unfortunately, tattooing produces a permanent change in skin colour and the affected scar cannot alter with temperature variations or sun exposure which often worsens the problem by highlighting the tattooed areas!

The gold standard of treatment for scar dyspigmentation is surgical excision and, if the size and site of the defect allows, direct closure. This completely removes the affected area and minimizes the new scarring created to close the defect. However, many areas of abnormal pigmentation will be too large to be closed directly and may require other techniques to cover the defect.

Alternatives to complete surgical excision for hypopigmented lesions are dermabrasion of the affected area and application of cultured or noncultured melanocytes. This approach has been used with good effect in hypopigmentation arising from vitiligo but little work has been carried out with cutaneous injuries and

the resulting abnormally pigmented scars.^[41] Often the injury sustained will have damaged the skin's adnexal elements, such as sebaceous glands and hair follicles. The behaviour of cultured or indeed noncultured melanocytes is unpredictable and may require multiple interventions.^[42,43]

SUMMARY

Despite extensive pigment cell research the melanocyte remains a mysterious cell with multiple roles controlled by numerous interlinking factors. Work to understand the repigmentation of scars following injury is ongoing, but to date, preservation of stem cells with the capability to differentiate into melanocytes seems key to the successful repigmentation of a scar postinjury. Likely factors affecting this are the type of injury sustained, as full-thickness injuries, which destroy all adnexal elements within the skin also destroy potential sources of melanocytes. Treatment options currently offer no definitive solution, but the gold standard remains surgical excision of the affected area and direct closure of the defect. Efforts to promote rapid wound healing and minimize the inflammatory response within the wound may prevent abnormalities of pigmentation within the resulting scar.

REFERENCES

- Morgan JE, Gilchrist B, Goldwyn RM. Skin pigmentation. Current concepts and relevance to plastic surgery. *Plast Reconstr Surg* 1975;56:617-28.
- Tyack ZF, Pegg S, Ziviani J. Postburn dyspigmentation: its assessment, management, and relationship to scarring—a review of the literature. *J Burn Care Rehabil* 1997;18:435-40.
- Wisely JA, Hoyle E, Tarrier N, Edwards J. Where to start? Attempting to meet the psychological needs of burned patients. *Burns* 2007;33:736-46.
- Zeitlin RE. Long-term psychosocial sequelae of paediatric burns. *Burns* 1997;23:467-72.
- Jablonski NG. The Evolution of Human Skin and Skin Color. *Annu Rev Anthropol* 2004;33:585-623.
- An SM, Koh JS, Boo YC. Inhibition of melanogenesis by tyrosinase siRNA in human melanocytes. *BMB Rep* 2009;42:178-83.
- Hearing VJ. Milestones in melanocytes/melanogenesis. *J Invest Dermatol* 2011;131:E1.
- Lassalle MW, Igarashi S, Sasaki M, Wakamatsu K, Ito S, Horikoshi T. Effects of melanogenesis-inducing nitric oxide and histamine on the production of eumelanin and pheomelanin in cultured human melanocytes. *Pigment Cell Res* 2003;16:81-4.
- Staricco RJ, Pinkus H. Quantitative and qualitative data on the pigment cells of adult human epidermis. *J Invest Dermatol* 1957;28:33-45.
- Iozumi K, Hoganson GE, Pennella R, Everett MA, Fuller BB. Role of tyrosinase as the determinant of pigmentation in cultured human melanocytes. *J Invest Dermatol* 1993;100:806-11.
- Fitzpatrick TB, Breathnach AS. The epidermal melanin unit system. *Dermatol Wochenschr* 1963;147:481-9.
- Plonka PM, Passeron T, Brenner M, Tobin DJ, Shibahara S, Thomas A, *et al.* What are melanocytes really doing all day long? *Exp Dermatol* 2009;18:799-819.
- Abdel-Malek Z, Scott MC, Suzuki I, Tada A, Im S, Lamoreux L, *et al.* The melanocortin-1 receptor is a key regulator of human cutaneous pigmentation. *Pigment Cell Res* 2000;13 Suppl 8:156-62.
- Eller MS, Ostrom K, Gilchrist BA. DNA damage enhances melanogenesis. *Proc Natl Acad Sci U S A* 1996;93:1087-92.
- Smith DR, Spaulding DT, Glenn HM, Fuller BB. The relationship between Na(+)/H(+) exchanger expression and tyrosinase activity in human melanocytes. *Exp Cell Res* 2004;298:521-34.
- Willey A, Anderson RR, Azpiazu JL, Bakus AD, Barlow RJ, Dover JS, *et al.* Complications of laser dermatologic surgery. *Lasers Surg Med* 2006;38:1-15.
- Chan HH. Special considerations for darker-skinned patients. *Curr Probl Dermatol* 2011;42:153-9.
- Randhawa M, Huff T, Valencia JC, Younossi Z, Chandhoke V, Hearing VJ, *et al.* Evidence for the ectopic synthesis of melanin in human adipose tissue. *Faseb J* 2009;23:835-43.
- Breathnach AS. Melanocytes in early regenerated human epidermis. *J Invest Dermatol* 1960;35:245-51.
- Pepper FJ. The epithelial repair of skin wounds in the guinea pig with special reference to the participation of melanocytes. *J Morphol* 1954;95:471-99.
- Snell RS. A study of the melanocytes and melanin in a healing deep wound. *J Anat* 1963;97:243-53.
- Hirobe T. Proliferation of epidermal melanocytes during the healing of skin wounds in newborn mice. *J Exp Zool* 1983;227:423-31.
- Heath RL, Thomlinson AM, Shah M. Melanocytes and burn wound healing. *Burns* 2009;35(Supplement 1):S44-S44.
- Tobin DJ. The cell biology of human hair follicle pigmentation. *Pigment Cell Melanoma Res* 2011;24:75-88.
- Nishimura EK. Melanocyte stem cells: a melanocyte reservoir in hair follicles for hair and skin pigmentation. *Pigment Cell Melanoma Res* 2011;24:401-10.
- Ito M, Liu Y, Yang Z, Nguyen J, Liang F, Morris RJ, *et al.* Stem cells in the hair follicle bulge contribute to wound repair but not to homeostasis of the epidermis. *Nat Med* 2005;11:1351-4.
- Zabierowski SE, Fukunaga-Kalabis M, Li L, Herlyn M. Dermis-derived stem cells: a source of epidermal melanocytes and melanoma? *Pigment Cell Melanoma Res* 2011;24:422-9.
- Matsumoto K, Robb E, Warden G, Nordlund J. Hyperpigmentation of human skin grafted on to athymic nude mice: immunohistochemical study. *Br J Dermatol* 1996;135:412-8.
- Buscà R, Ballotti R. Ballotti, Cyclic AMP a key messenger in the regulation of skin pigmentation. *Pigment Cell Res* 2000;13:60-9.
- Cui R, Widlund HR, Feige E, Lin JY, Wilensky DL, Igras VE, *et al.* Central role of p53 in the suntan response and pathologic hyperpigmentation. *Cell* 2007;128:853-64.
- Shah M, Revis D, Herrick S, Baillie R, Thorgeirson S, Ferguson M, *et al.* Role of elevated plasma transforming growth factor-beta1 levels in wound healing. *Am J Pathol* 1999;154:1115-24.
- Loeken MR. How TGF-beta and PAX3 regulate tanning. *Pigment Cell Melanoma Res* 2009;22:146-7.
- Ortonne JP, Bissett DL. Latest insights into skin hyperpigmentation. *J Invest Dermatol Symp Proc* 2008;13:10-4.
- Coelho SG, Zhou Y, Bushar HF, Miller SA, Zmudzka BZ, Hearing VJ, *et al.* Long-lasting pigmentation of human skin, a new look at an overlooked response to UV. *Pigment Cell Melanoma Res* 2009;22:238-41.
- van der Veer WM, Bloemen MC, Ulrich MM, Molema G, van Zuijlen PP, Middelkoop E, *et al.* Potential cellular and molecular

- causes of hypertrophic scar formation. *Burns* 2009;35:15-29.
36. Grover R, Morgan BD. Management of hypopigmentation following burn injury. *Burns* 1996;22:627-30.
 37. Bongiorno MR, Aricò M. Exogenous ochronosis and striae atrophicae following the use of bleaching creams. *Int J Dermatol* 2005;44:112-5.
 38. Briganti S, Camera E, Picardo M. Chemical and instrumental approaches to treat hyperpigmentation. *Pigment Cell Res* 2003;16:101-10.
 39. Mahé A, Ly F, Aymard G, Dangou JM. Skin diseases associated with the cosmetic use of bleaching products in women from Dakar, Senegal. *Br J Dermatol* 2003;148:493-500.
 40. Sperry K. Tattoos and tattooing. Part I: History and methodology. *Am J Forensic Med Pathol* 1991;12:313-9.
 41. Eves PC, Bullett NA, Haddow D, Beck AJ, Layton C, Way L, *et al.* Simplifying the delivery of melanocytes and keratinocytes for the treatment of vitiligo using a chemically defined carrier dressing. *J Invest Dermatol* 2008;128:1554-64.
 42. Wood FM, Kolybaba ML, Allen P. The use of cultured epithelial autograft in the treatment of major burn wounds: eleven years of clinical experience. *Burns* 2006;32:538-44.
 43. Wood FM, Giles N, Stevenson A, Rea S, Fear M. Characterisation of the cell suspension harvested from the dermal epidermal junction using a ReCell® kit. *Burns* 2012;38:44-51.
 44. Levy SB. Tanning preparations. *Dermatol Clin* 2000;18:591-6.
 45. Mahé A, Ly F, Aymard G, Dangou JM. Skin diseases associated with the cosmetic use of bleaching products in women from Dakar, Senegal. *Br J Dermatol* 2003;148:493-500.
 46. Chikkamuniyappa S, Sjuve-Scott R, Lancaster-Weiss K, Miller A, Yeh IT. Tattoo pigment in sentinel lymph nodes: a mimicker of metastatic malignant melanoma. *Dermatol Online J* 2005;11:14.
 47. Raine C, al-Nakib K, Quaba AA. A role for lasers in the treatment of pigmented skin grafts. *Burns* 1997;23:641-4.
 48. Back C, Dearman B, Li A, Neild T, Greenwood JE. Noncultured keratinocyte/melanocyte cosuspension: effect on reepithelialization and repigmentation--a randomized, placebo-controlled study. *J Burn Care Res* 2009;30:408-16.
 49. Al-Qattan MM. Surgical management of post-burn skin dyspigmentation of the upper limb. *Burns* 2000;26:581-6.
 50. Yamaguchi Y, Hearing VJ. Physiological factors that regulate skin pigmentation. *Biofactors* 2009;35:193-9.

How to cite this article: Chadwick S, Heath R, Shah M. Abnormal pigmentation within cutaneous scars: A complication of wound healing. *Indian J Plast Surg* 2012;45:403-11.

Source of Support: Nil, **Conflict of Interest:** None declared.