

Review Article

Wound coverage considerations for defects of the lower third of the leg

Babu Bajantri, R. Ravindra Bharathi, S. Raja Sabapathy

Department of Plastic, Hand and Reconstructive Microsurgery and Burns, Ganga Hospital, Mettupalayam Road, Coimbatore, Tamil Nadu, India

Address for correspondence: Dr. S. Raja Sabapathy, Department of Plastic, Hand and Reconstructive Microsurgery and Burns, Ganga Hospital, Mettupalayam Road, Coimbatore, Tamil Nadu, India. Email: rajahand@md3.vsnl.net.in

ABSTRACT

Anatomical features of the lower third of the leg like subcutaneous bone surrounded by tendons with no muscles, vessels in isolated compartments with little intercommunication between them make the coverage of the wounds in the region a challenging problem. Free flaps continue to be the gold standard for the coverage of lower third leg wounds because of their ability to cover large defects with high success rates and feasibility of using it in acute situations by choosing distant recipient vessels. Reverse flow flaps are more useful for the coverage of the ankle and foot defects than lower third leg defects. The perforators in the lower third leg on which these flaps are based are often damaged during the injury. In medium-sized defects of less than 50 cm² size, local transposition flaps, perforator flaps, or propeller flaps can be used. Preoperative identification by the Doppler is essential before embarking on these flaps. Of the muscle flaps, the peroneus brevis flap can be used in selected cases with small defects. In spite of all recent developments, cross-leg flaps continue to remain as a useful technique. In rare occasions when other flaps are not possible or when other options fail it can be a life boat. In the author's practice free flaps continue to be the first choice for coverage of wounds in the lower third leg with gracilis muscle flap for small and medium defects, latissimus dorsi muscle flap for large defects and anterolateral thigh flap when a skin flap is preferred.

KEY WORDS

Free flaps; perforator flaps; lower leg defects

INTRODUCTION

The anatomical features of the lower third of the leg make the wound coverage of the soft tissue loss into a challenging problem. The bones of the lower third are vulnerable to injury. Due to the paucity

of soft tissues around them, the fractures that occur are often open. Most muscles become tendons at that level and in the case of soft tissue loss, skin graft may not suffice and flap cover becomes mandatory. The three major arteries to the leg, anterior and posterior tibial, and peroneal are in closed compartments and they do not have significant communications between them. Recently lot of work has been done on the perforators arising from these vessels in the lower third of the leg. The ones from the posterior tibial and the peroneal are significant and could be used for flaps in the region. These perforators may be lost in degloving injuries and such flaps may not be possible.

Access this article online	
Quick Response Code: 	Website: www.ijps.org
	DOI: 10.4103/0970-0358.101299

Conventional teaching recommends gastrocnemius muscle and myocutaneous flaps and fasciocutaneous flaps for the upper third leg defects, soleus flaps for the middle third defects and free flaps for the lower third defects. Understanding of the vascular supply of muscles and the mapping of the perforators has widened the resources available for the plastic surgeon for the coverage of the lower third of the leg. In this article, we have taken the commonly used flaps and detail the technical aspects which we feel are important for obtaining good outcome.

DEBRIDEMENT

Quality debridement is the key to success for the healing of the wounds in the lower third of the leg. This has to follow the well laid out guidelines of debridement.^[1,2] In the lower leg, it is particularly important when the ankle joint is open. In such situations, the maximum displacement seen at the time of initial examination is not the maximum displacement that happened at the time of injury. [Figure 1] The wound is usually on one side and it is quite possible that the tissues on the other side of the ankle are contaminated due to their direct contact with the injuring surface. This area has to be debrided well before reduction of the fracture dislocation to prevent infection. After fracture fixation it is not possible to reach this area and it is one of the commonest cause of infection and non-healing of the wounds in the region.

FREE FLAPS FOR THE LOWER THIRD OF LEG WOUNDS

In spite of the advent and usage of other options like reverse flow flaps and perforator flaps, free flaps continue to be the gold standard for coverage of lower third leg defects [Figure 2]. Free flaps have the following advantages.

1. The size or the geometry of the defect is not an issue when planning free flaps.
2. It can safely be used in acute trauma by sourcing

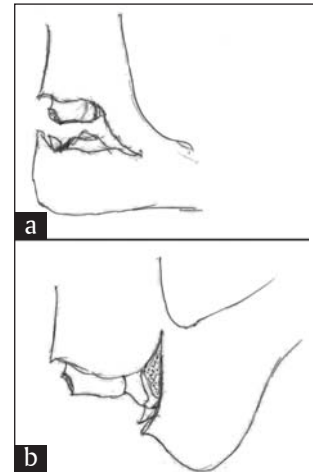


Figure 1: (a) A wound at the lower third of the leg, showing the fracture dislocation of the ankle joint. (b) The real extent of displacement that would have occurred at the time of the accident, in which even the lateral side of the ankle would have been directly exposed to the contaminants. This may escape the scrutiny of debridement predisposing to infection

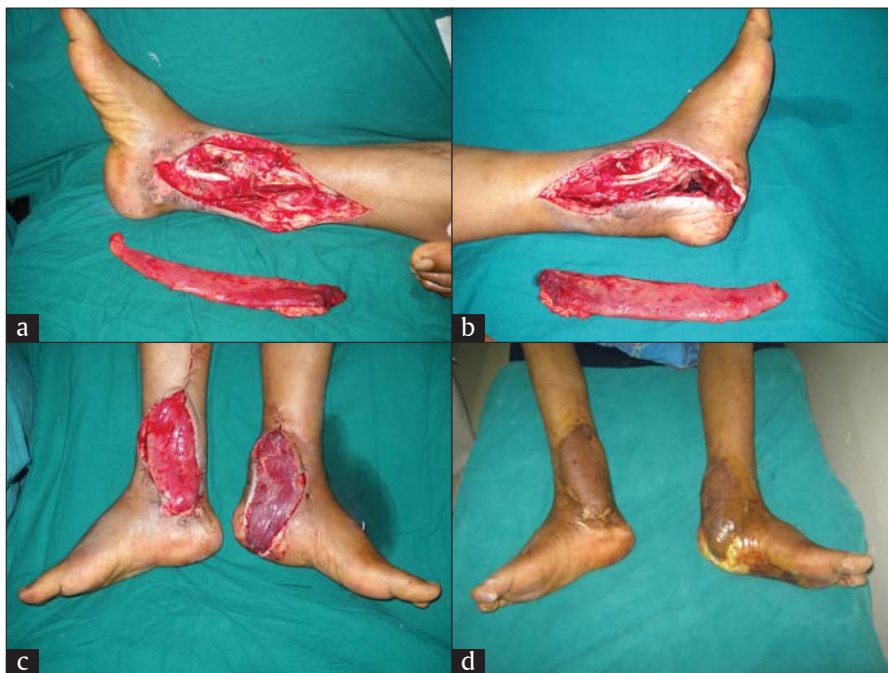

Figure 2: (a and b) A patient with bilateral lower third leg open fracture with soft tissue loss, (c) both sides covered by gracilis free flap and (d) the result at 5 weeks with complete healing of the wounds

recipient vessels away from the zone of injury.

3. It does not involve additional scarring in the surrounding area, as would happen when local flaps are used and their size does not allow primary closure.
4. When well planned, the success rate could be as high as 98%.
5. Choice of free flap could be made according to the need of the defect - muscle flaps when cavities need to be filled and skin flaps when surface defects are to be covered or access is needed for secondary procedures like bone grafting.

TECHNICAL TIPS

The success of free flaps to the lower third of the leg so much depends upon choosing good recipient vessels, it has been said that the surgery of free flaps to the lower third of the leg is the surgery of choosing the recipient vessels.

The vessels must be chosen away from the zone of injury. This could be done by extending the wound to source the vessels. Usually the posterior tibial artery is chosen, because the anterior tibial vessels become deeper as we go proximally into the middle third of the leg. Godina who propagated the concept of early free flap cover for open fractures suggested the technique of exposing the vessels from the popliteal fossa in the midline and continuing distally until the extent where good vessels are present in proximity to the wound.^[3] The vessels are approached between the two heads of gastrocnemius and spitting the soleus in the midline. The vessels are easily accessible. He advocated this technique even to the wounds of the lower third of the leg, since it ensured that there was no proximal level injury to the veins. While this technique may not be practiced in all situations, it is a safe method to follow when there is segmental fracture of the both bones of the leg or a proximal injury and there is a possibility of damage to the venae comitantes at a proximal level. Routinely done, it does not take extra time and the effort is worth the confidence it provides during the procedure.

Sometimes anterior or posterior tibial vessels may be injured and the injured vessel could be used as the recipient vessel. Though it appears to be the natural sequence of decision, it has to be done with care. This practice is safer to use in the acute situation. Even within 48-72 h of injury, the artery needs to be examined closely

to remove all thrombus in the end. In a ligated or divided vessel, clot fills up the vessel at least up to the first branch, proximal to the injury and the vessel needs to be excised proximal to that level. Good pulsatile flow must be obtained before the vessel is accepted as the recipient vessel.

In a single vessel limb, it is safer to choose the single vessel (mostly the posterior tibial artery) and attach the flap by performing an end to side anastomosis.^[4] We feel this is a safer and easier alternative than choosing the anterior tibial artery at a proximal level. Surgeons routinely performing free flaps to the lower third of the leg must become proficient in end to side anastomosis. Angiograms are rarely needed to know the vessel status and we have never done one. In a prospective study of 36 patients, Lutz *et al.* found that in none of the cases with at least one palpable pulse did preoperative angiography add relevant information which led to a plan change in free flap transfer.^[5] Authors concluded that preoperative angiography is indicated only when other pedal pulses are not palpable, and that normal preoperative angiography does not guarantee the presence of vessels suitable for anastomosis. Most problems occur due to the veins and no investigation would reveal their status for microvascular anastomosis.

Useful information can be obtained by careful clinical examination. Both dorsalis pedis and posterior tibial pulses must be felt before deciding the choice of vessel. It is a good practice to do an Allen's test. Simultaneously both pulsations are felt and compression of the posterior tibial artery will make the dorsalis pedis pulse to disappear if the limb is supplied by the posterior tibial artery only. In such situations, end to side anastomosis with posterior tibial artery is mandatory.

Venae comitantes are the preferred choice of veins for free flaps. They are adequate enough and are easily available near the site of arterial anastomosis. Sometimes the long saphenous vein is used. The superficial veins in the lower third of the leg are quite muscular and they are more prone to spasm than the deeper veins. The vessel ends need to be well dilated before using them. When high flow flaps like the latissimus dorsi flaps are used, venous drainage is critical and a good calibre vein needs to be chosen.

When free flaps are done secondarily or for a chronic wound more care needs to be exercised in choosing the vessels, because failures are higher than when free

flaps are done to the lower third of the leg defects for acute wounds. Chronicity and infection make the vessel dissection difficult. The edema that occurs during the initial insult, infection or chronicity leads to fibrosis along the neurovascular plane. This makes the dissection of the veins difficult and they rupture with every attempt at isolation. Good quality veins and arteries have a good plane of tissue to dissect around them and this is used as a guideline in choosing the vessel for anastomosis. A nice plane must be available around the vein at the level of anastomosis. This is the singular advantage of the Godina approach in choosing the recipient vessels for the free flap.

Can vessels distal to the injury be used for attaching the free flap?

Sometimes the division of the artery, which has been pulsating, reveals that the flow is retrograde than antegrade. In such situations, the artery can be attached to the distal segment, but the veins have to be attached in the regular manner. This is more possible in middle third defects than in the lower third leg defects. In all suspected situations, it is better to go for an end to side anastomosis.

Complications

Flap monitoring and anastomosis problems are dealt the same way as when performing free flaps in other areas and hence not discussed in detail. A complication specific to the reconstruction of the lower third of the leg defects is alone discussed.

In a single vessel limb, inadvertently if an end to end anastomosis is done, the amount of distal blood flow due to collateral circulation may not be sufficient in some cases. This may declare itself by the foot becoming pale at the end of the anastomosis. If it is very pale, it may be better to re-establish the circulation and then perform an end to side anastomosis for the flap at a different level. A vein graft may be needed. This is a safer alternative when

distal vascularity is very poor. When allowed to declare itself, it takes a few days and it starts with the toes losing turgidity followed by shrinking and colour change. At that stage, nothing active can be done and one must wait to decide on the level of secondary amputation. This steal phenomenon can occur particularly in elderly people who have peripheral vascular disease.^[6]

REVERSE FLOW FLAPS

Reverse flow flaps based on the anterior tibial and posterior tibial artery are known but are seldom used to cover defects of the lower leg since they sacrifice a major vascular supply to the foot. Reverse flow flaps which do not sacrifice a major vessel are popular in institutions where microsurgical facilities are not available. They are based on the vessels that accompany the sural nerve and lesser saphenous vein.^[7] These vessels are linked with septocutaneous perforators arising from the peroneal artery in the lower third of the leg. A constant perforator available at 5-8 cm proximal to the lateral malleolus is a good one to base the flap. [Figure 3]

When used for lower third leg defects, one has to be sure that the link between the perforators and the arteries accompanying the sural nerve and the lesser saphenous vein are intact. In acute trauma situations, one has to be careful. Reverse flow flaps are safer for ankle and foot defects than lower third defects. Good audible Doppler signals are important before embarking on this flap. Most of the posterior aspect of the skin in the middle third of the leg can be taken as a reverse flow flap and used to cover the lower leg defects. The sural nerve is deeper to deep fascia proximal to the middle of the leg and lies between the two heads of the gastrocnemius. When elevating the flap, the proximal incision is made first and the sural nerve and the lesser saphenous vein are first identified beneath the fascia and included in the flap. As dissection proceeds distally, the base of the flap could be

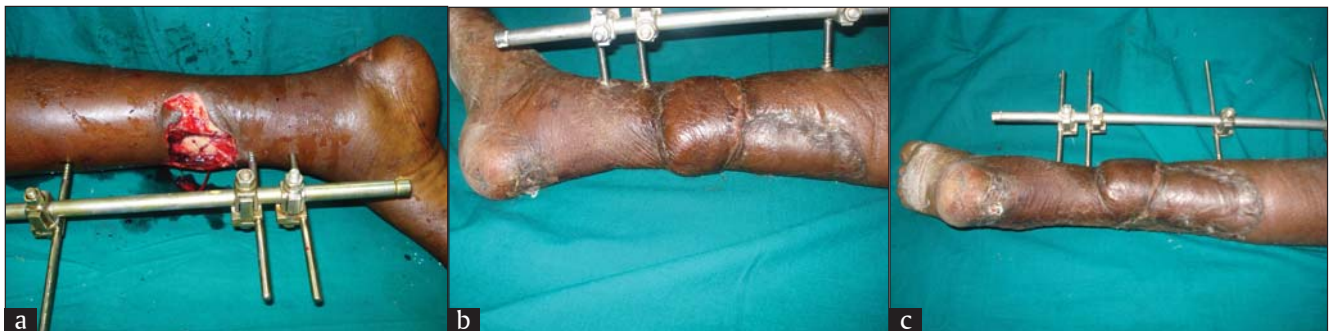

Figure 3: (a) The defect in the lower third leg exposing the fracture site, (b) covered by a reverse flow sural artery flap and (c) shows the obvious donor site

narrowed to just include the nerve and the vein and is centred on the posterior peroneal intermuscular septum to include the perforators arising from the peroneal vessels. In this way, the flap is made reliable.

Flaps of smaller diameter (up to 5 cm) can be directly closed. These flaps share the disadvantage of aesthetically unacceptable donor sites common to all large flaps raised from the leg when they have to be covered with the skin graft. In this aspect, the free flaps have a definite advantage.

LOCAL AND PERFORATOR FLAPS IN THE LOWER THIRD OF THE LEG

Local transposition flaps can be used to cover small defects in the lower third of the leg and their greatest limitation is the size of the defect they could cover in this region [Figure 4]. Increased understanding of the blood flow dynamics has shown us that vessels of small diameter when isolated can supply a large territory of the skin. Flaps based on these small vessels called as perforators could be used to cover even big defects. The flap could be islanded and based only on the perforators and it increases the mobility of the flap. When turned over 180°, it is called as a propeller flap [Figure 5]. Dissection requires skill and it can be called as microsurgery without anastomosis.

These flaps are particularly useful for small- to medium-

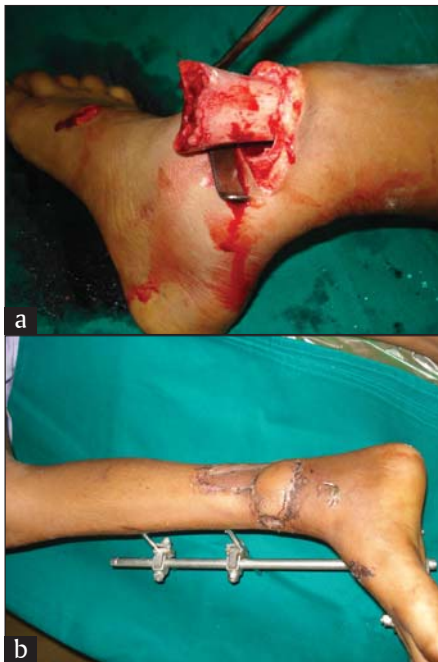

Figure 4: (a) An open fracture dislocation of the ankle which after reduction left a transverse defect which could not be primarily closed, (b) covered by a local transposition flap

sized defects around the ankle up to 50 cm² in size. For the defects on the medial and anterior leg, propeller flaps based on the perforators of the posterior tibial artery, which seems to have a constant perforator at around 10 ± 2 cm could be safely done. For narrow critical defects V–Y advancement can be done wherein one or multiple perforators supplying the skin island can be safely advanced to cover the defect. On the lateral aspect distally, the peroneal perforators are smaller in size and number and are not that constant in position. In such a situation a throw over flap based on the posterior tibial artery perforator can be safely done.^[8]

It is good to do a preoperative Doppler to mark the perforators on which the flap can be planned. However, there is high percentage of false-positive signals. The perforators are best identified on the table by using an exploratory incision. Depending on the number and size of the perforators, one has to be ready to alter the plan. For posterior tibial artery, the exploratory incision is usually made posteriorly taking care to place it over the muscular part and preserve the fascia over the tendoachilles. We have noted a constant significant perforator at the level 10 ± 2 cm from the medial malleolus. If we see a perforator going to the muscle, we expect a cutaneous perforator at the same level.

After having identified the perforator of adequate size, the flap is planned basing it as a pivotal point. Adding an additional 1 cm length of the flap allows easy inset. It has been observed that the clockwise rotation of the flap kinks the pedicle less and hence the flap should be planned accordingly.

The flap is islanded retaining all the significant perforators to it. After releasing the tourniquet, the flap viability is checked based on the perforator on which it has been planned by temporarily clamping the other perforators with microclamps. If it is adequate, the other perforators are divided. If not, it requires an alteration in the plan. All the fibrous strands around the pedicle are carefully removed with microforceps and scissors to avoid kinking of the vein on rotation. Now the flap can be rotated to the defect. The flap is inset with few loose sutures. The donor defect can be closed primarily only in narrow longitudinal defects. In acute trauma, skin grafting of the donor site is preferred because the edema makes closure tight and difficult. While doing this flap, we cannot commit till the perforator is identified. In the absence of the ideal perforator, one has to be prepared to do a free flap.

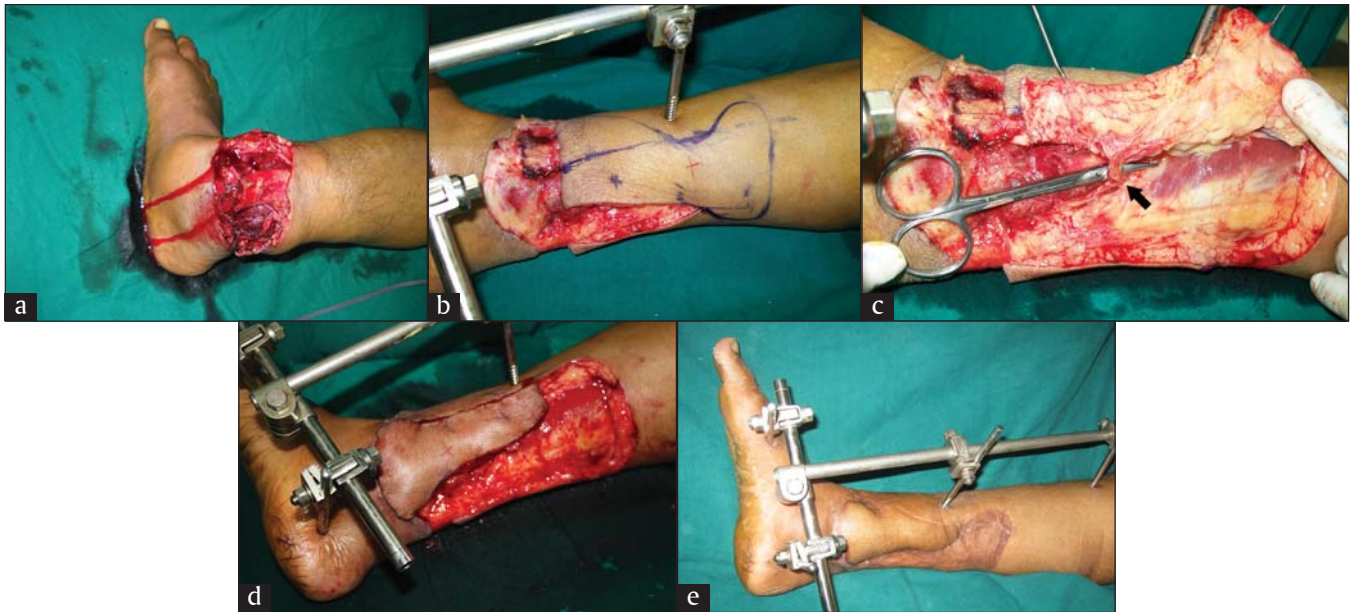


Figure 5: (a) A major crush injury of the lower third of the leg, (b) the defect after debridement and the Doppler examination showed good audible signals at X, and a flap marked, (c) the proposed flap elevated on one side and the perforator visualized before the whole flap is raised, (d) the flap raised and rotated through 180 degrees to cover the critical area and (e) a well-settled flap and the healed donor area

MUSCLE FLAPS

In the distal third of the leg, all the muscles become tendinous and hence there is not enough of muscle bulk to provide flap cover. However a distally based peroneus brevis muscle flap has been described which can reliably cover the defects in the lower leg and around the malleolar regions.^[9,10] This is based on the distal perforator which is found within 6 cm from the tip of lateral malleolus [Figure 6]. This is the last of the series of perforators supplying the muscle.

CROSS LEG FLAPS

Cross leg flaps, in spite of the inherent morbidity associated with the procedure, continue to remain as a useful technique for the coverage of wounds in the lower third of the leg. They are particularly useful when the lower third of the defect is associated with a proximal injury. In such cases though the arteries may be patent, suitable veins for the free flap may not be available. Cross leg flap when planned for the lower third leg defects has to be a distally based flap [Figure 7]. The base is to be planed to include perforators not only from the posterior tibial artery but also from the peroneal artery and the sural nerves. While planning, the length of the proximal edge of the flap will be equal to the length of the defect. If a long bridge segment is needed and if the flap extends to the proximal third of

the leg, prior delay is advised. Since cross leg flaps are resorted to in situations where other options are not feasible, it is safer to delay the flap. Flaps division is done at 3 weeks. If the inset of the flap exceeds more than 70% of the outline of the defect, a delay prior to division may not be needed.

ROLE OF VAC

VAC or vacuum-assisted closure, otherwise called NPWT (negative pressure wound therapy) has been used extensively in complex wounds of the lower limb either as an interim measure before the definitive cover or as a definitive therapy to achieve wound cover by forming granulation tissue over the implants and exposed bones over which a skin graft can be applied. In a retrospective study published in 2006 by Parrett *et al.*,^[11] they found a changing trend in the use of free flaps in a period of 12 years. Free flaps decreased from 42% over the first period to 11% in the last 4 years when VAC was extensively used. They have said that there is no statistically significant difference in infection, amputation and malunion/non-union rates.

Bhattacharyya^[12] studied the infection rate in 38 patients with Grade III B open fractures treated with NPWT to see if the definitive time for wound closure can be extended beyond the conventionally held view of 7 days. There was an increase of infection rate from 12% to 57% despite the

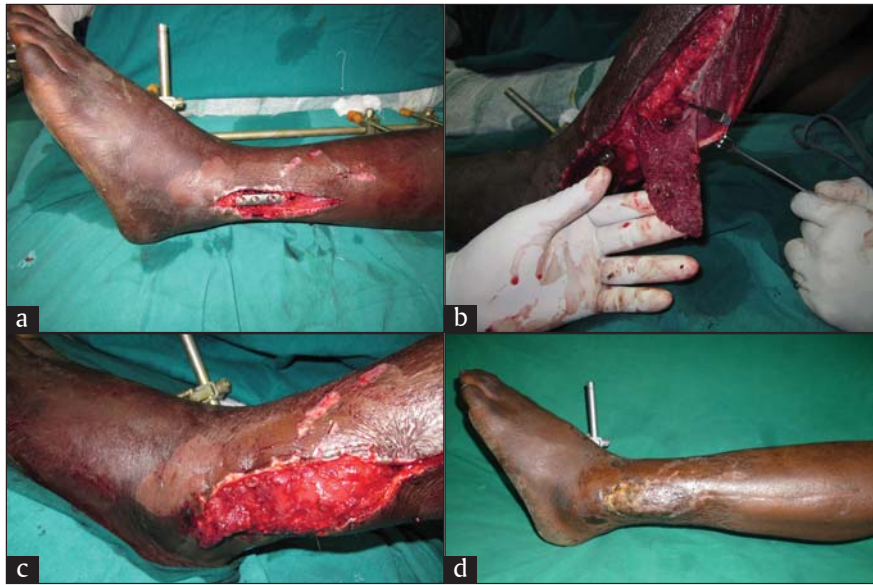

Figure 6: (a) A defect on the lateral side of the lower third of the leg and (b) the distally based peroneus brevis muscle raised retaining the last perforator. The clamp is on the proximal perforator to confirm the viability of the muscle with the distal perforator, (c) the muscle turned over to cover the defect and (d) the healed wound with a primarily closed donor defect

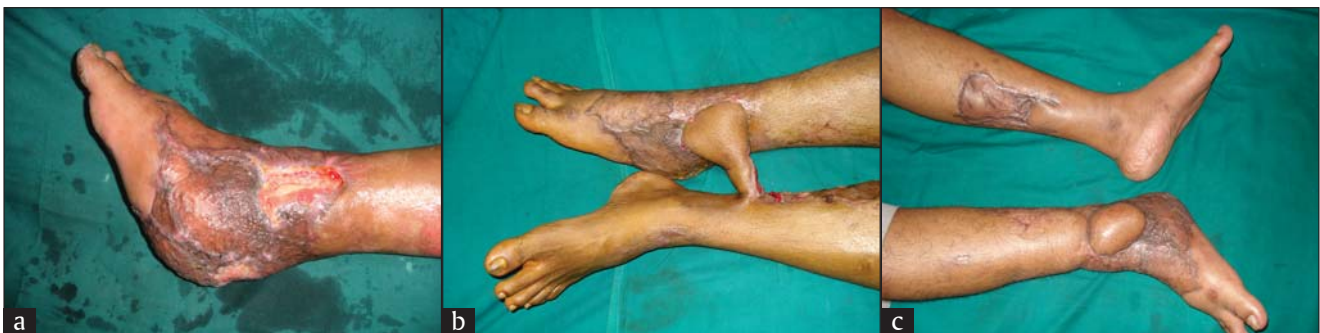

Figure 7: (a) Exposed bone in the lower third leg with graft all around in a major crush injury leg with no good proximal recipient vessels. (b) Distally based cross leg flap, where the proximal edge attaches to the length of the defect (c) after completion of reconstruction

use of negative pressure. Although the study is small, this does suggest a degree of caution in using NPWT as a delaying tactic in lower extremity trauma and suggests that the strategy of trying to close these wounds within 7 days is still essential in the era of negative pressure wound therapy.

DISCUSSION

We now have a set of viable alternatives to cover the various defects in the lower third of the leg. What would one use depends upon the familiarity and the comfort levels of the surgeon with the technique as much as the various circumstances. This is sometimes good since by repeatedly doing the procedure one masters the technique which helps to keep the complications down. But however good the surgical skills may be, each flap and technique has its own inherent limitations. Hence, it is good that a plastic

surgeon is familiar with all techniques so that he has a wide choice to choose from to the benefit of the patient particularly in a demanding situation as when covering a defect in the lower third of the leg.

Of all the available options, free flaps still remain the gold standard for the coverage of soft tissue defects of the lower third of the leg. Skin or muscle free flaps could be chosen as per the need, and the size and shape of the defect are not a factor and aesthetically also it is the most desirable since it does not leave a donor defect in the vicinity. When microsurgical facilities are not available, other options may be chosen being fully aware that local pedicled flaps and perforator flaps are equally technically demanding procedures.

Negative pressure wound therapy is popular but there are no studies which deal exclusively with lower third

leg defects. It is a good temporary measure to cover the wound but not be used as a delaying tactic to performing a flap cover when needed. While in other parts of the lower limb it may reduce the incidence of the need for flap cover, it is questionable as to how much it will reduce the need in the lower leg and ankle region. If there would be a need for secondary procedures like a bone graft or bone transport to be done, then early skin flap cover is a better option.

With the knowledge of perforators supplying the lower third leg, local flaps and perforator flaps are being done with increasing frequency. They are limited by size that they could cover and are to be done with equal care as though performing a microvascular procedure.

Healthcare delivery is currently very much influenced by the cost of care and the surgeon's choice of various procedures is also influenced by the reimbursement levels. Hence, studies of the various procedures should also be evaluated by the social system in which the study has been performed. Ultimately the surgeon should choose the procedure which in his hands would give the best result keeping the best interest of the patient in mind.

REFERENCES

1. Gupta A, Shatford RA, Wolff TW, Tsai TM, Schecker LR, Vevin LS. Treatment of the severely injured upper extremity. *J Bone Joint Surg* 1999;81:1628-51.
2. Sabapathy SR. Debridement – preparing the wound bed for cover. In: Sarabahi S, Tiwari VK, editors. *Principles and Practice of Wound Care*. New Delhi: Jaypee Publishers; 2012. p. 68-79.
3. Godina M. A thesis on the management of injuries to the lower extremity. PresernovaDruzba. Ljubljana: 1991.
4. Godina M. Preferential use of end-to-side arterial anastomoses in free flap transfers. *Plast Reconstr Surg* 1979;64:673-82.
5. Lutz BS, Wei FC, Machens HG, Rhode U, Berger A. Indications and limitations of angiography before free flap transplantation to the distal lower leg after trauma: Prospective study in 36 patients. *J Reconstr Microsurg* 2000;16:187-91.
6. Sonntag BV, Murphy RX, Chernofsky MA, Chowdary RP. Microvascular steal phenomenon in lower extremity reconstruction. *Ann Plast Surg* 1995;34:336-40.
7. Masquelet AC, Romana MC, Wolf G. Skin island flaps supplied by the vascular axis of the sensitive superficial nerves: Anatomic study and clinical experience in the leg. *Plast Reconstr Surg* 1992;89:1115-21.
8. Bajantri B, Sabapathy SR, Burgess TM. The throw over flap; a modification of the propeller flap for reconstruction of non-adjacent soft tissue defects. *Indian J Plast Surg* 2011;44:525-6.
9. Ng YH, Chong KW, Tan GM, Rao M. Distally pedicled peroneus brevis muscle flap: A versatile lower leg and foot flap. *Singapore Med J* 2010;51:339-42.
10. Lorenzetti F, Lazzeri D, Bonini L, Giannotti G, Piolanti N, Lisanti M, *et al.* Distally based peroneus brevis muscle flap in reconstructive surgery of the lower leg: Postoperative ankle function and stability evaluation. *J Plast Reconstr Aesthet Surg* 2010;63:1523-33.
11. Parrett BM, Matros E, Pribaz JJ, Orgill DP. Lower extremity trauma: Trends in the management of soft-tissue reconstruction of open tibia-fibula fractures. *Plast Reconstr Surg* 2006;117:1315-22; discussion 1323-4.
12. Bhattacharyya T, Mehta P, Smith RM, Pomahac B. Routine use of wound vacuum- assisted closure does not allow coverage delay in open tibial fractures. *Plast Reconstr Surg* 2008;121:1263-6.

How to cite this article: Bajantri B, Bharathi RR, Sabapathy RS. Wound coverage considerations for defects of the lower third of the leg. *Indian J Plast Surg* 2012;45:283-90.

Source of Support: Nil, **Conflict of Interest:** None declared.