



AIMS Genetics, 3(1): 49-59.  
DOI: 10.3934/genet.2016.1.49  
Received 3 February 2016,  
Accepted 20 March 2016,  
Published 29 March 2016

<http://www.aimspress.com/journal/Genetics>

---

## Review

# Aarskog-Scott syndrome: phenotypic and genetic heterogeneity

M. Reza Jabalameli<sup>1</sup>, Ignacio Briceno<sup>2</sup>, Julio Martinez<sup>2</sup>, Ignacio Briceno<sup>3</sup>, Reuben J. Pengelly<sup>1</sup>, Sarah Ennis<sup>1</sup>, and Andrew Collins<sup>1,\*</sup>

<sup>1</sup> Genetic Epidemiology & Genomic Informatics, Faculty of Medicine, University of Southampton, Southampton, UK

<sup>2</sup> Department of Biomedical Sciences, Medical School, Universidad de La Sabana, Bogota, Colombia

<sup>3</sup> Instituto de Genética Humana, Faculty of Medicine, Pontificia Universidad Javeriana, Colombia

\* **Correspondence:** Email: [arc@soton.ac.uk](mailto:arc@soton.ac.uk); Tel: +44(0)2381206939;  
Fax: +44(0)2380794264.

**Abstract:** Aarskog-Scott syndrome (AAS) is a rare developmental disorder which primarily affects males and has a relative prevalence of 1 in 25,000 in the general population. AAS patients usually present with developmental complications including short stature and facial, skeletal and urogenital anomalies. The spectrum of genotype-phenotype correlations in AAS is unclear and mutations of the *FGD1* gene on the proximal short arm of chromosome X account for only 20% of the incidence of the disorder. Failure to identify pathogenic variants in patients referred for *FGD1* screening suggests heterogeneity underlying pathophysiology of the condition. Furthermore, overlapping features of AAS with several other developmental disorders increase the complexity of diagnosis. Cytoskeletal signaling may be involved in the pathophysiology of AAS. The FGD1 protein family has a role in activation of CDC42 (Cell Division Control protein 42 homolog) which has a core function in remodeling of extracellular matrix and the transcriptional activation of many modulators of development. Therefore, mutations in components in the EGFR1 (Epidermal Growth Factor Receptor 1) signaling pathway, to which CDC42 belongs, may contribute to pathophysiology. Parallel sequencing strategies (so-called next generation sequencing or high throughput sequencing) enables simultaneous production of millions of sequencing reads that enormously facilitate cost-effective identification of cryptic mutations in heterogeneous monogenic disorders. Here we review the source of phenotypic and genetic heterogeneity in the context of AAS and discuss the applicability of next generation sequencing for identification of novel mutations underlying AAS.

**Keywords:** Aarskog-Scott Syndrome; *FGD1* gene; genetic heterogeneity; phenotypic heterogeneity; next generation sequencing

---

## 1. Introduction

Aarskog-Scott syndrome (AAS, OMIM #305400) (also known as faciogenital dysplasia) is a complex developmental disorder initially described by Aarskog in a Finnish pedigree [1] and later by Scott [2]. Patients with AAS present with a range of developmental complications including short stature, hypertelorism, ptosis, long philtrum, micrognathia, broad nasal bridge, clinodactyly of the little finger and genitourinary abnormalities including cryptorchidism and shawl scrotum [3]. Causal genetic variants underlying AAS pathophysiology map to the proximal short arm of chromosome X (Xq11.22) [4] and, to date, 61 different mutations across the 18 exons of the *FGDI* gene are reported as pathogenic in the context of the condition. The *FGDI* mutational spectrum includes 32 missense mutations, 16 frameshift variants, 6 nonsense variants, 4 splice site variants, 1 in-frame deletion and 2 out of frame deletions [5–10].

While only a limited number of the reported cases have been molecularly confirmed (~35), the population incidence of two to three patients with a proven *FGDI* mutation per year is suggestive of world population prevalence of 1/25000 [5]. It is notable that the reported mutations only describe 20% of the known cases of AAS [6] and the spectrum of genotype-phenotype correlations is unclear. Failure to identify pathogenic variants in patients who are referred for *FGDI* mutation analysis must reflect extensive clinical and genetic heterogeneity in AAS. In particular, the phenotypic features of the condition overlap with several other developmental disorders. Since it is now possible to undertake cost-effective sequencing of genes of clinical interest, exomes, or indeed whole genomes, there is greatly increased confidence that phenotypic overlaps can be resolved and underlying genetic causal variation understood for AAS and AAS-like syndromes. We review here sources of phenotypic and genetic heterogeneity underlying the condition and discuss the extent to which next generation sequencing can be utilized to detect new mutations in AAS.

## 2. Phenotypic presentation

A diagnosis of AAS is normally established through the Teebi criteria [7] by evaluating phenotypic features in a mother and an affected son. In this approach the clinical manifestation of the condition is studied in a tiered fashion and diagnosis is established in the presence of all primary and most secondary criteria. A detailed list of the diagnostic criteria and clinical features which differentiate AAS from similar syndromes is provided in Table 1. Short stature, hypertelorism and fold of the lower lip are the primary features present in nearly all cases [8]. Brachydactyly, interdigital webbing, shawl scrotum, long philtrum and mild facial hypoplasia are secondary features observed in almost 80% of cases. Additional phenotypic manifestations which include cryptorchidism, inguinal hernia, downward eye slant and ptosis are present in only a fraction of patients and therefore deemed secondary for diagnosis. AAS patients usually present with delayed growth in early childhood, but achieve developmental milestones later in life [9]. AAS predominantly influences males and phenotypic complications are attenuated in females. Two separate reports identify impaired executive attentional processes including attention deficit/hyperactivity disorder (ADHD) [10] and mania [11].

**Table 1. Teebi tiered criteria for differential diagnosis of Aarskog-Scott Syndrome [12,17].**

<i>Criteria</i>	<i>AAS</i>	<i>Kuwait</i>	<i>Robinow Syndrome</i>	<i>Optiz Syndrome</i>	<i>Naguib-Richieri-Costa Syndrome</i>	<i>Teebi Hypertelorism Syndrome</i>	<i>Craniofrontonasal Dysplasia (CFND)</i>
<b>AAS Primary Diagnostic Criteria</b>							
<i>Hypertelorism</i>	+	+	+	+ variable	+	+ pronounced	+ variable
<i>Short nose/ anteverted nares</i>	+	+	+	+ mild	+	+	+/-
<i>Maxillary hypoplasia</i>	+	+	+	+	-	+	+/- asymmetry
<i>Crease below lower lip</i>	+	-	-	-	+	-	-
<i>Short, broad hands</i>	+	+	+	-	-	+/-	+/-
<i>Mild, interdigital webbing</i>	+	+	-	+	+	+	-
<i>Short stature</i>	+	+	+	-	-	-	-
<i>Shawl scrotum</i>	+	+	-	-	+	+	+
<i>Short fifth finger/ clinodactyly</i>	+	+	+	-	-	+	+
<b>AAS Secondary Criteria</b>							
<i>Widow's peak</i>	+	+	-	+	+	+	-
<i>Ptosis</i>	+	-	-	+/-	+	+	-
<i>Downward slant of palpebral fissures</i>	+	-	-	+/-	+	+	-
<i>Abnormal auricle/Fleshy lobules</i>	+	+	+	+	+	+	-
<i>Joint hyperextensibility</i>	+	+	-	+	-	-	+/-
<i>Broad feet with bulbous toes</i>	+	+	+	-	+ variable	+	- long toes
<i>Cryptorchidism/inguinal umbilical hernia</i>	+	-	+	+	-	+	-
<i>Large head/bossing</i>	+/-	-	+	-	-	+	+
						brachycephaly	
<i>Craniosynostosis</i>	-	-	-	-	-	-	+
<i>Broad or bifid nasal tip</i>	-	-	-	+	+	+	-
<i>Thick eyebrows</i>	-	-	-	-	+	+	-
<i>True syndactyly</i>	-	-	-	+ toes	+ 3 and 4 fingers	-	-
<i>Nail groove</i>	-	-	-	-	-	-	+/-
<i>Broad thumb/toe, duplications or polydactyly</i>	-	-	-	-	+	-	+
<i>Short limbs</i>	-	-	+	-	-	-	+
<i>Hypoplastic genitalia</i>	-	-	+	-	-/+	-	-
<i>Hypospadias</i>	+/-	-	-	+ constant	+	-	-
<i>Laryngeal complications</i>	-	-	-	+	-	-	-

<i>Criteria</i>	<i>AAS</i>	<i>Kuwait</i>	<i>Robinow Syndrome</i>	<i>Optiz Syndrome</i>	<i>Naguib-Richieri-Costa Syndrome</i>	<i>Teebi Hypertelorism Syndrome</i>	<i>Craniofrontonasal Dysplasia (CFND)</i>
<i>Vertebral anomalies</i>	+	-	+	-	-	-	-
<i>Intelligence</i>	Usually Normal	Normal	Normal	Variable	Normal	Normal	Variable
<i>Affected sex</i>	Mostly males	Both	Both	Both	Both	Both	Mostly females
<i>Inheritance</i>	AD, XL	AR	AD, AR	AD, XL	AR	AD	?AD, ?XL

Key: AD: Autosomal dominant, AR: Autosomal recessive, XL: X-linked

### 3. Phenotypic heterogeneity: related syndromes and differential diagnosis

Similarities between the phenotypic faciogenital characteristics of AAS patients and other developmental disorders including Noonan syndrome, SHORT syndrome (Short stature, hyperextensibility, hernia, ocular depression, Rieger anomaly, and teething delay) and Robinow syndrome increase the complexities of diagnosis. Noonan (OMIM #163950) and Noonan-like syndromes in particular show significant similarities to AAS. Hypertelorism, genital anomalies and ptosis are present in both conditions, however, additional characteristics of Noonan syndrome including heart abnormalities and lymphatic malformations contribute to unambiguous diagnosis [12]. Similarly, Robinow syndrome (OMIM #268310) presents with many manifestations identical to AAS. While short stature, hypertelorism and facial anomalies are seen in both conditions, shawl scrotum is restricted to AAS patients and Robinow patients present characteristic shortening of mesomelic limbs [13]. Furthermore, LEOPARD syndrome (OMIM #151100) in which patients present with Lentigines, Electrocardiographic condition defect, Ocular hypertelorism, Pulmonary stenosis, Abnormalities of genitals, Retarded growth and Deafness shares some phenotypic characteristics of AAS. LEOPARD syndrome appears to occur sporadically and therefore differential diagnosis is usually established based on mode of inheritance [14]. Since related syndromes may share phenotypic features with AAS differential diagnosis therefore requires careful consideration of a spectrum of phenotypic features. Establishment of a robust AAS diagnosis requires consideration of the age and gender of the patient [15]. Furthermore, resolution of any developmental delay issues during later stages of development is indicative of AAS. Female AAS patients, arising through X-linked recessive inheritance, present with attenuated features of the condition. This can be attributed to skewed X-inactivation in which the causal X-linked allele is subject to strong selection to become inactivated [16]. The extent of non-random X-inactivation in the context of AAS is poorly understood and merits further investigation. Genitourinary abnormalities are almost always restricted to male patients.

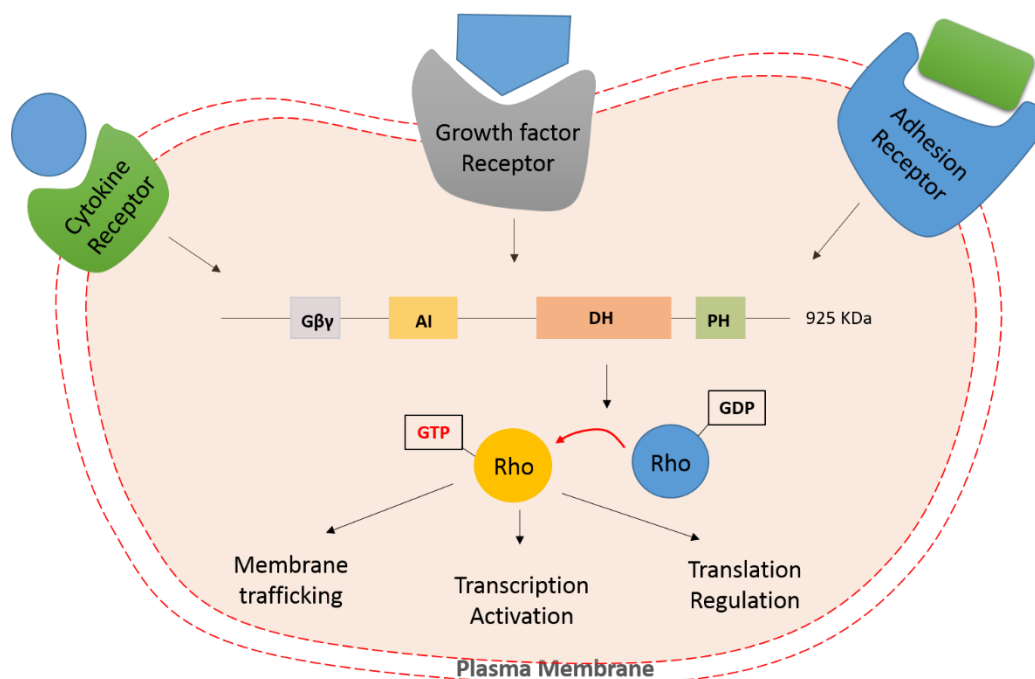
Rare AAS cases with additional complications including spina bifida occulta (incomplete closure of the spine and surrounding tissues), cervical spine abnormalities [17], scoliosis (abnormal curve of spine) [18], camptodactyly (fixed flexion deformity of the joints in toes) and lymphoedema [19],

macrochidism (abnormally enlarged testis) [20] and ocular complications (optic nerve hypoplasia, retinal vessel tortuosity, deficient ocular elevation, hyperopia and anisometropia) [21–23] are also reported.

The clinical spectrum of AAS phenotypes and overlap with related syndromes is sufficiently broad to complicate diagnosis and in many cases a definitive diagnosis can only be established through molecular methods such as targeted sequencing [24].

#### 4. The functional role of *FGDI*

At least 61 mutations known to be involved in AAS map to the *FGDI* gene which is located at the proximal short arm of chromosome X (Xp11.22) [25]. *FGDI* encodes a member of the Dbl family of guanine nucleotide exchange factors (GEFs) which play important roles in cell division through activation of Rho GTPase cell division cycle 42 (*CDC42*) [26]. Dbl family GEFs comprise a highly conserved Dbl homology (DH) domain and a tandem pleckstrin homology (PH) domain that functions immediately upstream of Rho GTPases. Following stimuli from growth factor or cytokine receptors, the PH domain of the protein targets intracellular Rho-GDP complexes and the catalytic activity of DH domain phosphorylates Rho-GDP. The activated Rho-GTP complex initiates a cascade of downstream signaling leading to transcription activation, regulation of translation and membrane trafficking (Figure 1; reviewed in [27]). The precise mechanisms by which *FGDI* mutations cause the dysmorphic craniofacial features of AAS is unclear, but it is believed that pathogenic mutations of *FGDI* disrupt *CDC42* signaling during skeletogenesis and the disturbed extracellular matrix remodeling results in characteristic faciogenital anomalies of AAS [28].



**Figure 1. Domain structure and signaling cascade of Dbl family GEFs in the regulation of Rho-GTPase function.** (AI: autoinhibitory domain; Gβγ: Gβγ domain; DH: Dbl homology domain; PH: Pleckstrin homology domain). Signaling cascade initiates upon

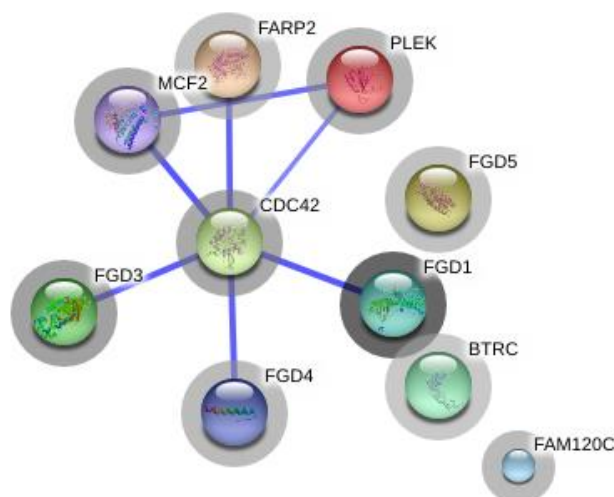
activation of range of cell surface receptors including cytokine receptors, growth factor receptors and adhesion receptors where the PH domain of Dbl family GEFs are thought to have interactions with cell-membrane phospholipids. Stimuli from the receptor lead to conformational change in Dbl family GEFs which lead to activation of PH domain through relief of intramolecular interactions. DH domain in turn facilitate activation of Rho GTPase through exchange of GDP to GTP. Activated Rho-GTPase subsequently mediates activation of variety of downstream pathways including transcription activation, translation regulation and membrane trafficking.

## 5. AAS mode of inheritance

Segregation analysis indicates that AAS is typically an X-linked recessive condition, however sex-influenced autosomal dominant and autosomal recessive patterns of inheritance have also been reported [21,29]. An autosomal recessive form is recurrently observed in the Kuwaiti Bedouin tribe with prevalence of 1 in 625 [25]. The phenotypic spectrum in this tribe, where consanguineous marriage is common, is consistent with AAS and indicates a founder effect in this population. In addition, several reports have identified a sex influenced autosomal dominant pattern for AAS [23,30,31] with at least one report of complete phenotypic expression in a mother and her son who both had a balanced X: autosome translocation [23]. The determination of carrier status in female patients is usually challenging as skewed X-inactivation results in random and attenuated expression [32]. The detailed characteristics of known *FGDI* mutations underlying faciogenital dysplasias extracted from the LOVD v.3.0 database [33] is provided in Supplementary Table S1.

## 6. Discussion

Increasing evidence suggests the Dbl family of proteins play critical roles in essential cell processes, including cytoskeleton organization, regulation of vesicular endocytosis and intracellular signal transduction. Mutations in genes encoding these proteins are associated with variety of developmental syndromes and their pathologies display overlapping features with AAS [34]. Because known *FGDI* mutations only explain ~20% of cases the pathologic mutations underlying most cases remain undefined and mutations in genes within this family, or related pathways, are strong candidates. The variability in disease expression and the extensive phenotypic similarities between AAS and RASopathies (Noonan syndrome, LEOPARD syndrome, cardio-facio-cutaneous syndrome and Costello syndrome) suggest possibilities for identifying additional AAS causal genes in related pathways. Germline mutations of the RAS/MAPK signaling pathway are implicated in RASopathies and all recently discovered mutations in the context of RASopathies map to components of mitogen-activated protein kinase [35]. Genotype-phenotype correlations in AAS are poorly understood and it seems plausible that some cases without molecular diagnosis arise through mutations in key modulators of development which function both upstream and downstream of the *FGDI* protein (Figure 2 and Table 2) [36,37].



**Figure. 2 Schematic representation of the human FGD1 interactome compiled in STRING v.10 [38].** Neighboring proteins with direct interactions usually function in the same signaling pathway and are therefore responsible for the same, or phenotypically similar, disorders. The FGD1 interactome highlights the genes whose protein products are known to have direct protein-protein interaction with CDC42, the key protein in EGFR1 signaling pathway that implicated in AAS pathophysiology.

**Table 2. Predicted FGD1 signaling partners and their functions [38].**

<i>Gene/ Protein ID</i>	<i>Name</i>	<i>Function</i>
CDC42	Cell division cycle 42	Plasma membrane-associated small GTPase which cycles between an active GTP-bound and an inactive GDP-bound state.
FGD3	FYVE, RhoGEF and PH domain containing 3	Member of the Ras-like family of Rho and Rac proteins- may activate CDC42
MCF2	Cell line derived transforming sequence	Encodes a GEF oncoprotein that regulates activation of some members of the Rho family of small GTPases.
PLEK	Pleckstrin	Major protein kinase C substrate of platelets.
FAM120C	Family with sequence similarity 120C	–
FGD4	FYVE, RhoGEF and PH domain containing 4	Member of the Ras-like family of Rho and Rac proteins. Activates CDC42 and plays an important role in regulating the actin cytoskeleton and cell shape.
FARP2	FERM, RhoGEF and pleckstrin domain protein 2	Encodes a GEF that activate RAC1. May have attenuated activity.
FGD5	FYVE, RhoGEF and PH domain containing 5	Member of the Ras-like family of Rho and Rac proteins. Activates CDC42. Possibly plays a role in regulating the actin cytoskeleton and cell shape.
BTRC	Beta-transducin repeat containing E3 ubiquitin protein ligase	Encodes one member of F-box protein that constitutes one of the four subunits of SCFs (SKP1-cullin-F-box) that function in phosphorylation-dependent ubiquitination.

Comprehensive molecular diagnosis of AAS patients may need to consider sources of causal variation that may be missed by, for example, exome sequencing which excludes intronic variants (including splice site branch points). Therefore, in some cases gene resequencing or whole-genome analysis may be the most suitable approach for establishing the molecular basis for pathophysiology of the condition. The identification of a branch point variant within an intronic region adjacent to exon 13 of *FGDI* [39] in an AAS case lends further support to effectiveness of whole gene/genome sequencing. In the latter study the causative variant was identified only upon relaxing the filtering criteria to include larger intronic segments. *In-silico* analysis predicted that the identified aberration of a splice site leads to the skipping of exon 13 and disruption in the reading frame introducing a premature stop codon [40].

The very large number of potentially deleterious variants identified by sequencing presents challenges. Even with rigorous filtering and prioritization procedures there may be difficulties in firmly establishing underlying pathogenic variants. In a recent study [41] into the effectiveness of clinical whole-genome sequencing of patients with uncertain molecular diagnosis, the authors established that causal variants could be firmly identified in only 34% of patients with Mendelian disorders. In targeted high-throughput sequencing of heterogeneous disorders the probability of successful identification of causal variants is directly correlated with the number of major clinical features presented by the patient. The latter notion is demonstrated in a study by Redin et al. [30] where comparison of clinical phenotypes between patients with more than one detected pathogenic variant and those with either one or no suspicious pathogenic variant clearly demonstrated the importance of precise phenotyping in facilitating accurate identification of underlying causal mutations.

Another consideration in the analysis of high-throughput sequencing data is the presence of high frequency pathologic variants in isolated populations (e.g. the Kuwaiti Bedouin tribe) that might be otherwise neglected during filtering and prioritization processes. This challenge could be addressed through application of high-throughput autozygosity mapping [31] and haplotype-based variant callers [42].

More than 21 Guanine nucleotide exchange factors (GEFs) have been identified so far which have key roles in various intracellular processes ranging from gene expression to intracellular trafficking and cytoskeleton rearrangements [43]. It is conceivable that additional pathogenic variants that underlie AAS are located in these genes and their identification will be facilitated through establishing rigorous phenotyping strategies and analysis of high-throughput sequencing data.

In this review we have discussed phenotypic and genetic heterogeneity underlying AAS. In the majority of cases the condition is associated with germline *FGDI* mutations, but many reported cases lack a molecular diagnosis and therefore precise clinical diagnosis as AAS cannot be independently established. This is of particular importance given extensive phenotypic heterogeneity in AAS and phenotypic overlap with other developmental disorders. Therefore, the molecular understanding of this condition is substantially incomplete and a more comprehensive approach toward molecular identification of causative variants is required. In summary, mutations of *FGDI* remains the primary molecular candidate for the condition but the burden of pathological variants in either intronic regions of *FGDI* or related genes, including *CDC42*, and other genes in relevant pathways merits further investigation.



## Conflict of interest

Authors declare no conflict of interest.

## References

1. Aarskog D (1971) A familial syndrome of short stature associated with facial dysplasia and genital anomalies. *Birth Defects Orig Artic Ser* 7: 235-239.
2. Scott CI (1971) Unusual facies, joint hypermobility, genital anomaly and short stature: a new dysmorphic syndrome. *Birth Defects Orig Artic Ser* 7: 240-246.
3. Orrico A, Galli L, Cavaliere ML, et al. (2004) Phenotypic and molecular characterisation of the Aarskog-Scott syndrome: a survey of the clinical variability in light of FGD1 mutation analysis in 46 patients. *Eur J Hum Genet* 12: 16-23.
4. Estrada L, Caron E, Gorski JL (2001) Fgd1, the Cdc42 guanine nucleotide exchange factor responsible for faciogenital dysplasia, is localized to the subcortical actin cytoskeleton and Golgi membrane. *Hum Mol Genet* 10: 485-495.
5. Orrico A, Galli L, Clayton-Smith J, et al. (2011) Clinical utility gene card for: Aarskog-Scott syndrome (faciogenital dysplasia). *Eur J Hum Genet* 19.
6. Orrico A, Galli L, Faivre L, et al. (2010) Aarskog-Scott Syndrome: Clinical Update and Report of Nine Novel Mutations of the FGD1 Gene. *Am J Med Genet A* 152a: 313-318.
7. Teebi AS, Rucquoi JK, Meyn MS (1993) Aarskog Syndrome - Report of a Family with Review and Discussion of Nosology. *Am J Med Genet* 46: 501-509.
8. Perez-Coria M, Lugo-Trampe JJ, Zamudio-Osuna M, et al. (2015) Identification of novel mutations in Mexican patients with Aarskog-Scott syndrome. *Mol Genet Genomic Med* 3: 197-202.
9. Logie LJ, Porteous ME (1998) Intelligence and development in Aarskog syndrome. *Arch Dis Child* 79: 359-360.
10. Orrico A, Galli L, Buoni S, et al. (2005) Attention-deficit/hyperactivity disorder (ADHD) and variable clinical expression of Aarskog-Scott syndrome due to a novel FGD1 gene mutation (R408Q). *Am J Med Genet A* 135a: 99-102.
11. Nayak RB, Lambika, Bhogale GS, et al. (2012) Mania with Aarskog-Scott Syndrome. *Indian Pediatrics* 49: 327-328.
12. Roberts AE, Allanson JE, Tartaglia M, et al. (2013) Noonan syndrome. *Lancet* 381: 333-342.
13. Al Kaissi A, Bieganski T, Baranska D, et al. (2007) Robinow syndrome: Report of two cases and review of the literature. *Australas Radiol* 51: 83-86.
14. Smpokou P, Zand DJ, Rosenbaum KN, et al. (2015) Malignancy in Noonan syndrome and related disorders. *Clin Genet* 88: 516-522.
15. Fryns JP (1992) Aarskog Syndrome - the Changing Phenotype with Age. *Am J Med Genet* 43: 420-427.
16. Galupa R, Heard E (2015) X-chromosome inactivation: new insights into cis and trans regulation. *Curr Opin Genet Dev* 31: 57-66.
17. Jogiya A, Sandy C (2005) Mild optic nerve hypoplasia with retinal venous tortuosity in aarskog (facial-digital-genital) syndrome. *Ophthalmic Genet* 26: 139-141.
18. Andrassy RJ, Murthy S, Woolley MM (1979) Aarskog syndrome: significance for the surgeon. *J Pediatr Surg* 14: 462-464.

19. Mikelsaar RV, Lurie IW (1992) Atypical case of Aarskog syndrome. *J Med Genet* 29: 349-350.
20. Fryns JP, Van den Berghe H (1989) On the occurrence of macroorchidism and mental handicap in the Aarskog syndrome. *J Genet Hum* 37: 221-223.
21. Teebi AS, Naguib KK, Alawadi SA, et al. (1988) New Autosomal Recessive Faciodigitogenital Syndrome. *J Med Genet* 25: 400-406.
22. Teebi AS, Alawadi SA (1991) Kuwait Type Faciodigitogenital Syndrome. *J Med Genet* 28: 805-805.
23. Bawle E, Tyrkus M, Lipman S, et al. (1984) Aarskog Syndrome - Full Male and Female Expression Associated with an X-Autosome Translocation. *Am J Med Genet* 17: 595-602.
24. Person AD, Beiraghi S, Sieben CM, et al. (2010) WNT5A mutations in patients with autosomal dominant Robinow syndrome. *Dev Dyn* 239: 327-337.
25. Stevenson RE, May M, Arena JF, et al. (1994) Aarskog-Scott syndrome: confirmation of linkage to the pericentromeric region of the X chromosome. *Am J Med Genet* 52: 339-345.
26. Schmidt A, Hall A (2002) Guanine nucleotide exchange factors for Rho GTPases: turning on the switch. *Genes Dev* 16: 1587-1609.
27. Zheng Y (2001) Dbl family guanine nucleotide exchange factors. *Trends Biochem Sci* 26: 724-732.
28. Genot E, Daubon T, Sorrentino V, et al. (2012) FGD1 as a central regulator of extracellular matrix remodelling - lessons from faciogenital dysplasia. *J Cell Sci* 125: 3265-3270.
29. Grier RE, Farrington FH, Kendig R, et al. (1983) Autosomal dominant inheritance of the Aarskog syndrome. *Am J Med Genet* 15: 39-46.
30. Redin C, Le Gras S, Mhamdi O, et al. (2012) Targeted high-throughput sequencing for diagnosis of genetically heterogeneous diseases: efficient mutation detection in Bardet-Biedl and Alstrom syndromes. *J Med Genet* 49: 502-512.
31. Alkuraya FS (2013) The application of next-generation sequencing in the autozygosity mapping of human recessive diseases. *Hum Genet* 132: 1197-1211.
32. Pasteris NG, Cadle A, Logie LJ, et al. (1994) Isolation and Characterization of the Faciogenital Dysplasia (Aarskog-Scott Syndrome) Gene - a Putative Rho/Rac Guanine-Nucleotide Exchange Factor. *Cell* 79: 669-678.
33. Den Dunnen JT, LOVD v.3.0. 2015. Available from: <http://www.lovd.nl/3.0/home>
34. Tartaglia M, Gelb BD, Zenker M (2011) Noonan syndrome and clinically related disorders. *Best Pract Res Clin Endocrinol Metab* 25: 161-179.
35. Aoki Y, Niihori T, Inoue S, et al. (2016) Recent advances in RASopathies. *J Hum Genet* 61: 33-39.
36. Zou W, Greenblatt MB, Shim JH, et al. (2011) MLK3 regulates bone development downstream of the faciogenital dysplasia protein FGD1 in mice. *J Clin Invest* 121: 4383-4392.
37. Gao L, Gorski JL, Chen CS (2011) The Cdc42 guanine nucleotide exchange factor FGD1 regulates osteogenesis in human mesenchymal stem cells. *Am J Pathol* 178: 969-974.
38. von Mering C, Huynen M, Jaeggi D, et al. (2003) STRING: a database of predicted functional associations between proteins. *Nucleic Acids Res* 31: 258-261.
39. Aten E, Sun Y, Almomani R, et al. (2013) Exome sequencing identifies a branch point variant in Aarskog-Scott syndrome. *Hum Mutat* 34: 430-434.
40. Desmet FO, Hamroun D, Lalande M, et al. (2009) Human Splicing Finder: an online bioinformatics tool to predict splicing signals. *Nucleic Acids Res* 37: e67.

- 
41. Taylor JC, Martin HC, Lise S, et al. (2015) Factors influencing success of clinical genome sequencing across a broad spectrum of disorders. *Nat Genet* 47: 717-726.
  42. Rimmer A, Phan H, Mathieson I, et al. (2014) Integrating mapping-, assembly- and haplotype-based approaches for calling variants in clinical sequencing applications. *Nat Genet* 46: 912-918.
  43. Pertz O (2010) Spatio-temporal Rho GTPase signaling - where are we now? *J Cell Sci* 123: 1841-1850.



**AIMS Press**

© 2016 Andrew Collins et al., licensee AIMS Press. This is an open access article distributed under the terms of the Creative Commons Attribution License (<http://creativecommons.org/licenses/by/4.0>)