

Manuscript submitted to:

Volume 2, Issue 2, 104-109.

*AIMS Genetics*

DOI: 10.3934/genet.2015.2.104

Received date 26 November 2014, Accepted date 26 February 2015, Published date 3 March 2015

---

*Research article***Two cases of androgen insensitivity due to somatic mosaicism**Natalie J. Nokoff<sup>1,\*</sup>, Sharon Travers<sup>1</sup> and Naomi Meeks<sup>2</sup><sup>1</sup> Pediatric Endocrinology, Children's Hospital Colorado, Aurora, CO 80045, USA<sup>2</sup> Genetics, Children's Hospital Colorado, Aurora, CO 80045, USA\* **Correspondence:** Email: Natalie.Nokoff@childrenscolorado.org; Tel: 720-777-3607.

**Abstract:** Androgen insensitivity syndrome (AIS) is caused by mutations in the gene encoding the androgen receptor (AR). The incidence of AIS is estimated to be 1 in 99,000. Complete androgen insensitivity syndrome (CAIS) is characterized by a 46,XY karyotype with external genitalia that appear typically female and results from mutations that render the androgen receptor non-functional. Partial androgen insensitivity syndrome (PAIS) results from partial loss of function mutations in *AR*. Rarely, PAIS results from somatic mosaicism for an *AR* mutation and not from a hypomorphic variant. We present two cases of PAIS due to somatic mosaicism, one caused by a novel nonsense mutation and one caused by a missense mutation previously reported in CAIS. Two patients with atypical genitalia presented to our multidisciplinary clinic for disorders of sex development and sequencing of *AR* was performed as part of the diagnostic evaluation. In case one, *AR* sequencing revealed mosaicism for a nonsense mutation, c.1331T > A; p.Leu444Ter. This mutation has not previously been reported, but is presumed to be pathogenic. In case two, *AR* sequencing revealed a mosaic missense mutation, c.2279 C > A; p.Ser760Tyr, which has previously been reported in CAIS but not in PAIS. Similar phenotypes may result from *AR* mutations that are present in a mosaic state with full loss of function or hypomorphic mutations that partially impair the function of the protein in either all tissues or in a mosaic state.

**Keywords:** disorders of sex development; androgen insensitivity; partial androgen insensitivity; mosaicism

---

**1. Introduction**

Androgen insensitivity syndrome (OMIM #300068) is an X-linked condition in which 46,XY individuals have varying degrees of undervirilization secondary to defects in androgen action due to mutations in the androgen receptor (*AR*) gene (OMIM#313700) [1]. There are three main types of androgen insensitivity syndrome (AIS): complete androgen insensitivity syndrome (CAIS), partial

androgen insensitivity syndrome (PAIS) and mild androgen insensitivity syndrome [1]. Individuals with CAIS have a 46,XY karyotype and due to the complete inaction of androgens in utero, infants are born with phenotypically normal female external genitalia. Internal structures typically consist of a short vagina ending in a blind pouch. Testes are present in the abdomen, but structures derived from the Wolffian ducts are absent, including the vas deferens, epididymis, seminal vesicles and prostate [2]. The phenotypes associated with PAIS are wide-ranging due to varying degrees of androgen resistance [2]. Those with mild androgen insensitivity can have impaired spermatogenesis, impaired pubertal virilization or gynecomastia in puberty [1]. Mutations in the gene *AR* are the primary cause of AIS [1]. The estimated incidence of AIS (complete and partial) is at least one in 99,000 [3]. While genotype-phenotype correlations for CAIS are quite consistent, the phenotype in PAIS can show significant variation [3]. There are reports of individuals from families with the same *AR* mutation with a different sex of rearing and undergoing different reconstructive surgeries [3]. AIS due to somatic mosaicism has been reported as a rare cause of PAIS [4-8].

We present two males with PAIS due to somatic mosaicism, one caused by a novel nonsense mutation that has not previously been reported and another caused by a missense mutation that has been reported to cause CAIS [9], but not PAIS.

## 2. Materials and methods

### 2.1. Patients

We reviewed the records of two individuals with known somatic mosaicism for an *AR* mutation. The case history was obtained by a Pediatric Endocrinologist and Clinical Geneticist. Approval for this case series was obtained from the Colorado Multiple Institutional Review Board and written informed consent was obtained.

### 2.2. DNA analysis

Commercially available sequencing of the *AR* gene was performed in each case. In case one, sequencing was performed by GeneDx ([www.genedx.com](http://www.genedx.com)) and in case two, sequencing was performed by Denver Genetic Laboratories ([www.denvergenetics.org](http://www.denvergenetics.org)). Following peripheral venipuncture, DNA was extracted and amplified using the polymerase chain reaction. Bidirectional Sanger (dideoxynucleotide chain termination) sequencing was performed of the eight coding exons of the *AR* gene and flanking intronic regions.

### 2.3. Hormone analysis

In cases one and two, LH and FSH were measured using an electrochemiluminescent immunoassay. In case one inhibin B and anti-müllerian hormone were measured using a quantitative enzyme-linked immunosorbent assay. In case one testosterone was measured using tandem mass spectrometry and in case two by competitive amino assay. In both cases dihydrotestosterone was measured using tandem mass spectrometry.

### 3. Results

#### 3.1. Case 1

A full term infant presented with atypical genitalia and was assigned a female sex of rearing. The infant was born to a 23-year-old gravida 2 para 2 mother. No prenatal genetic studies or amniocentesis were performed. Family history was unremarkable and consanguinity was denied.

At the first well child examination, genital ambiguity was noted. Examination by an urologist, geneticist and endocrinologist at three months of age revealed a one centimeter phallus, dark, rugated and bifid labioscrotal folds, perineal hypospadias, palpable inguinal gonads and orthotopic anus.

Karyotype revealed 46,XY chromosomal complement. Studies obtained at 3 months of age included: follicle stimulating hormone 1.0 mIU/mL, luteinizing hormone 0.8 mIU/mL, inhibin B 425 pg/mL, anti-müllerian hormone of greater than 225 ng/mL, testosterone 12 ng/dL and dihydrotestosterone 7.8 ng/dL. *AR* sequencing revealed mosaicism for a nonsense mutation, c.1331T > A; p.Leu444Ter.

At five months of age, sex of rearing was reassigned to male and he was treated with intra-muscular testosterone cypionate 50 mg monthly for four months. Phallic length increased to four centimeters. He was also noted to develop Tanner II breast tissue after the testosterone injections.

Cystovaginoscopy performed at age 13 months demonstrated a normal bladder neck, a female urethra, rudimentary vagina measuring 1 cm in length and no evidence of a verumontanum or müllerian structures.

He subsequently underwent bilateral inguinal orchiopexy and herniorrhaphy. He then had a vaginectomy, first-stage hypospadias repair with labial mucosal graft, tunica albuginea plication and circumcision. At that time, findings were notable for perineal hypospadias, ventral penile angulation, a rudimentary vagina and bifid scrotum. Pathology revealed stratified squamous epithelium overlying a fibrovascular submucosa consistent with a rudimentary vagina. This was followed by second-stage hypospadias repair and scrotoplasty at 28 months of age. Parents report a male gender role at three years of age although he has not had formal assessment of either gender identity or gender role.

#### 3.2. Case 2

A now 20 year old male presented with atypical genitalia noted at one week of life. He was born in Iraq and initial medical records were not available. He had bilateral undescended testes and bilateral orchiopexies were performed in childhood. Family history was significant for a paternal uncle with undescended testes. There was no family history of consanguinity.

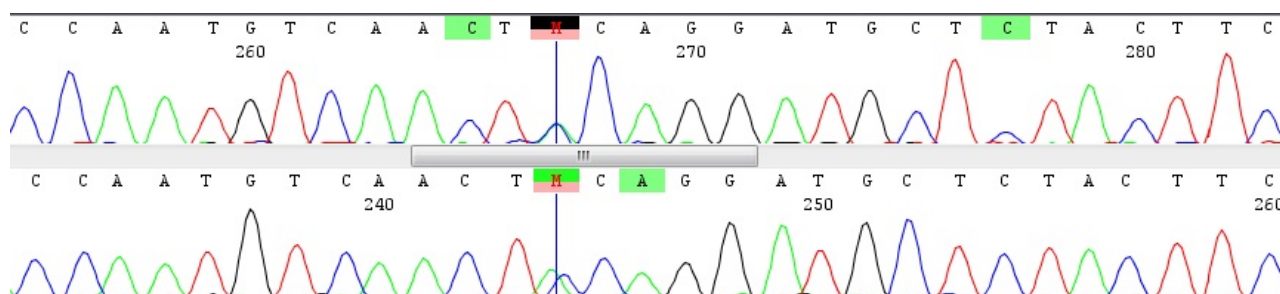
In the past, he had received testosterone injections while living in Iraq and Syria although exact doses and the ages at which he received the injections are not available. The patient reported that at age 20 years he noticed progression in male secondary sex characteristics including more facial hair, acne and deepening of his voice after receiving testosterone. However, he noted that his facial hair growth was asymmetric. He did not notice any enlargement of his penis or testes after testosterone. He reports a male gender identity and exhibits a male gender role although these have not been formally assessed.

Cystoscopy performed at age 20 years showed that his urethra started at the mid-bulbous region

and extended into the membranous region. The prostate and verumontanum were absent.

Physical exam revealed a height of 172cm (25<sup>th</sup> percentile for height on CDC growth curve), arm span 174cm, mild acne on his face and chest, moderate axillary hair and no gynecomastia. Genitourinary exam was significant for tanner V pubic hair, a 4.5 cm phallus, no chordee, subcoronal hypospadias, partially bifid scrotum, non-palpable right gonad and 12mL left testis in the scrotum.

Labs at age 20 years were significant for: follicle stimulating hormone 4.7 mIU/mL, luteinizing hormone 8.42 mIU/mL, total testosterone 1040 ng/dL and dihydrotestosterone 40 ng/dL. He was not on testosterone at the time these labs were drawn. *AR* sequencing revealed a mosaic missense mutation, c.2279 C > A; p.Ser760Tyr (Figure 1).



**Figure 1. In Sanger sequencing, the appearance of two overlapping electropherogram peaks in the *AR* gene in an individual who has one X chromosome is evidence for two cell lines. This sequence shows the mutation (c.2279C > A; p.Ser760Tyr) identified in case 2 (NM\_000044.3).**

#### 4. Discussion

We present two males with PAIS due to somatic mosaicism for *AR* mutations. In the first case, the c.1331T > A; p.Leu444Ter nonsense mutation has not previously been reported in the literature or in a database of known mutations in the *AR* gene (<http://androgendb.mcgill.ca/>) [10]. This results in premature truncation of the protein. In the second case, the c.2279C > A; p.Ser760Tyr missense mutation has been reported to cause CAIS [9], but not PAIS. This is also a rare variant and is not found in population databases including 1000 Genomes, NHLBI Exome sequencing Project (ESP) Exome Variant Server or the Exome Aggregation Consortium (ExAC). Three *in silico* analysis programs predict this change is disease-causing. 46,XY individuals are hemizygous for *AR*, which is on the X chromosome and therefore a single nonsense mutation will result in complete resistance to the action of androgens. The androgen receptor is a nuclear receptor that is bound by either testosterone or dihydrotestosterone. In the bound state, the androgen receptor regulates gene transcription to cause typical embryonic male development and typical male pubertal progression [11]. If only some tissues or cells carry a nonsense mutation or other null allele, then a phenotype of PAIS may result. Mosaicism, or the presence of a genetic variant in only a subset of cells, is presumed to result from a mitotic error in cell replication after fertilization. This is in contrast with germ line mutations or those that arise in meiosis, which are present in all cells of the body. In many genetic conditions, the resultant phenotype depends on which tissues carry the mutation and the percentage of mosaicism in those tissues [12]. For example, newer evidence suggests that Turner syndrome may represent mosaicism in every case that is not lethal in utero [13].

Although nonsense mutations in *AR* are typically reported in CAIS [14-17], mosaicism for both missense and nonsense mutations have been reported in PAIS [5,6,8]. As in case one, some individuals will have increase in phallic length after a course of testosterone, suggesting significant amounts of the functional wild-type receptor in genital tissue despite under-virilization at birth [8]. The child in case one was also noted to develop Tanner II breast tissue after the testosterone injections, likely from aromatization to estrogen. The male in case two did not have any penile growth after treatment with testosterone, suggesting that the genitalia did not have significant expression of the functional androgen receptor protein. However, he did report increase in facial hair, worsening of acne and deepening of his voice after testosterone injections, suggesting that those tissues may have more expression of functional androgen receptor protein. One limitation of this report is the lack of sequencing of *AR* in other tissues and no functional analysis of the protein.

Reports of PAIS caused by a somatic mutation of the *AR* gene are rare in the scientific literature but they represent an important subset of AIS cases [4-7,10]. There is a database of known mutations in the *AR* gene (<http://androgendb.mcgill.ca/>) and the number of individuals in the database with known somatic mosaicism for mutations is small [10]. Similar phenotypes may result from *AR* mutations that are present in a mosaic state with full loss of function or hypomorphic mutations that partially impair the function of the protein in either all tissues or in a mosaic state. Mutations in the *AR* gene may be under-represented since sequencing is usually only performed in blood. If another tissue is readily available, sequencing of *AR* in that tissue may be considered.

## 5. Conclusion

In case 1, the c.1331T > A; p.Leu444Ter nonsense mutation has not previously been reported. In case 2, the c.2279C > A; p.Ser760Tyr missense mutation has been reported to cause CAIS, but not PAIS. Both nonsense and missense mutations can cause mosaic PAIS and the phenotypes can be variable. These findings underscore the importance of considering somatic mosaicism as a genetic etiology for PAIS.

## Conflict of interest

All authors declare no conflict of interest in this manuscript.

## References

1. Gottlieb B, Beitel LK, Trifiro MA (1999 Mar 24 Updated 2014 Jul 10.) Androgen Insensitivity Syndrome. *GeneReviews® Internet*. Seattle (WA): University of Washington, Seattle; 1993-2014 Available from: <http://www.ncbi.nlm.nih.gov/books/NBK1429/>.
2. Galani A, Kitsiou-Tzeli S, Sofokleous C, et al. (2008) Androgen insensitivity syndrome: clinical features and molecular defects. *Hormones* 7: 217-229.
3. Boehmer ALM, Brüggewirth H, van Assendelft C, et al. (2001) Genotype Versus Phenotype in Families with Androgen Insensitivity Syndrome. *J Clin Endocrinol Metab* 86: 4151-4160.
4. Hiort O, Sinnecker GH, Holterhus PM, et al. (1998) Inherited and de novo androgen receptor gene mutations: investigation of single-case families. *J Pediatr* 132: 939-943.

5. Holterhus PM, Bruggenwirth HT, Hiort O, et al. (1997) Mosaicism due to a somatic mutation of the androgen receptor gene determines phenotype in androgen insensitivity syndrome. *J Clin Endocrinol Metab* 82: 3584-3589.
6. Holterhus P-M, Wiebel J, Sinnecker GHG, et al. (1999) Clinical and Molecular Spectrum of Somatic Mosaicism in Androgen Insensitivity Syndrome. *Pediatr Res* 46: 684-684.
7. Boehmer AL, Brinkmann AO, Niermeijer MF, et al. (1997) Germ-line and somatic mosaicism in the androgen insensitivity syndrome: implications for genetic counseling. *Am J Hum Genet* 60: 1003-1006.
8. Köhler B, Lumbroso S, Leger J, et al. (2005) Androgen insensitivity syndrome: somatic mosaicism of the androgen receptor in seven families and consequences for sex assignment and genetic counseling. *J Clin Endocrinol Metab* 90: 106-111.
9. Hughes IA, Werner R, Bunch T, et al. (2012) Androgen insensitivity syndrome. *Semin Reprod Med* 30: 432-442.
10. Gottlieb B, Beitel LK, Nadarajah A, et al. (2012) The androgen receptor gene mutations database: 2012 update. *Human Mutation* 33: 887-894.
11. Sperling M (2014) Pediatric endocrinology fourth edition. Philadelphia, PA: Saunders/Elsevier.
12. Gottlieb B, Beitel LK, Trifiro MA (2001) Somatic mosaicism and variable expressivity. *Trends Genet* 17: 79-82.
13. Hook EB, Warburton D (2014) Turner syndrome revisited: review of new data supports the hypothesis that all viable 45,X cases are cryptic mosaics with a rescue cell line, implying an origin by mitotic loss. *Hum Genet* 133: 417-424.
14. Zoppi S, Wilson CM, Harbison MD, et al. (1993) Complete testicular feminization caused by an amino-terminal truncation of the androgen receptor with downstream initiation. *J Clin Invest* 91: 1105-1112.
15. Trifiro M, Prior RL, Sabbaghian N, et al. (1991) Amber mutation creates a diagnostic MaeI site in the androgen receptor gene of a family with complete androgen insensitivity. *Am J Med Genet* 40: 493-499.
16. Hiort O, Wodtke A, Struve D, et al. (1994) Detection of point mutations in the androgen receptor gene using non-isotopic single strand conformation polymorphism analysis. German Collaborative Intersex Study Group. *Hum Mol Genet* 3: 1163-1166.
17. Batch JA, Williams DM, Davies HR, et al. (1992) Androgen receptor gene mutations identified by SSCP in fourteen subjects with androgen insensitivity syndrome. *Hum Mol Genet* 1: 497-503.

© 2015, Natalie J. Nokoff, et al., licensee AIMS Press. This is an open access article distributed under the terms of the Creative Commons Attribution License (<http://creativecommons.org/licenses/by/4.0>)