

Case Study Spontaneous Otoliquorrhea in Adult

Relato de Caso: Otoliquorreia Espontânea em Adulto

Amanda Costa Rossi*, **Juliana Martins de Araujo Cardoso Bertoncello****, **Luiz Carlos Scachetti*****,
Carolina Schäffer***, **Aguinaldo Pereira Catanoce******, **Silvio Antonio Monteiro Marone*******.

* Resident of the Year 3 of the Department of Otolaryngology, Hospital Celso Pierro School of Medicine, PUC Campinas.

** Otorhinolaryngologist. Specialist Medical Assistant Department of Otolaryngology, Hospital Celso Pierro School of Medicine, PUC Campinas.

*** Medical (a) ENT. Medical (a) Specialist Contributor (a) of the Department of Otolaryngology, Hospital Celso Pierro School of Medicine, PUC Campinas.

**** MD Neurosurgeon. Specialist Assistant to the Department of Neurosurgery, Hospital Celso Pierro School of Medicine, PUC Campinas, Vera Cruz Hospital and the Hospital Estadual Mário Covas FMABC.

***** Professor of Otolaryngology, School of Medicine, PUC Campinas. Professor of Otolaryngology, School of Medicine, PUC Campinas and Professor of Otolaryngology, School of Medicine, USP.

Institution: Celso Pierro Hospital and Medical School, PUC Campinas.
Campinas / SP - Brazil.

Mail address: Amanda Rossi Costa - Rua José Luis Pereira de Com Queiros, 170 - Apto 141 - Botafogo - Campinas / SP - Brazil - Zip code: 13020-080 - Telephone: (+55 19) 3343-8599 - E-mail: amandarossi@hotmail.com

Article received on May 3, 2009. Article accepted on August 4, 2009.

SUMMARY

Introduction:

The spontaneous otological CSF leaks are rare entities. Usually they manifest themselves in children with meningitis and deep sensorineural hearing loss and in adults with middle otitis and effusion clinical picture.

Objective:

To describe the clinical picture, diagnosis and surgical treatment of a patient with CSF otological.

Case Report:

A female sex patient, 57 years old, with hearing loss, aural fullness and right ear tinnitus case history 10 years ago. After insertion of tympanostomy tubes on the right in another service, it began liquid, transparent and constant otorrhea in large quantities. The diagnosis was performed by suggestive cisternoscintigraphy of CSF leak, and by cisternography that showed that the area of bone dehiscence in the tegmen tympani region to the right, partial opacification of mastoid cells and middle ear to the right, besides concentration of contrast medium in sub-arachnoid space to the lower right compared to the left side. Through transmastoid via was located the CSF leak and meningoencephalocele in the region of the right tegmen tympani. The closure of the fistula was accomplished through the use of the temporal muscle flap, fibrin glue and Surgicel®.

Final Comments:

In adults with symptoms suggestive of recurrent otitis media with effusion, the diagnosis of CSF fistula should be raised. The research should proceed with imaging, highlighting the CTC. Surgical treatment in this patient using the transmastoid technique has proved effective in the short and long term.

Keywords:

CSF otorrhea, fistula, meningitis.

RESUMO

Introdução:

As fístulas líquóricas otológicas espontâneas (FLOEs) são entidades raras. Geralmente manifestam-se em crianças com meningite e perda sensorineural profunda e em adultos com quadro de otite média com efusão.

Objetivo:

Descrever o quadro clínico, o diagnóstico e o tratamento cirúrgico de uma paciente com FLOE.

Relato do Caso:

Paciente do sexo feminino, 57 anos, com história de hipoacusia, plenitude aural e tinnitus à direita há 10 anos. Após colocação de tubo de ventilação à direita em outro serviço, iniciou otorreia líquida, transparente e constante em grande quantidade. O diagnóstico foi realizado através da cisternocintilografia, sugestiva de fístula líquórica; e da cisternotomografia que mostrou área de deiscência óssea em região de tegmen tympani à direita, velamento parcial de células mastóideas e de orelha média à direita, além concentração do meio de contraste no espaço sub-aracnoideo à direita menor em relação ao lado esquerdo. Através de via transmastóidea foi localizada fístula líquórica e meningoencefalocele na região de tegmen tympani à direita. O fechamento da fístula foi realizado através do uso de retalho de músculo temporal, cola de fibrina e Surgicel®.

Comentários Finais:

Em adultos com história clínica sugestiva de otite média com efusão recorrente, a hipótese diagnóstica de fístula líquórica deve ser levantada. A investigação deve prosseguir com exames de imagem, destacando-se a cisternotomografia. O tratamento cirúrgico nesta paciente, através da técnica transmastóidea, se revelou eficaz a curto e a longo prazo.

Palavras-chave:

otorreia de líquido cefalorraquidiano, fistula, meningite.

INTRODUCTION

The otologic cerebrospinal fluid leakage was mainly due to acquired factors such as temporal bone fractures and surgeries involving the temporal bone (1).

Otological spontaneous CSF fistulas (floe) are rare and can be grouped according to age into two groups (1,2,3):

- In children due to the presence of failures in the temporal bone as dehiscence. In these cases an early manifestation is between one and five years of life, and usually presents with meningitis and profound sensorineural hearing loss.
- In adults in the fifth decade of life, generally obese women with clinical secretory otitis media. It presents one or more areas of bony dehiscence in the tegmen tympani and less commonly in the posterio-fossa.

The pathophysiology of the floe is not yet fully understood.

There are two theories responsible for the congenital and the presence of arachnoid granulations:

- The congenital bone defect theory posits that small communications with the tegmen result from anomalous embryological development (4). The passage of CSF may occur due to inner ear to the cochlear aqueduct and thus extended through a defect in the modiolus which allows passage through the oval or round windows (5), or directly to middle ear through changes in the cleft of tympanomeníngea HYRTL (6).
- The presence of granulation theory was postulated by RICHARD GACEK in 1990 (7) and suggests that arachnoid granulations during embryonic development ending in a blind bottom surface inner bone of the skull base. The central portion of these granules contains liquor and covered loosely by a fibrous capsule and the endothelium. Over time, pressure from the subarachnoid space causes erosion of the fibrous capsule of the nasal bone and consequently the anterior, middle or later, resulting in passage of CSF to the middle ear.

The diagnosis of floe depends largely on clinical suspicion. It is suggested that any patient over 50 years with symptoms suggestive recurrent otitis media with effusion should be taken as a diagnosis among other floe (4).

The aim of this paper and describe the clinical features, diagnosis and surgical treatment of a patient into a floe Otorhinolaryngology Service of a tertiary care hospital, with residency in Otolaryngology.

CASE REPORT

Female patient, 57 years, sought the Department of Otolaryngology with a history of hearing loss, ear fullness and tinnitus on the right for about 10 years. He denied vertigo. Nearly a year had been submitted to the use of a ventilation tube to the right in another service. Since then started otorrhea liquid, transparent and consistent in great quantity, without improvement with the use of eardrops. Personal history included arterial hypertension, diabetes mellitus and asthma. He denied any history of meningitis, trauma or other otologic surgery.

ENT examination was normal except for right otoscopy, which showed opaque tympanic membrane with the presence of a ventilation tube through which drained large amounts of clear liquid.

The endoscopy showed no abnormalities, tubal ostia bilaterally free.

She underwent the following complementary exams.

The dosage of glucose ear fluid was 1 mg / dL (from the ventilation tube was still inserted), which suggested it is not liquor.

Audiometry, had mild conductive hearing loss on the right.

As for imaging, computed tomography of the temporal bone showed no bone dehiscence. Magnetic resonance imaging did not provide relevant data.

It was then submitted to cistern cintilography with signs suggestive of CSF, showing concentration of radiotracer in the region of the right ear (Figures 1, 2 and 3). CTC, after the introduction of intrathecal iodinated contrast medium showed the area of bony dehiscence in the region of the right tegmen, partial opacification of the mastoid cells and middle ear to the right (Figure 4). Also showed asymmetric concentration of contrast medium in the subarachnoid space, showing up in smaller quantities in the right cerebral hemisphere (Figures 5 and 6), thus confirming the hypothesis of CSF fistula.

Through transmastoid CSF leak was located about 1 mm in the right tegmen tympani, which is also evidenced meningoencephalocele the same region. The closure of the fistula was achieved through the placement of a temporalis muscle flap, followed by placement of fibrin glue and Surgicel®. After this procedure, was removed the vent tube right tympanic

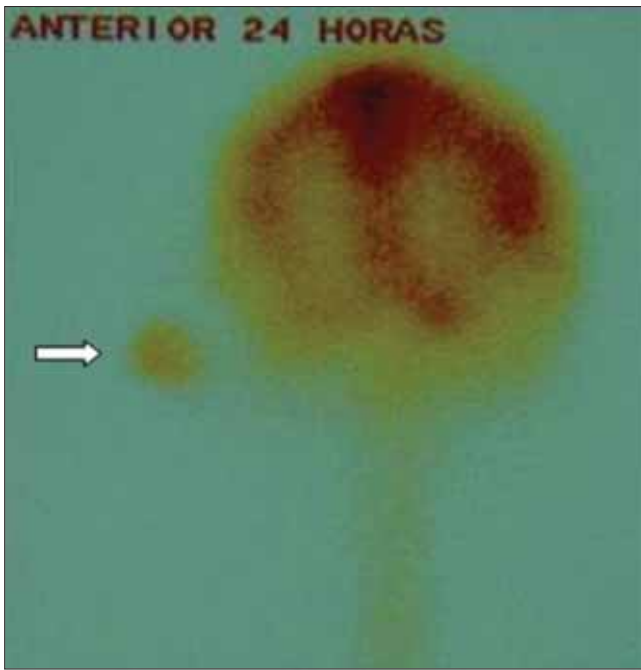

Figure 1. Cisternocintilografia - Previous - Suggestive of cerebrospinal fluid leak in the area of the right ear (arrow).

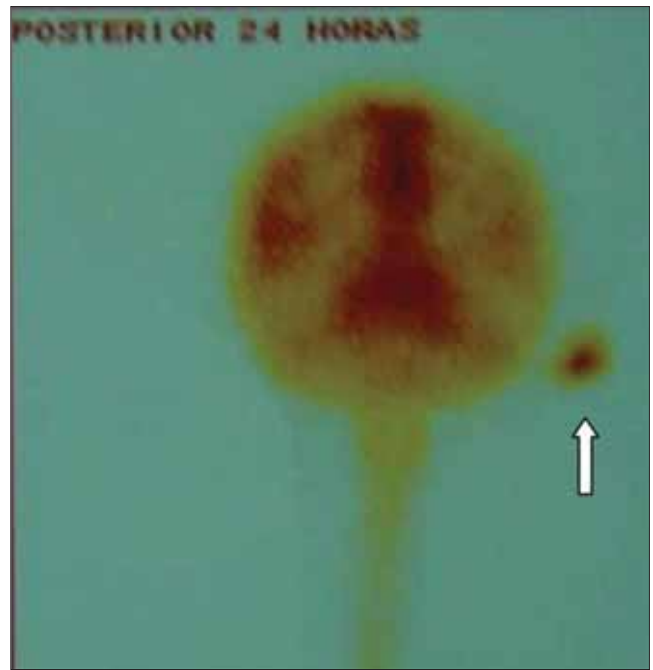

Figure 2. Cisternocintilografia - Rear - Suggestive of cerebrospinal fluid leak in the area of the right ear (arrow).

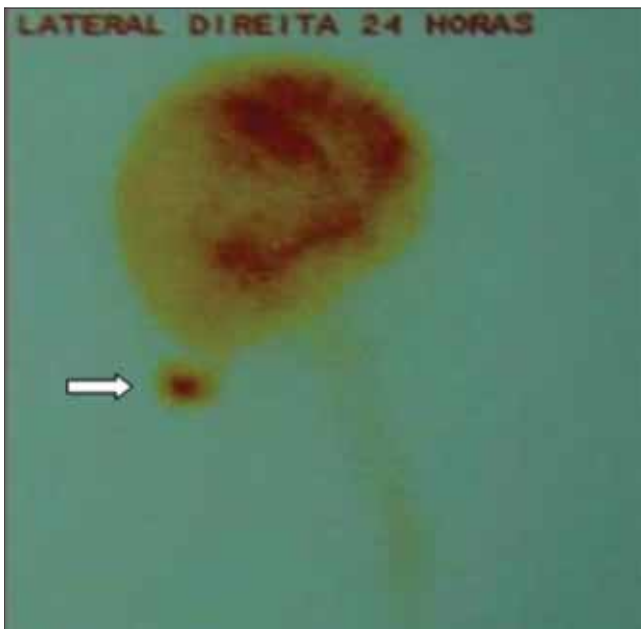

Figure 3. Cisternocintilografia - Right Side - Suggestive of cerebrospinal fluid leak in the area of the right ear (arrows).

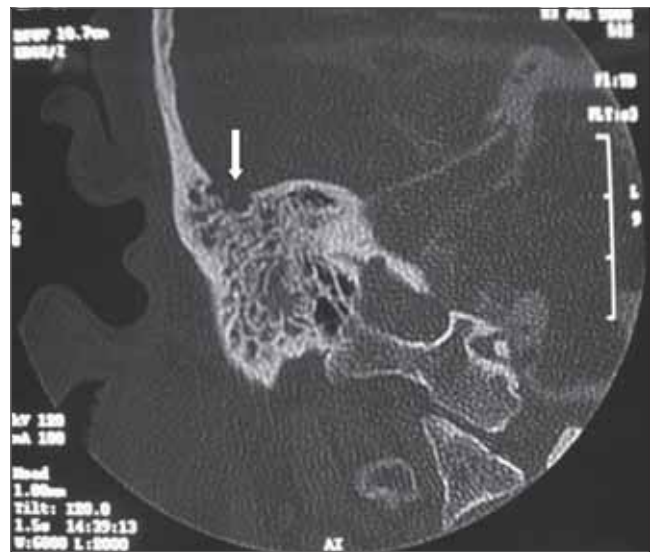

Figure 4. Cisternography of the temporal bone (coronal) - area of bony dehiscence in the tegmen tympani (arrow).

membrane. We opted for the withdrawal of ventilation tubes for while maintaining the same power to highlight the possible permanence of otorrhea, this could be ascertained by otoscopy by changes of the tympanic membrane . Moreover, the permanence of the vent pipe could facilitate the onset of infection.

The patient remained 72 hours with lumbar drainage in the supine position with head elevated on bedrest in diet and laxative. During his admission he used an IV Ceftriaxone 2g of 12/12 hours. The patient was discharged on the fifth postoperative day. In the immediate postoperative otorrhea had no more liquid and remained

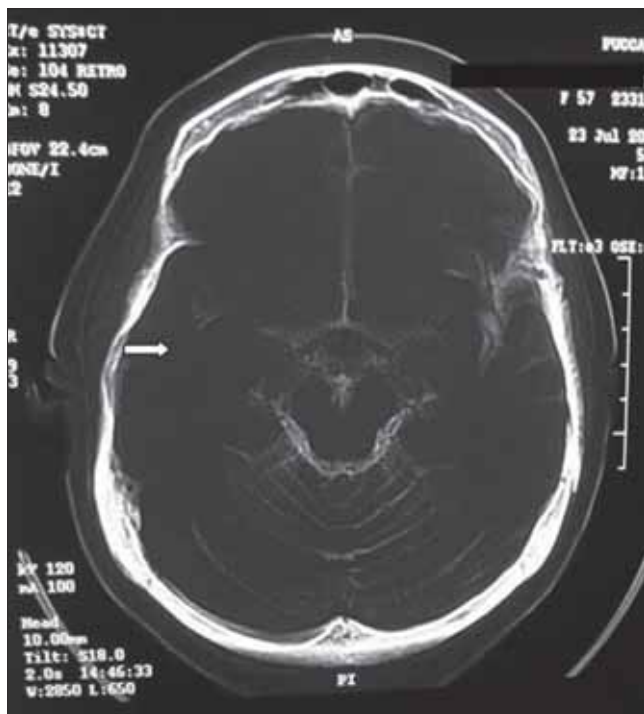


Figure 5. Cisternography temporal bone (axial) - The concentration of contrast medium to a lesser extent in subarachnoid space to the right over the left side (arrow).

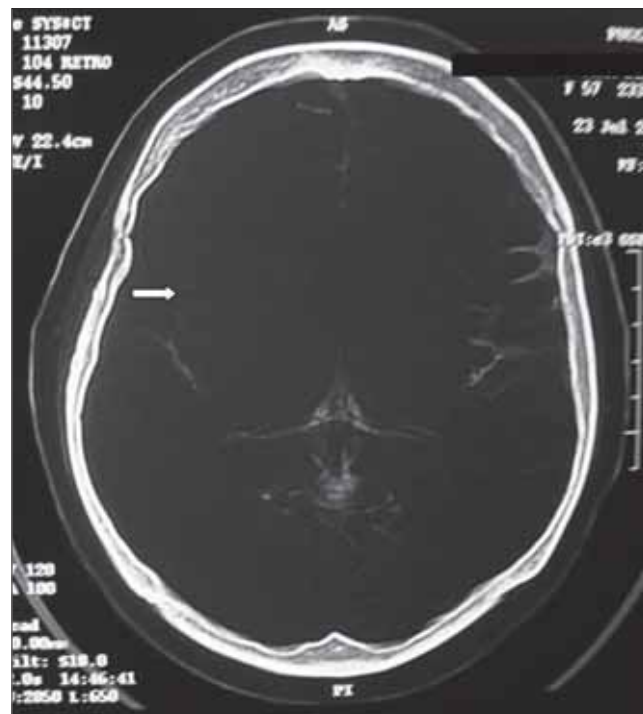


Figure 6. Cisternography temporal bone (axial) - The concentration of contrast medium to a lesser extent in subarachnoid space to the right over the left side (arrow).

so during follow-up that continues to be conducted periodically for 12 months.

Postoperative audiometry performed, which revealed no abnormalities.

DISCUSSION

Age and clinical presentation of this case, are consistent with the theory of arachnoid granulation due to the age of onset and type of clinical presentation. Regarding gender, most studies (2,3,8) show a higher incidence in middle-aged women. The susceptibility in women is not well understood, increased intracranial pressure is suggested as a possible cause in these women (2). There is still no published data that relate to the female floe (9).

Early diagnosis of floe depends on a high degree of clinical suspicion (2,3,4,9). In our case, the suspect took place after the completion of the clinical exam, with no explanation for the occurrence of such otorrhea.

Can be performed laboratory tests such as fasting glucose level of the liquid. A concentration of 30 mg / dL glucose is considered positive CSF in a patient with normal glucose level. However, the chemical analysis of fluid obtained from the ear depends on the presence of

contamination or infection, bringing a high rate of false positive. In our case, the fasting glucose level was 0.1 mg / dL, it is not conclusive for diagnosis. highly specific and sensitive to CSF leak is the dosage of beta 2 transferrin, a specific protein from the CSF and can be measured in extremely small amounts of fluid (4), being an expensive test. We do not have in our service.

In evaluating patients with suspected CSF leak at high resolution CT of the temporal bone is considered essential. MRI reveals no bone dehiscence. The intrathecal injection of radioisotope was helpful in diagnosing the presence of fistula, but no help in locating the site (9).

Regarding surgical approach, several authors refer to the technique of the middle fossa craniotomy for repair of fistula. There are also recent reports of access transmastoid and combination of these approaches (1,2,3,9,10).

The middle fossa approach provides wide exposure, so dehiscence (larger than 2 cm), multiple or extending anteriorly to the petrous apex can be corrected by this route (4), saving your hearing. However, it is a procedure with great potential for complications (10). The transmastoid has the advantage of accessing the middle and posterior fossa craniotomy and preventing retraction of the temporal lobe (4). It is also technically easier to perform, and a procedure with fewer risks and

complications, not proving a deterrent for the correction of bone defects, even larger. Thus, you can choose initially by transmastoid and failure of this procedure using a broader access to the craniotomy (10). In our case, we chose to perform the transmastoid as the first option to be a less invasive procedure.

Several materials can be used for repair of CSF leaks: as autologous fascia, muscle, cartilage, fat and bone, and various combinations of materials and synthetic counterparts (4, 10). The closure technique with multiple layers has shown higher rates of permanent closure and lower recurrence rate (2,4). In our case we used the technique of closure with multiple layers, with the temporalis muscle, fibrin glue and Surgicel®.

A lumbar shunt can be used as an adjunct for postoperative decrease the intracranial pressure. Its use in the postoperative period is controversial due to risk of potential complications such as meningitis, headache or catheter obstruction (10). In the case described lumbar drainage was used for 72 hours without complicações. O use of antibiotic prophylaxis is not mentioned by many authors, but there are reports on the use of Ceftriaxone 1g 8 / 8 hours (10). In our case we chose Ceftriaxone 2g 12/ 12 hours as a prophylactic measure.

CONCLUSION

Otologic cerebrospinal fluid leak may occur in the absence of a history of trauma or meningitis. In adults with symptoms suggestive of recurrent otitis media with effusion, especially with no cause for such, the diagnosis of CSF should be raised. The investigation should proceed with imaging, highlighting the CTC. Surgical treatment in this patient, using the technique transmatoid proved effective in the short and long term.

BIBLIOGRAPHIC REFERENCES

1. Wetmore SJ, Herrmann P, Fisch U. Spontaneous Cerebrospinal Fluid Otorrhea. *Am J Otol.* 1987, 8(2):96-102.
2. Rao AK, Merenda DW, Wetmore SJ. Diagnosis and Management of Spontaneous Cerebrospinal Fluid Otorrhea. *Otology & Neurotology.* 2005, 26(6):1171-1175.
3. Gacek RR, Gacek MR, Tart R. Adult Spontaneous Cerebrospinal Fluid Otorrhea: Diagnosis and Management. *Am J Otol.* 1999, 20:770-776.
4. Brown NE, Grundfast KM, Jabre A, Megerian CA, Malley BW, Rosenberg SI. Diagnosis and Management of Spontaneous Cerebrospinal Fluid - Middle Ear Effusion and Otorrhea. 2004, 114(5):800-805.
5. Montgomery WW. Dural defects of the temporal bone. *Am J Otol.* 1993, 14:548-551.
6. Schuknecht HF, Gulya AJ. Anatomy of the temporal bone with surgical implications. Philadelphia: Lea & Febiger, 1986.
7. Gacek RR. Arachnoid Granulation Cerebrospinal Fluid Otorrhea. *Annals of Otology, Rhinology and Laryngology.* 1990, 99:854-862.
8. Schlosser RJ, Bolger WE. Significance of Empty Sella in Cerebrospinal Fluid Leaks. *Otolaryngology Head Neck Surgery.* 2003, 128:32-38.
9. May JS, Mikus JL, Matthews BL, Browne JD. Spontaneous Cerebrospinal Fluid Otorrhea from Defects of the Temporal Bone: A Rare Entity? *Am J Otol.* 1995, 16(6):765-771.
10. Bento RF, Pádua FGM. Abordagem Transmastoídea de Fístula Líquórica em Tegmen Timpânico. *Arq Int Otorrinolaringol.* 2003, 7(4):250.