

Aniridia as a clue for the diagnosis of Gillespie syndrome

Aniridia: dica clínica para o diagnóstico da síndrome de Gillespie

Flávio Moura REZENDE FILHO¹, José Luiz PEDROSO¹, Júlian Letícia de FREITAS¹, Luis Fernando TEIXEIRA², Orlando Graziani Povoas BARSOTTINI¹

A 23-year-old woman presented with global developmental delay and non-progressive ataxia since birth. Parents were consanguineous. On examination, she had dysarthria, nystagmus and ataxia. Ophthalmological evaluation showed absence of part of the iris or aniridia (Figure 1) and magnetic resonance imaging (MRI) pointed mild cerebellar atrophy. Genetic testing revealed

homozygous mutations in *ITPR1* gene and confirmed Gillespie syndrome.

Absence of part or all the iris is called aniridia. This is a distinct ophthalmological feature observed in a restrict group of genetic diseases¹. The triad of aniridia, congenital ataxia and intellectual disability characterize Gillespie syndrome, a recessive or dominant disease caused by *ITPR1* gene mutations².

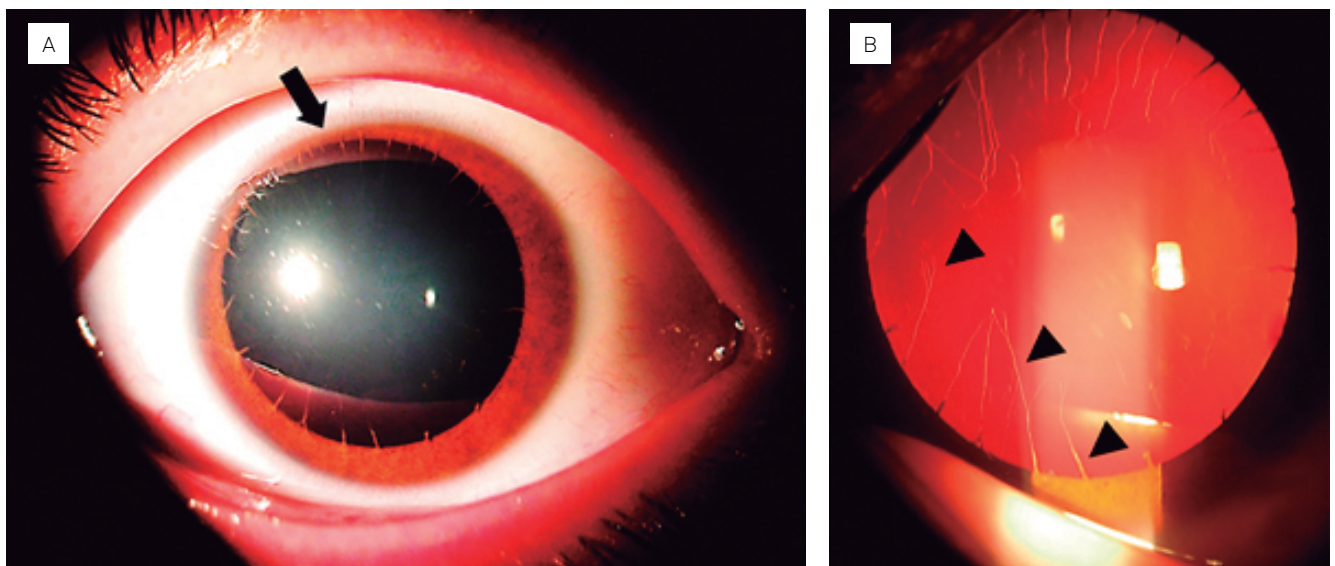


Figure 1. Ophthalmological findings in a 23-year-old woman with Gillespie syndrome. (A) Photograph of the right eye. (B) Slit-lamp examination. A thin rim of iridal tissue (arrow) results in a fixed and dilated appearance of the pupil, consistent with iris hypoplasia (A). Iridolenticular strands occurring at irregular intervals (arrowheads) constitute remnants of the pupillary membrane (B).

References

- Hall HN, Williamson KA, FitzPatrick DR. The genetic architecture of aniridia and Gillespie syndrome. *Hum Genet.* 2019 Sep;138(8-9):881-98. <https://doi.org/10.1007/s00439-018-1934-8>
- Gerber S, Alzayady KJ, Burglen L, Brémond-Gignac D, Marchesin V, Roche O, et al. Recessive and dominant de novo *ITPR1* mutations cause Gillespie syndrome. *Am J Hum Genet.* 2016 May 5;98(5):971-80. <https://doi.org/10.1016/j.ajhg.2016.03.004>

¹Universidade Federal de São Paulo, Departamento de Neurologia, Unidade de Ataxia, São Paulo SP, Brazil.

²Universidade Federal de São Paulo, Departamento de Oftalmologia, Setor de Órbita, São Paulo SP, Brazil.

Flávio Moura REZENDE FILHO <https://orcid.org/0000-0003-4565-5898>; José Luiz PEDROSO <https://orcid.org/0000-0002-1672-8894>; Júlian Letícia de FREITAS <https://orcid.org/0000-0002-7119-3423>; Luis Fernando TEIXEIRA <https://orcid.org/0000-0002-5241-0541>; Orlando Graziani Povoas BARSOTTINI <https://orcid.org/0000-0002-0107-0831>

Correspondence: José Luiz Pedroso; E-mail: jlpedroso.neuro@gmail.com

Conflict of interest: There is no conflict of interest to declare.

Received on December 27, 2019; Received in its final form on January 17, 2020; Accepted on January 20, 2020.