

Ring-shaped lateral ventricular nodules: a “leave me alone” lesion

Nódulos ventriculares laterais em formato de anel: uma lesão “não me toque”

Marcos Rosa Júnior¹, Vera Lúcia Ferreira Vieira²

A 34-year-old female presented at our facility with headache. The MRI showed ring-shaped lateral ventricular nodules (RSLVNs) (Figure).

The RSLVNs are an incidental finding on MRI in patients who undergo neuroimaging mainly for headache.¹ The nature of the RSLVNs is controversial and includes neuroglial/glioependymal cyst, inflammatory or reactive formation of

ependyma, astrocytic gliosis reaction near subependymal veins, redetachment of the fused portion of coarctation of the frontal horn or a variant of subependymoma^{1,2}. In the differential diagnosis, the most common pathological entities are subependymal heterotopias, usually found in patients with epilepsy and subependymal nodules in patients with tuberous sclerosis¹.

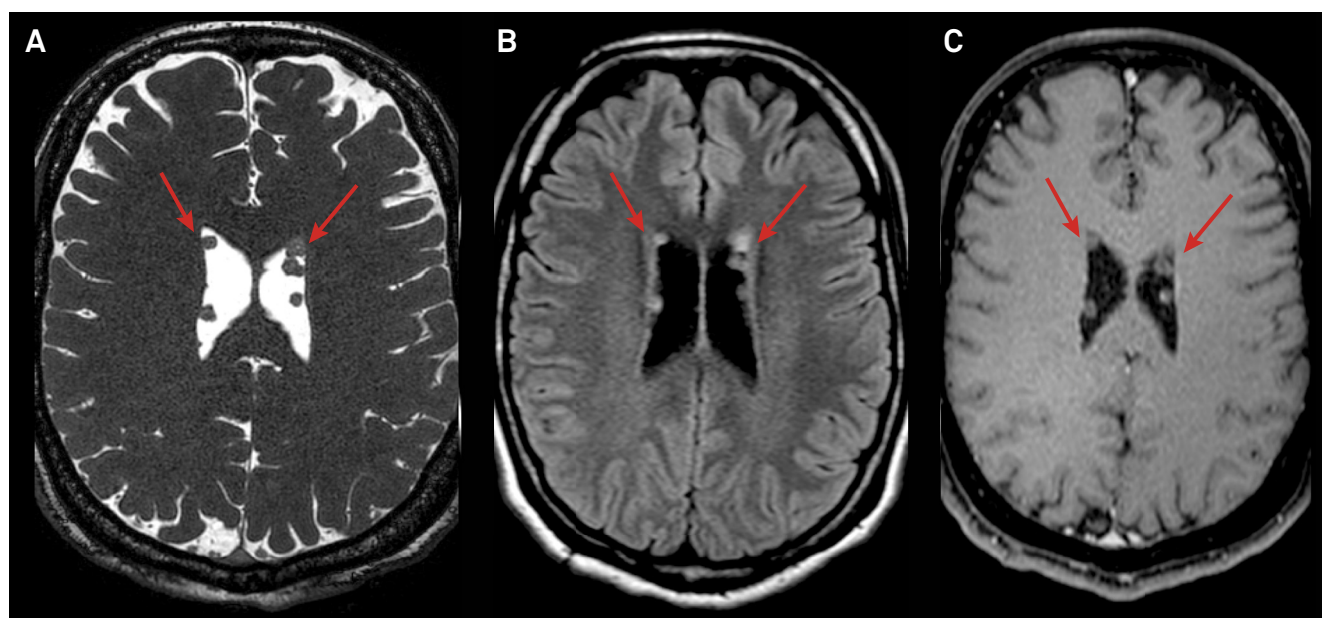


Figure. MRI, axial balanced, a three-dimensional steady-state free precession T2-weighted imaging (A), FLAIR (B) and T1-post gadolinium (C), obtained at the level of the roof of the lateral ventricles show ring-shaped left lateral ventricular nodules (arrows) with no contrast enhancement.

References

1. Shimono T, Hosono M, Ashikaga R, Kumano S, Imaoka Y, Okada M et al. Ring-shaped lateral ventricular nodules: an incidental finding on brain magnetic resonance imaging. *Neuroradiology*. 2009;51(3):145-50. <https://doi.org/10.1007/s00234-008-0476-5>
2. Friedman DP. Abnormalities of the deep medullary white matter veins: MR imaging findings. *AJR Am J Roentgenol*. 1997;168(4):1103-8. <https://doi.org/10.2214/ajr.168.4.9124123>

¹ Universidade Federal do Espírito Santo, Hospital Universitário Cassiano Antônio de Moraes, Empresa Brasileira de Serviços Hospitalares, Departamento de Neurorradiologia, Vitória ES, Brasil;

² Universidade Federal do Espírito Santo, Hospital Universitário Cassiano Antônio de Moraes, Departamento de Neurologia, Vitória ES, Brasil.

Correspondence: Marcos Rosa Júnior; Universidade Federal do Espírito Santo – UFES, Centro de Ciências da Saúde; Avenida Marechal Campos, 1468; Maruípe, 29043-900 Vitória ES, Brasil. E-mail: marcosrosajr@hotmail.com

Conflict of interest: There is no conflict of interest to declare.

Received 10 January 2018; received in final form 03 February 2018; Accepted 07 February 2018.