

# Calcified intracranial tuberculomas as sequelae of pediatric neurotuberculosis

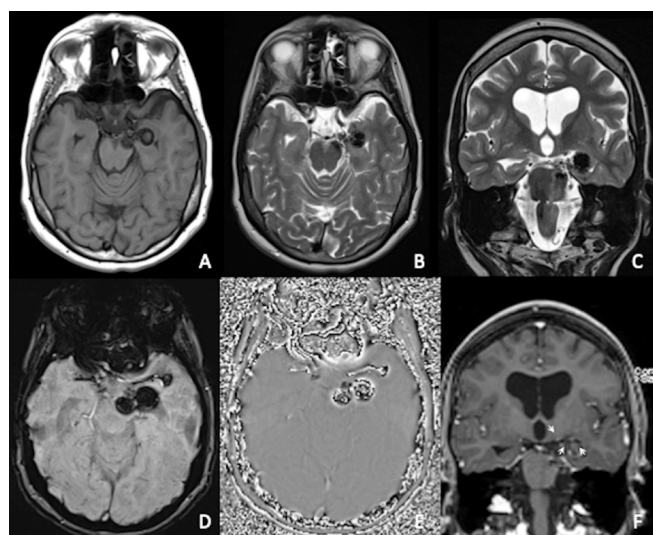
Tuberculomas calcificados intracranianos como sequela de neurotuberculose pediátrica

Carolina de Medeiros RIMKUS<sup>1</sup>, Thiago Augusto Vasconcelos MIRANDA<sup>1</sup>, Leandro Tavares LUCATO<sup>1</sup>

A 29-year-old woman with a history of neurotuberculosis at the age of 18 months presented with seizures, abnormal gait, and fluctuations of consciousness level, recovering after anti-tuberculosis treatment. She remained asymptomatic for the next years, except for moderate cognitive impairment. Years later, a brain magnetic resonance imaging (MRI) scan (Figure 1) revealed

calcified lobulated masses in the brain parenchyma and basal cisterns.

Intracranial tuberculomas occur in 5–24% of pediatric neurotuberculosis<sup>1</sup> and can be secondary to pial vessel inflammation, perivascular abscesses, or septic emboli<sup>2</sup>. Medical history and the characterization of non-enhancing, diffusely calcified brain masses are important clues for diagnosing residual granulomas.



**Figure 1.** Magnetic resonance imaging shows multiple lobulated masses with low signal in T1-weighted (A) and T2-weighted (B and C) images in the brain parenchyma and basal cisterns, with low signal in susceptibility-weighted imaging (SWI) (D) and phase images (E), compatible with calcifications. Lesions are non-enhancing in post-gadolinium images (F), except for a few peripheral enhancing foci (arrows), corresponding to small vessels.

## References

- Chiang SS, Khan FA, Milstein MB, Tolman AW, Benedetti A, Starke JR, et al. Treatment outcomes of childhood tuberculous meningitis: a systematic review and meta-analysis. *Lancet Infect Dis*. 2014 Oct;14(10):947-57. [https://doi.org/10.1016/S1473-3099\(14\)70852-7](https://doi.org/10.1016/S1473-3099(14)70852-7)
- Rock RB, Olin M, Baker CA, Molitor TW, Peterson PK. Central nervous system tuberculosis: pathogenesis and clinical aspects. *Clin Microbiol Rev*. 2008 Apr;21(2):243-61. <https://doi.org/10.1128/CMR.00042-07>

<sup>1</sup>Universidade de São Paulo, Faculdade de Medicina, Departamento de Radiologia e Oncologia, São Paulo SP, Brazil.

Carolina de Medeiros RIMKUS <https://orcid.org/0000-0002-3866-1299>; Thiago Augusto Vasconcelos MIRANDA <https://orcid.org/0000-0002-8144-0758>; Leandro Tavares LUCATO <https://orcid.org/0000-0001-9181-5245>

**Correspondence:** Carolina de Medeiros Rimkus; E-mail: carolina.rimkus@hc.fm.usp.br

**Conflict of interest:** There is no conflict of interest to declare.

**Authors' contributions:** CMR: study conceptual design, imaging analysis, writing and review of the manuscript. TAV: imaging and clinical data acquisition, review of the manuscript. LTL: imaging analysis, writing and review of the manuscript.

Received on June 8, 2020; Received in its final form on July 19, 2020; Accepted on July 25, 2020.